National Comprehensive Cancer Network®

NCCN Clinical Practice Guidelines in Oncology (NCCN Guidelines®)

Head and Neck Cancers

Version 1.2026 — December 8, 2025

NCCN.org

NCCN recognizes the importance of clinical trials and encourages participation when applicable and available. Trials should be designed to maximize inclusiveness and broad representative enrollment.

NCCN Guidelines for Patients® available at www.nccn.org/patients

Version 1.2026, 12/08/2025 © 2025 National Comprehensive Cancer Network® (NCCN®), All rights reserved. NCCN Guidelines® and this illustration may not be reproduced in any form without the express written permission of NCCN.

PLEASE NOTE that use of this NCCN Content is governed by the End-User License Agreement, and you MAY NOT distribute this Content or use it with any artificial intelligence model or tool.
Printed by Galya Basol Kochav on 1/4/2026 9:40:35 AM. Copyright © 2026 National Comprehensive Cancer Network, Inc. All Rights Reserved.

***David G. Pfister, MD † Þ/Chair**
Memorial Sloan Kettering Cancer Center

***Sharon Spencer, MD §/Vice-Chair**
O'Neal Comprehensive Cancer Center at UAB

***Douglas Adkins, MD †**
Siteman Cancer Center at Barnes-Jewish Hospital and Washington University School of Medicine

Andrew C. Birkeland, MD ξ
UC Davis Comprehensive Cancer Center

***David M. Brizel, MD §**
Duke Cancer Institute

Paul M. Busse, MD, PhD §
Mass General Cancer Center

Molly Cassidy, JD, EdD ¥
Patient Advocate

***Jimmy J. Caudell, MD, PhD §**
Moffitt Cancer Center

Anthony J. Cmelak, MD §
Vanderbilt-Ingram Cancer Center

***A. Dimitrios Colevas, MD †**
Stanford Cancer Institute

Greg Durm, MD, MS †
Indiana University Melvin and Bren Simon Comprehensive Cancer Center

Carole Fakhry, MD, MPH ξ
Johns Hopkins Kimmel Cancer Center

Thomas J. Galloway, MD §
Fox Chase Cancer Center

Jessica L. Geiger, MD †
Case Comprehensive Cancer Center/University Hospitals Seidman Cancer Center and Cleveland Clinic Taussig Cancer Institute

***Maura L. Gillison, MD, PhD †**
The University of Texas MD Anderson Cancer Center

Christine Glastonbury, MBBS ∩
UCSF Helen Diller Family Comprehensive Cancer Center

***Robert I. Haddad, MD †**
Dana-Farber/Brigham and Women's Cancer Center

Wesley L. Hicks, Jr., MD ¶
Roswell Park Comprehensive Cancer Center

Ying J. Hitchcock, MD §
Huntsman Cancer Institute at the University of Utah

***Antonio Jimeno, MD, PhD †**
University of Colorado Cancer Center

Aditya Juloori, MD §
The UChicago Medicine Comprehensive Cancer Center

Michael Kase, DMD ω
O'Neal Comprehensive Cancer Center at UAB

Alexander Ladenheim, MD
Yale Cancer Center/Smilow Cancer Hospital

Debra Leizman, MD Þ
Case Comprehensive Cancer Center/University Hospitals Seidman Cancer Center and Cleveland Clinic Taussig Cancer Institute

***Ellie Maghami, MD ¶ ξ**
City of Hope National Medical Center

Loren K. Mell, MD §
UC San Diego Moores Cancer Center

Bharat B. Mittal, MD §
Robert H. Lurie Comprehensive Cancer Center of Northwestern University

Harlan A. Pinto, MD † Þ
Stanford Cancer Institute

Katharine Price, MD †
Mayo Clinic Comprehensive Cancer Center

***James W. Rocco, MD, PhD ¶**
The Ohio State University Comprehensive Cancer Center - James Cancer Hospital and Solove Research Institute

***Cristina P. Rodriguez, MD † ‡**
Fred Hutchinson Cancer Center

David Schwartz, MD §
The University of Tennessee Health Science Center

***Jatin P. Shah, MD, PhD ¶**
Memorial Sloan Kettering Cancer Center

David Sher, MD, MPH §
UT Southwestern Simmons Comprehensive Cancer Center

Maie St. John, MD, PhD ¶
UCLA Jonsson Comprehensive Cancer Center

Gregory Weinstein, MD ¶
Abramson Cancer Center at the University of Pennsylvania

***Francis Worden, MD †**
University of Michigan Rogel Cancer Center

Justine Yang Bruce, MD †
University of Wisconsin Carbone Cancer Center

***Sue S. Yom, MD, PhD §**
UCSF Helen Diller Family Comprehensive Cancer Center

Weining Zhen, MD §
Fred & Pamela Buffett Cancer Center

NCCN
Susan Darlow, PhD
Sarah Montgomery, BA

ω Dental Oncology
∩ Diagnostic Radiology
‡ Hematology/Hematology oncology
Þ Internal medicine
† Medical oncology
ξ Otolaryngology
≠ Pathology
¥ Patient advocacy
§ Radiation oncology
¶ Surgery/Surgical oncology
* Discussion Writing Committee Member

NCCN Guidelines Panel Disclosures

Version 1.2026, 12/08/2025 © 2025 National Comprehensive Cancer Network® (NCCN®), All rights reserved. NCCN Guidelines® and this illustration may not be reproduced in any form without the express written permission of NCCN.

PLEASE NOTE that use of this NCCN Content is governed by the End-User License Agreement, and you MAY NOT distribute this Content or use it with any artificial intelligence model or tool.
Printed by Galya Basol Kochav on 1/4/2026 9:40:35 AM. Copyright © 2026 National Comprehensive Cancer Network, Inc. All Rights Reserved.

NCCN Guidelines Version 1.2026
Head and Neck Cancers

NCCN Head and Neck Cancers Panel Members
Summary of the Guidelines Updates

Multidisciplinary Team and Support Services (TEAM-1)
Cancer of the Oral Cavity (Including Mucosal Lip) (OR-1)
Cancer of the Oropharynx (ORPH-1)
• p16-negative (ORPH-2)
• p16 (HPV)-positive (ORPHPV-1)
Cancer of the Hypopharynx (HYPO-1)
Cancer of the Nasopharynx (NASO-1)
• Systemic Therapy for Nasopharyngeal Cancers (NASO-B)
Cancer of the Glottic Larynx (GLOT-1)
Cancer of the Supraglottic Larynx (SUPRA-1)
Ethmoid Sinus Tumors (ETHM-1)
Maxillary Sinus Tumors (MAXI-1)
Very Advanced Head and Neck Cancer (ADV-1)
Recurrent/Persistent Very Advanced Head and Neck Cancer (ADV-3)
Occult Primary (OCC-1)
Salivary Gland Tumors (SALI-1)
• Systemic Therapy for Salivary Gland Tumors (SALI-B)
Mucosal Melanoma (MM-1)
Follow-up Recommendations (FOLL-A)
Principles of Imaging (IMG-A)
Principles of Surgery (SURG-A)
Principles of Radiation Techniques (RAD-A)
Principles of Systemic Therapy for Non-Nasopharyngeal Cancers (SYST-A)
Principles of Nutrition: Management and Supportive Care (NUTR-A)
Principles of Oral/Dental Evaluation and Management (DENT-A)

Staging (ST-1)

Abbreviations (ABBR-1)

Find an NCCN Member Institution: https://www.nccn.org/home/member-institutions.

NCCN Categories of Evidence and Consensus: All recommendations are category 2A unless otherwise indicated.

See NCCN Categories of Evidence and Consensus.

NCCN Categories of Preference: All recommendations are considered appropriate.

See NCCN Categories of Preference.

The NCCN Guidelines® are a statement of evidence and consensus of the authors regarding their views of currently accepted approaches to treatment. Any clinician seeking to apply or consult the NCCN Guidelines is expected to use independent medical judgment in the context of individual clinical circumstances to determine any patient's care or treatment. The National Comprehensive Cancer Network® (NCCN®) makes no representations or warranties of any kind regarding their content, use or application and disclaims any responsibility for their application or use in any way. The NCCN Guidelines are copyrighted by National Comprehensive Cancer Network®. All rights reserved. The NCCN Guidelines and the illustrations herein may not be reproduced in any form without the express written permission of NCCN. ©2025.

PLEASE NOTE that use of this NCCN Content is governed by the End-User License Agreement, and you MAY NOT distribute this Content or use it with any artificial intelligence model or tool.
Printed by Galya Basol Kochav on 1/4/2026 9:40:35 AM. Copyright © 2026 National Comprehensive Cancer Network, Inc. All Rights Reserved.

Updates in Version 1.2026 of the NCCN Guidelines for Head and Neck Cancers include:

Global Changes
- References updated throughout the guideline.
- Instances of PDL-1 have been updated to read PDL-1 *positive* throughout the guideline.

TEAM-1
- General medical care ~~(NCCN Guidelines for Management of Immunotherapy-Related Toxicities)~~ *(NCCN Guidelines for Immune Checkpoint Inhibitor-Related Toxicities)*

OR-1
- Workup, bullet 3, sub-bullet modified: PD-L1 testing *by immunohistochemistry (IHC)* (combined positive score [CPS]) (Also for ORPH-1, HYPO-1, GLOT-1, and SUPRA-1)
- Workup, bullet added: Genetic testing in the context of early age of onset or family history
- Footnotes
  - Footnote c modified: Screen for ~~depression~~ *distress* ~~(NCCN Guidelines for Distress Management)~~. *Refer to the NCCN Distress Thermometer and Problem List, which includes social determinants of health. See NCCN Guidelines for Distress Management (DIS-A)*. (Also for ORPH-1, HYPO-1, NASO-1, GLOT-1, SUPRA-1, ETHM-1, OCC-1, SALI-1, and MM-1)
  - Footnote d modified: Image-guided (ultrasound [US] or CT) needle biopsy of cystic neck nodes may offer better diagnostic yield than fine-needle aspiration (FNA) by palpation alone for initial diagnosis in this setting. For unresectable or metastatic disease where there is a plan for systemic therapy, a core biopsy would allow for ~~ancillary immune-genomic~~ *biomarker* testing. (Also for ORPH-1, HYPO-1, NASO-1, GLOT-1, SUPRA-1, ETHM-1, OCC-2, SALI-1, and MM-1)

OR-A (1 of 2)
- Footnote b modified: For doses >70 Gy, some clinicians ~~feel~~ *think* that the fractionation should be slightly modified (eg, <2.0 Gy/fraction for at least some of the treatment) to minimize toxicity. An additional 2–3 doses can be added depending on clinical circumstances. (Also for ORPH-A 1 of 2, HYPO-A 1 of 2, NASO-A, GLOT-A, SUPRA-A 1 of 2, ETHM-A, MAXI-A, ADV-A 2 of 2, OCC-A 1 of 2, and SALI-A)

OR-A (2 of 2)
- Bullet 1 modified: Preferred interval between resection and *initiation of* postoperative RT is ≤6 weeks. (Also for ORPH-A 2 of 2, HYPO-A 2 of 2, GLOT-A 2 of 2, SUPRA-A 2 of 2, ETHM-A, MAXI-A, ADV-A 2 of 2, OCC-A 2 of 2, SALI-A, and MM-A)
- Note modified: For T1–T2 simple lip lesions, treat with postoperative RT as per ~~non-melanoma skin cancers~~ *skin cancers excluding melanoma*.

ORPHPV-2
- Footnote u modified: De-escalation to 50 Gy may be considered in patients with p16 (HPV)-positive oropharynx cancer who have ≤4 positive *ipsilateral* lymph nodes *with the largest ≤6 cm*, T1–T2 resected to negative or close margins (<3 mm)~~, and/or N1–N2 disease (excluding bilateral disease based on ECOG 3311 criteria)~~ with ≤1 mm extranodal extension *based on ECOG 3311 Intermediate Risk criteria* (Ferris RL, et al. J Clin Oncol 2022;40:138-149) (category 2B). (Also for OPHPV-3)

ORPH-A (1 of 2)
- Definitive, PTV
  - High risk: Hyperfractionation for T2,N0–1 disease: *74.4*–81.6 Gy/*6*–7 weeks (1.2 Gy/fraction, twice daily)

Continued

Version 1.2026, 12/08/2025 © 2025 National Comprehensive Cancer Network® (NCCN®), All rights reserved. NCCN Guidelines® and this illustration may not be reproduced in any form without the express written permission of NCCN.

PLEASE NOTE that use of this NCCN Content is governed by the End-User License Agreement, and you MAY NOT distribute this Content or use it with any artificial intelligence model or tool.
Printed by Galya Basol Kochav on 1/4/2026 9:40:35 AM. Copyright © 2026 National Comprehensive Cancer Network, Inc. All Rights Reserved.

Updates in Version 1.2026 of the NCCN Guidelines for Head and Neck Cancers include:

ORPH-B
- Bullet 2 modified: Distinguishing *patients with* p16+ *tumors* ~~patients~~ by HPV tumor status informs prognosis. Patients with p16+ and HPV+ tumors have an improved prognosis compared to patients with p16+ and HPV-negative tumors.
- Bullet 6 modified: A small proportion of tumors at non-oropharyngeal sites (eg, paranasal sinus, oral cavity, larynx) are HPV-related. However, given the small proportion and lack of consistent evidence in support of prognostic significance, routine HPV testing or p16 testing of ~~non-oropharyngeal~~ cancers ~~outside of the oropharynx and sinonasal tract~~ is not recommended.
- Bullet 8 modified: When using p16 ~~testing~~, the 70% cutoff with nuclear and cytoplasmic expression with at least moderate to strong intensity is recommended.

HYPO-2
- Treatment of Primary and Neck, option modified: Partial laryngopharyngectomy (open or endoscopic) + ipsilateral or bilateral neck dissection ± ~~hemi~~thyroidectomy, and pretracheal and ipsilateral paratracheal lymph node dissection

HYPO-3
- Treatment of Primary and Neck, option modified: Partial or total laryngopharyngectomy + ipsilateral or bilateral neck dissection ± ~~hemi- or total~~ thyroidectomy and pretracheal and ipsilateral paratracheal lymph node dissection

HYPO-4
- Primary site: <PR, option modified: Unresectable *primary or* nodal disease

HYPO-5
- Treatment of Primary and Neck, option modified: Total laryngopharyngectomy + ipsilateral or bilateral neck dissection ± ~~hemi- or total~~ thyroidectomy, after ipsilateral or bilateral paratracheal lymph node dissection

HYPO-6
- Primary site: <PR
  - Option modified: Surgery ~~+ neck dissection as indicated~~
  - Option modified: Unresectable *primary or* nodal disease

NASO-1
- Workup, bullet 6 modified: ~~Consider~~ Epstein-Barr virus (EBV)/DNA testing
- Workup, bullet 7 modified: *Consider* HPV testing (may inform etiology)
- Footnote e modified: "For nonkeratinizing or undifferentiated histology, consider testing for EBV in tumor *tissue* and blood. Common means for detecting EBV in pathologic specimens include ISH for EBV-encoded RNA (EBER) or ~~immunohistochemical~~ *IHC* staining for latent membrane protein (LMP)..."

NASO-A
- Footnote e modified: ~~Principles of Systemic Therapy for Non-Nasopharyngeal Cancers (SYST-A).~~ *Systemic Therapy for Nasopharyngeal Cancers (NASO-B).*

Continued

Version 1.2026, 12/08/2025 © 2025 National Comprehensive Cancer Network® (NCCN®), All rights reserved. NCCN Guidelines® and this illustration may not be reproduced in any form without the express written permission of NCCN.

PLEASE NOTE that use of this NCCN Content is governed by the End-User License Agreement, and you MAY NOT distribute this Content or use it with any artificial intelligence model or tool.
Printed by Galya Basol Kochav on 1/4/2026 9:40:35 AM. Copyright © 2026 National Comprehensive Cancer Network, Inc. All Rights Reserved.

Updates in Version 1.2026 of the NCCN Guidelines for Head and Neck Cancers include:

NASO-B (1 of 4)
- Bullet 1 modified: The choice of systemic therapy should be individualized based on patient characteristics *and goals of therapy.* ~~(eg, PS, goals of therapy)~~
- Bullet 2 modified: Use *multigene panel testing (MGPT)* ~~NGS profiling~~ and other appropriate biomarker testing to test for at least ~~CPS~~ *PD-L1 expression and, tumor mutational burden (*TMB*), and mismatch repair (MMR)* prior to treatment. (category 2B)
- Bullet 3 added: Nivolumab and hyaluronidase-nvhy subcutaneous injection may be substituted for IV nivolumab. Nivolumab and hyaluronidase-nvhy has different dosing and administration instructions compared to IV nivolumab.
- Bullet 4 added: Pembrolizumab and berahyaluronidase alfa-pmph subcutaneous injection may be substituted for IV pembrolizumab. Pembrolizumab and berahyaluronidase alfa-pmph has different dosing and administration instructions compared to IV pembrolizumab.
- Footnote b added: For more information regarding DPYD testing, see the NCCN Guidelines for Colon Cancer. (Also for NASO-B 2 of 2, SYST-A 1 of 7, SYST-A 2 of 7, SYST-A 3 of 7, and SYST-A 4 of 7)
- Footnote removed: Nivolumab and hyaluronidase-nvhy subcutaneous injection may be substituted for IV nivolumab. Nivolumab and hyaluronidase-nvhy has different dosing and administration instructions compared to IV nivolumab. (Also for SYST-A 4 of 7)

GLOT-1
- Workup, bullet 3 modified: CT with contrast and thin angled cuts *or cuts <1.25 mm* through larynx and/or MRI with and without contrast of primary and neck (Also for SUPRA-1)

GLOT-5
- Primary site: <PR
  - Option modified: ~~Laryngectomy~~ *Surgery*
  - Option modified: Unresectable *primary or* nodal disease

GLOT-6
- T4a,N0-3
  - Treatment Option Modified: Surgery, including ipsilateral or bilateral neck dissection; thyroidectomy to clear central compartment nodes, especially when there is ~~external pharyngeal~~ *extralaryngeal* extension of the thyroid gland and significant subglottic extension
- Stage modified: Selected *patients with* T4a *primary* ~~patients~~ who decline surgery

GLOT-A (1 of 2)
- Definitive, RT Alone, bullet 4 modified: *T3,N0 or* ≥T2,N1

SUPRA-2
- Treatment of Primary and Neck, option removed: Endoscopic resection + neck dissection

SUPRA-7
- Primary site: <PR, treatment option modified: Unresectable *primary or* nodal disease

ETHM-2
- Footnote q modified: Adverse pathologic features: positive margins, close margins (tumors adjacent to the cribriform plate and/or medial wall of the orbit), unfavorable histology (ie, *adenoid cystic,* high-grade *tumors,* ~~adenoid cystic~~), intracranial and/or intraorbital extension, cribriform plate location, medial wall of orbit location, perineural invasion, and lymphovascular space invasion (Discussion). (Also for ETHM-3)

MAXI-2
- Footnote h modified: See the salivary gland algorithm for management after resection. See ~~NCCN Guidelines for~~ Salivary Gland Tumors (SALI-1). (Also for MAXI-3)

Continued

Version 1.2026, 12/08/2025 © 2025 National Comprehensive Cancer Network® (NCCN®), All rights reserved. NCCN Guidelines® and this illustration may not be reproduced in any form without the express written permission of NCCN.

PLEASE NOTE that use of this NCCN Content is governed by the End-User License Agreement, and you MAY NOT distribute this Content or use it with any artificial intelligence model or tool.
Printed by Galya Basol Kochav on 1/4/2026 9:40:35 AM. Copyright © 2026 National Comprehensive Cancer Network, Inc. All Rights Reserved.

Updates in Version 1.2026 of the NCCN Guidelines for Head and Neck Cancers include:

ADV-1
- Diagnosis option modified: Unresectable *primary or* nodal disease
- Pathway removed: Newly diagnosed disease
- Footnote a added: If no prior RT.

ADV-2
- Treatment of Head and Neck Cancer
  - PS 2-3 option modified: *Combination (PS 2 only) or* single-agent systemic therapy

ADV-3
- Footnote g modified: Consider ~~NGS genomic profiling~~ *MGPT* for biomarker identification. (Also for ADV-4)

OCC-2
- Node level I, II, III, upper V
  - Workup, bullet 3: Biopsy of areas of clinical concern and tonsillectomy ± lingual tonsillectomy *(only for squamous cell carcinoma [SCC])*
- Footnote n modified: HPV and EBV testing are suggested if not yet done. *If HPV positive, see ORPH-1. If EBV positive, see NASO-1.*

OCC-3
- Footnote q modified: Treatment for nasopharyngeal (NASO-2) and p16-positive oropharyngeal cancers (ORPHPV-3 and ORPHPV-4) to guide management of EBV-positive and ~~p16-~~ *HPV*-positive occult primary tumors.

OCC-4
- Footnote t added: Refer to ST-16 for staging criteria.

OCC-A (1 of 2)
- Footnote g added: If HPV positive, target oropharynx. If EBV positive, target nasopharynx. Avoid total mucosal irradiation. (Also for OCC-A 2 of 2)

SALI-1
- Clinical presentation option modified: ~~Unresected~~ Salivary gland mass *(unresected or incompletely resected)*
- Clinical presentation option removed: Incompletely resected salivary gland mass

SALI-2
- Clinically benign or T1,T2
  - Pathology result option modified: Adenoid cystic; *or* Intermediate or high grade

SALI-3
- Completely resected
  - Adverse pathological features option modified: *High-grade* T3–4a tumors

SALI-4
- Footnote p modified: Use ~~NGS profiling~~ *MGPT* and other appropriate biomarker testing to check status of at least the following: androgen receptor (AR), HER2, NTRK*1/2/3*, FGFR, BRAF, RET, microsatellite instability (MSI), mismatch repair deficiency (dMMR), ~~tumor mutational burden (~~TMB~~)~~, and programmed death ligand 1 (PD-L1) prior to treatment. (category 2B).

SALI-A
- Definitive, PTV
  - Low to intermediate risk, dosing modified: 44–50 Gy (2.0 Gy/fraction) to 54–63 Gy (~~1.6–~~1.8–*2.0* Gy/fraction) (Also for Postoperative RT)

Continued

Version 1.2026, 12/08/2025 © 2025 National Comprehensive Cancer Network® (NCCN®), All rights reserved. NCCN Guidelines® and this illustration may not be reproduced in any form without the express written permission of NCCN.

PLEASE NOTE that use of this NCCN Content is governed by the End-User License Agreement, and you MAY NOT distribute this Content or use it with any artificial intelligence model or tool.
Printed by Galya Basol Kochav on 1/4/2026 9:40:35 AM. Copyright © 2026 National Comprehensive Cancer Network, Inc. All Rights Reserved.

Updates in Version 1.2026 of the NCCN Guidelines for Head and Neck Cancers include:

SALI-B (1 of 2)
- Recurrent, Unresectable, or Metastatic Salivary Gland Tumors (with no surgery or RT option)
  - Bullet 1 modified: The choice of systemic therapy should be individualized based on patient characteristics *and goals of therapy* ~~(eg, PS, goals of therapy).~~
  - Bullet 2 added: *Pembrolizumab and berahyaluronidase alfa-pmph subcutaneous injection may be substituted for IV pembrolizumab. Pembrolizumab and berahyaluronidase alfa-pmph has different dosing and administration instructions compared to IV pembrolizumab.*
  - Useful in Certain Circumstances
    - Header modified: ~~NTRK therapy f~~ *F*or NTRK*1/2/3* gene fusion-positive tumors
    - *Header added:* Other targeted therapies
      - Option modified: Erdafitinib for FGFR mutations or *gene* fusion-*positive tumors* and disease progression with at least one line of prior systemic therapy and no availability of an alternative systemic therapy (category 2B)

MM-A
- Details on Optional dosing schedules moved from footnote to text.
- Footnote c added: Suggest 44–50 Gy in sequentially planned IMRT or 54–63 Gy with IMRT dose painting technique (dependent on dose per fraction).

FOLL-A (1 of 2)
- Bullet 4 modified: ~~Thyroid-stimulating hormone (~~TSH~~)~~ every 6–12 mo if neck irradia*tion*~~ed~~ *and/or partial thyroidectomy*
- Bullet 7 added: Consider venous duplex ultrasound of the neck every 3 years if neck irradiated
- Bullet 10 added: Survivorship
  - Sub-bullet added: Additional health monitoring and immunizations should be performed as indicated under the care of a primary care physician

IMG-A (1 of 4)
- Initial Workup, Primary Site
  - Sub-bullet 2, sub-sub-bullet removed: To evaluate cartilage invasion
  - Sub-bullet 3, sub-sub-bullet 2 modified: To assess skull base invasion*,* ~~and~~ cranial nerve involvement, *and perineural tumor spread*
    - Sub-sub-sub bullet added: As a dedicated larynx protocol study for equivocal cartilage penetration on CT
  - Sub-bullet 4 modified: "...For certain conditions, such as involved lymph nodes in the low neck or cancers that frequently involve the upper mediastinum (such as thyroid cancer), the imaging should extend to the carina. *When mediastinal nodes must be evaluated (eg, for thyroid carcinoma), recommend obtaining a contrast enhanced CT scan in addition to the neck CT."*
  - Sub-bullet 5 modified: "...In addition, FNA biopsy of metastatic *or equivocal* nodes may be pathologically informative. Image-guided (~~ultrasound [~~US~~]~~ or CT) needle biopsy of cystic neck nodes may offer better diagnostic yield than FNA by palpation alone for initial diagnosis in this setting."

IMG-A (2 of 4)
- Distant metastases, sub-bullet 3 modified: ~~Non-contrast~~ *Low-dose* CT of the chest can be sufficient to screen for lung parenchymal metastases but is not adequate for assessment of mediastinal adenopathy. This is an appropriate lung cancer screening intervention for patients with a history of smoking. See NCCN Guidelines for Lung Cancer Screening.

Continued

Version 1.2026, 12/08/2025 © 2025 National Comprehensive Cancer Network® (NCCN®), All rights reserved. NCCN Guidelines® and this illustration may not be reproduced in any form without the express written permission of NCCN.

PLEASE NOTE that use of this NCCN Content is governed by the End-User License Agreement, and you MAY NOT distribute this Content or use it with any artificial intelligence model or tool.
Printed by Galya Basol Kochav on 1/4/2026 9:40:35 AM. Copyright © 2026 National Comprehensive Cancer Network, Inc. All Rights Reserved.

Updates in Version 1.2026 of the NCCN Guidelines for Head and Neck Cancers include:

IMG-A (3 of 4)
- Locoregionally Advanced Disease: <6 Months Post-Treatment (Short-Term)
  - Bullet 3 modified: In cases of concern for ~~incomplete~~ *non*-response *or disease progression*, a CT or MRI scan may be obtained much earlier, such as 4–8 weeks post-treatment or even immediately based on the specific clinical situation. US of the neck for targeted sampling of any suspicious tissues may also be helpful, but results can be variably interpreted depending on the specific clinical situation.
    - Sub-bullet added: Early CT/MRI scans before 8 weeks are associated with significant false-positive rates and should be avoided in the absence of signs of recurrence or progression.
  - Bullet 4 modified: FDG-PET/CT should be performed within 3~~–6~~ months of definitive radiation*,* ~~or~~ systemic therapy/RT*, surgery, or adjuvant RT* for assessment of treatment response and to identify any residual tumor.
    - Sub-bullet 2 modified: The optimal timing of PET scans after radiation treatment appears to be at ~~the~~ 3~~- to 6-~~month~~window~~. A *second* negative PET *performed at 6 months after this baseline has a high negative prediction value, and radiologic assessment can be suspended for patients with asymptomatic disease* ~~at this time point predicts improved overall survival at 2 years.~~

SURG-A (3 of 9)
- Primary Tumor Resection
  - Bullet 6 modified: "... In the ~~edentulous~~ patient *with complete edentulism* due to mandibular atrophy that occurs over time, a partial mandibulectomy may not be possible. The extent of mandibular resection will depend on the degree of involvement accessed clinically and in the operating room."
  - Bullet 8 modified: "...For T4 or N2–3 laryngeal cancers treated with surgery, consideration should be given to thyroidectomy for tumor clearance and clearance of central compartment pretracheal or paratracheal nodes. *Consider the risks and benefits versus improved locoregional control."*

RAD-A (4 of 7)
- Reirradiation with SBRT, PBT, or IMRT
  - Reirradiation dosing, sub-bullet 3 modified: Hyperfractionation for locally advanced nasopharyngeal carcinoma: IMRT total dose of ~~65~~ *64.8* Gy, in 54 fractions, twice daily, with an irradiation interval of 6–8 hours

SYST-A (1 of 7)
- Header added: General Principles
- Bullet 1 modified: The choice of systemic therapy should be individualized based on patient characteristics *and goals of therapy* ~~(eg, PS, goals of therapy). Next-generation sequencing (NGS) genomic profiling~~ *Multigene panel testing (MGPT) and other appropriate biomarker testing*, including testing for at least ~~combined positive score (CPS)~~ *PD-L1 expression*, microsatellite instability (MSI), ~~d~~MMR, ~~tumor mutational burden (~~TMB~~)~~, HER2, and FGFR may be considered to guide patient treatment options, including clinical trials.
- Bullet 6 added: Imaging every 2–3 cycles of treatment in the recurrent/metastatic setting.
- Bullet 7 added: Nivolumab and hyaluronidase-nvhy subcutaneous injection may be substituted for IV nivolumab. Nivolumab and hyaluronidase-nvhy has different dosing and administration instructions compared to IV nivolumab. Nivolumab and hyaluronidase-nvhy is not approved for concurrent use with IV ipilimumab.
- Bullet 8 added: Pembrolizumab and berahyaluronidase alfa-pmph subcutaneous injection may be substituted for IV pembrolizumab. Pembrolizumab and berahyaluronidase alfa-pmph has different dosing and administration instructions compared to IV pembrolizumab.

Continued

Version 1.2026, 12/08/2025 © 2025 National Comprehensive Cancer Network® (NCCN®), All rights reserved. NCCN Guidelines® and this illustration may not be reproduced in any form without the express written permission of NCCN.

PLEASE NOTE that use of this NCCN Content is governed by the End-User License Agreement, and you MAY NOT distribute this Content or use it with any artificial intelligence model or tool.
Printed by Galya Basol Kochav on 1/4/2026 9:40:35 AM. Copyright © 2026 National Comprehensive Cancer Network, Inc. All Rights Reserved.

Updates in Version 1.2026 of the NCCN Guidelines for Head and Neck Cancers include:

SYST-A (4 of 7)
- Useful in Certain Circumstances
  - Regimen added: Enfortumab vedotin-ejfv (if disease progression on or after platinum therapy and a PD-1/PD-L1 inhibitor) (category 2B)
  - Regimen modified: Erdafitinib for FGFR mutations or *gene* fusion *positive tumors* and disease progression with at least one line of prior systemic therapy and no availability of an alternative systemic therapy (category 2B)

NUTR-A (1 of 3)
- Assessment and Management
  - Nutrition, sub-bullet 1 modified: "...All patients should be evaluated for nutritional risks and should receive nutrition counseling by a registered dietitian and/or indicated treatment with various nutrition interventions, such as feeding tubes (eg, nasogastric [NG] tubes, *nasojejunal [NJ] tubes,* percutaneous endoscopic gastrostomy [PEG] tubes*, percutaneous endoscopic jejunostomy [PEJ] tubes*) or intravenous nutrition support (but only if enteral support is not feasible)."
  - Speech and Swallowing
    - Sub-bullet 5 modified: Maintain *and/or improve oropharyngeal movement through* range of motion *and strengthening exercises.*~~, which may include the following:~~
      - Sub-sub-bullet added: Prophylactic and/or rehabilitative pharyngeal strengthening exercises and expiratory strength training
    - Sub-bullet 6 added: Patients with tracheostomy
      - Sub-sub-bullet added: Facilitating communication, humidification, swallowing, and working towards de-cannulation with head and neck surgeon, respiratory therapy, and speech language pathology teams as indicated.

NUTR-A (2 of 3)
- Assessment and Management Continued
  - Pain, sub-bullet 1 modified: Assess pain from oral mucositis and ~~prescribe~~ *consider prescribing* pregabalin (category 2B), gabapentin, doxepin, or
- Header modified: Use of Alternative Routes for Nutrition (~~NG and PEG~~ *feeding* tubes)
  - Bullet 1 modified: The Panel does not recommend prophylactic ~~PEG or NG~~ *feeding* tube placement in patients with very good PS and without significant pretreatment weight loss, significant airway obstruction, or severe dysphagia.
  - Bullet 3 modified: For those who did not warrant prophylactic ~~PEG or NG~~ *feeding* tube placement pre-treatment, caloric intake, treatment-related side effects, and change in body weight should be monitored weekly during treatment. Consider reactive feeding tube placement if two or more of the following criteria apply:

ST-3
- AJCC Staging Version Updated from 8th edition to 9th edition.

Version 1.2026, 12/08/2025 © 2025 National Comprehensive Cancer Network® (NCCN®), All rights reserved. NCCN Guidelines® and this illustration may not be reproduced in any form without the express written permission of NCCN.

PLEASE NOTE that use of this NCCN Content is governed by the End-User License Agreement, and you MAY NOT distribute this Content or use it with any artificial intelligence model or tool.
Printed by Galya Basol Kochav on 1/4/2026 9:40:35 AM. Copyright © 2026 National Comprehensive Cancer Network, Inc. All Rights Reserved.

MULTIDISCIPLINARY TEAM

The comprehensive care of patients with head and neck cancers is complex. All patients need access to the full range of support services and specialists with expertise in the comprehensive care of patients with head and neck cancer for optimal treatment and follow-up. Outcomes are improved when patients with head and neck cancers are treated at high-volume centers.

- Head and neck surgery
- Radiation oncology
- Medical oncology
- Diagnostic and interventional radiology
- Plastic and reconstructive surgery
- Specialized nursing care
- Dentistry/prosthodontics
- Physical medicine and rehabilitation (including therapy for lymphedema of the neck)
- Speech and swallowing therapy
- Clinical social work
- Clinical nutrition
- Pathology (including cytopathology)
- Adjunctive services
  - Neurosurgery
  - Ophthalmology
  - Psychiatry
  - Addiction services
  - Audiology
  - Palliative care
  - Pain management

SUPPORT SERVICES

Follow-up should be performed by a physician and other health care professionals with expertise in the comprehensive care and prevention of treatment sequelae. It should include a comprehensive head and neck exam. The comprehensive care of patients with head and neck cancer may involve the following:

- General medical care (NCCN Guidelines for Immune Checkpoint Inhibitor-Related Toxicities)
- Pain and symptom management (NCCN Guidelines for Adult Cancer Pain)
- Nutritional support
  - Enteral feeding
  - Oral nutrition
- Dental care for radiation therapy (RT) effects
- Xerostomia management
- Smoking and alcohol cessation (NCCN Guidelines for Smoking Cessation)
- Speech and swallowing therapy
- Audiology
- Tracheotomy care
- Wound management
- Depression assessment and management (NCCN Guidelines for Distress Management)
- Social work and case management
- Care coordination
- Supportive care (NCCN Guidelines for Palliative Care)
- Physical therapy (lymphedema management)

Version 1.2026, 12/08/2025 © 2025 National Comprehensive Cancer Network® (NCCN®), All rights reserved. NCCN Guidelines® and this illustration may not be reproduced in any form without the express written permission of NCCN.

PLEASE NOTE that use of this NCCN Content is governed by the End-User License Agreement, and you MAY NOT distribute this Content or use it with any artificial intelligence model or tool.
Printed by Galya Basol Kochav on 1/4/2026 9:40:35 AM. Copyright © 2026 National Comprehensive Cancer Network, Inc. All Rights Reserved.

Buccal mucosa, floor of mouth, oral tongue, alveolar ridge, retromolar trigone, hard palate[a]

WORKUP

- History and physical (H&P)[b,c] including a complete head and neck exam; mirror and fiberoptic examination as clinically indicated
- Biopsy[d]
- As clinically indicated:
  - Chest CT (with or without contrast)[e]
  - CT with contrast and/or MRI with and without contrast of primary and neck
  - Consider FDG-PET/CT[e,f]
  - Examination under anesthesia (EUA) with endoscopy
  - Preanesthesia studies
  - Dental/prosthodontic evaluation,[g] including Panorex or dental CT without contrast[e]
  - Nutrition, speech, and swallowing evaluation/therapy[h]
  - Smoking cessation counseling[b]
  - Fertility/reproductive counseling[i]
  - Screening for hepatitis B
  - PD-L1 testing by immunohistochemistry (IHC) (combined positive score [CPS])
- Multidisciplinary consultation as clinically indicated
- Genetic testing in the context of early age of onset or family history

CLINICAL STAGING

- T1–2,N0 → Treatment of Primary and Neck (OR-2)
- T3,N0 → Treatment of Primary and Neck (OR-3)
- T1–3,N1–3 → Treatment of Primary and Neck (OR-3)
- T4a,N0–3 → Treatment of Primary and Neck (OR-3)
- T4b,N0–3 or Unresectable nodal disease or Unfit for surgery → Treatment of Very Advanced Head and Neck Cancer (ADV-1)
- Metastatic (M1) disease at initial presentation → Treatment of Very Advanced Head and Neck Cancer (ADV-2)

[a] Cutaneous squamous cell carcinoma of the vermilion lip is not included in this guideline. See NCCN Guidelines for Squamous Cell Skin Cancer.
[b] H&P should include documentation and quantification (pack years smoked) of tobacco use history, as well as alcohol use and counseling. All patients who currently smoke should be advised to quit smoking, and those who formerly smoked should be advised to remain abstinent from smoking. For additional cessation support, refer to the Smoking Cessation and Treatment Resources in the NCCN Guidelines for Smoking Cessation.
[c] Screen for distress. Refer to the NCCN Distress Thermometer and Problem List, which includes social determinants of health. See NCCN Guidelines for Distress Management (DIS-A).
[d] Image-guided (ultrasound [US] or CT) needle biopsy of cystic neck nodes may offer better diagnostic yield than fine-needle aspiration (FNA) by palpation alone for initial diagnosis in this setting. For unresectable or metastatic disease where there is a plan for systemic therapy, a core biopsy would allow for biomarker testing.
[e] Principles of Imaging (IMG-A).
[f] Discussion.
[g] Principles of Oral/Dental Evaluation and Management (DENT-A).
[h] Principles of Nutrition: Management and Supportive Care (NUTR-A).
[i] See fertility and reproductive endocrine considerations in the NCCN Guidelines for Adolescent and Young Adult (AYA) Oncology.

Note: All recommendations are category 2A unless otherwise indicated.

Version 1.2026, 12/08/2025 © 2025 National Comprehensive Cancer Network® (NCCN®), All rights reserved. NCCN Guidelines® and this illustration may not be reproduced in any form without the express written permission of NCCN.

PLEASE NOTE that use of this NCCN Content is governed by the End-User License Agreement, and you MAY NOT distribute this Content or use it with any artificial intelligence model or tool.
Printed by Galya Basol Kochav on 1/4/2026 9:40:35 AM. Copyright © 2026 National Comprehensive Cancer Network, Inc. All Rights Reserved.

Buccal mucosa, floor of mouth, oral tongue, alveolar ridge, retromolar trigone, hard palate[a]

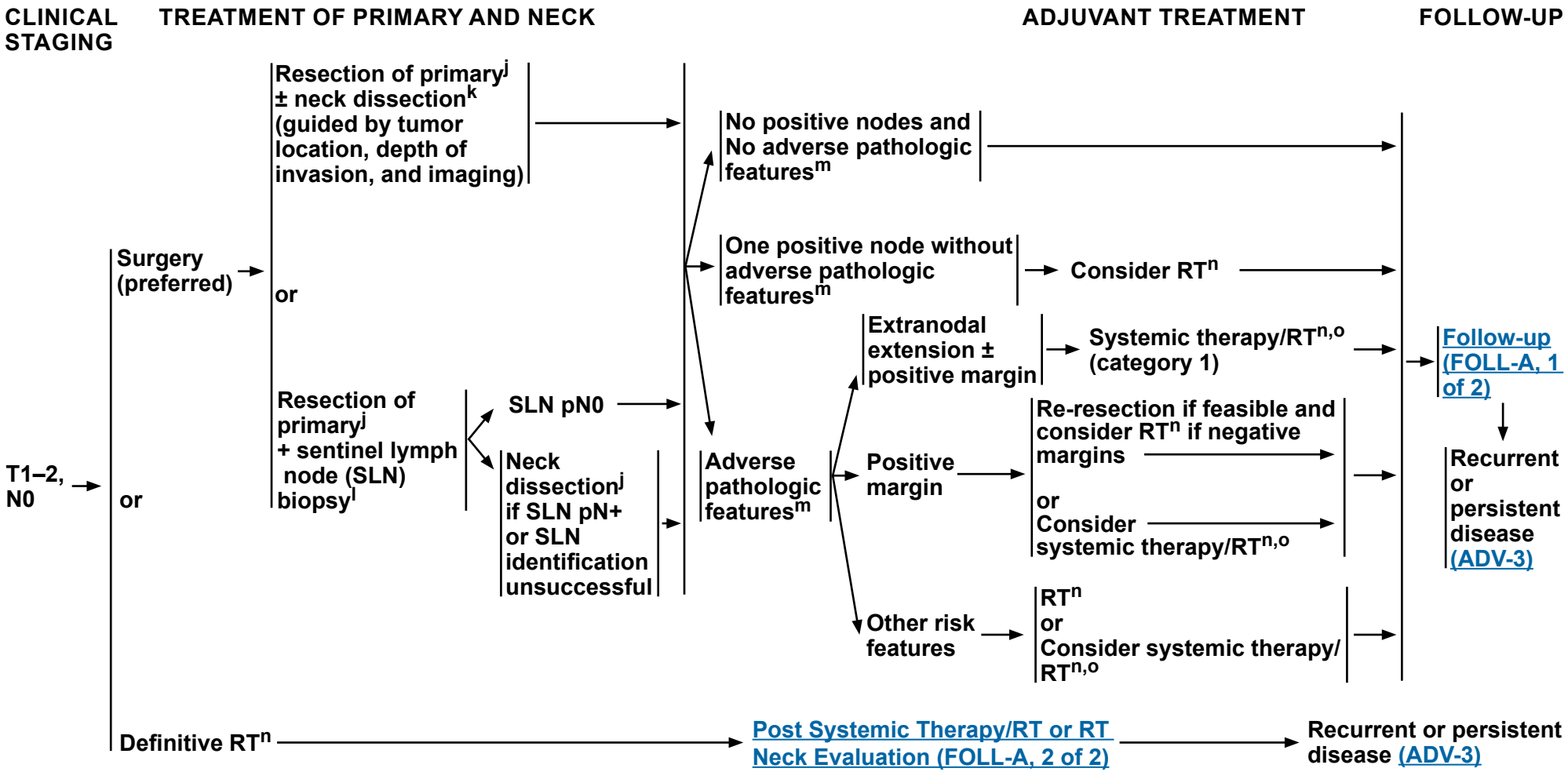

[a] Cutaneous squamous cell carcinoma of the vermilion lip is not included in this guideline. See NCCN Guidelines for Squamous Cell Skin Cancer.
[j] Principles of Surgery (SURG-A).
[k] Neck dissection is generally not indicated for T1–3,N0 mucosal lip.
[l] Data are limited on the efficacy of SLN biopsy for oral cavity cancers. See Sentinel Lymph Node Biopsy in Principles of Surgery (SURG-A, 7 of 9).
[m] Adverse pathologic features: extranodal extension, positive margins, close margins, pT3 or pT4 primary, pN2 or pN3 nodal disease, nodal disease in levels IV or V, perineural invasion, vascular invasion, and lymphatic invasion (Discussion).
[n] Principles of Radiation Therapy (OR-A).
[o] Principles of Systemic Therapy for Non-Nasopharyngeal Cancers (SYST-A).

Note: All recommendations are category 2A unless otherwise indicated.

Version 1.2026, 12/08/2025 © 2025 National Comprehensive Cancer Network® (NCCN®), All rights reserved. NCCN Guidelines® and this illustration may not be reproduced in any form without the express written permission of NCCN.

PLEASE NOTE that use of this NCCN Content is governed by the End-User License Agreement, and you MAY NOT distribute this Content or use it with any artificial intelligence model or tool.
Printed by Galya Basol Kochav on 1/4/2026 9:40:35 AM. Copyright © 2026 National Comprehensive Cancer Network, Inc. All Rights Reserved.

Buccal mucosa, floor of mouth, oral tongue, alveolar ridge, retromolar trigone, hard palate[a]

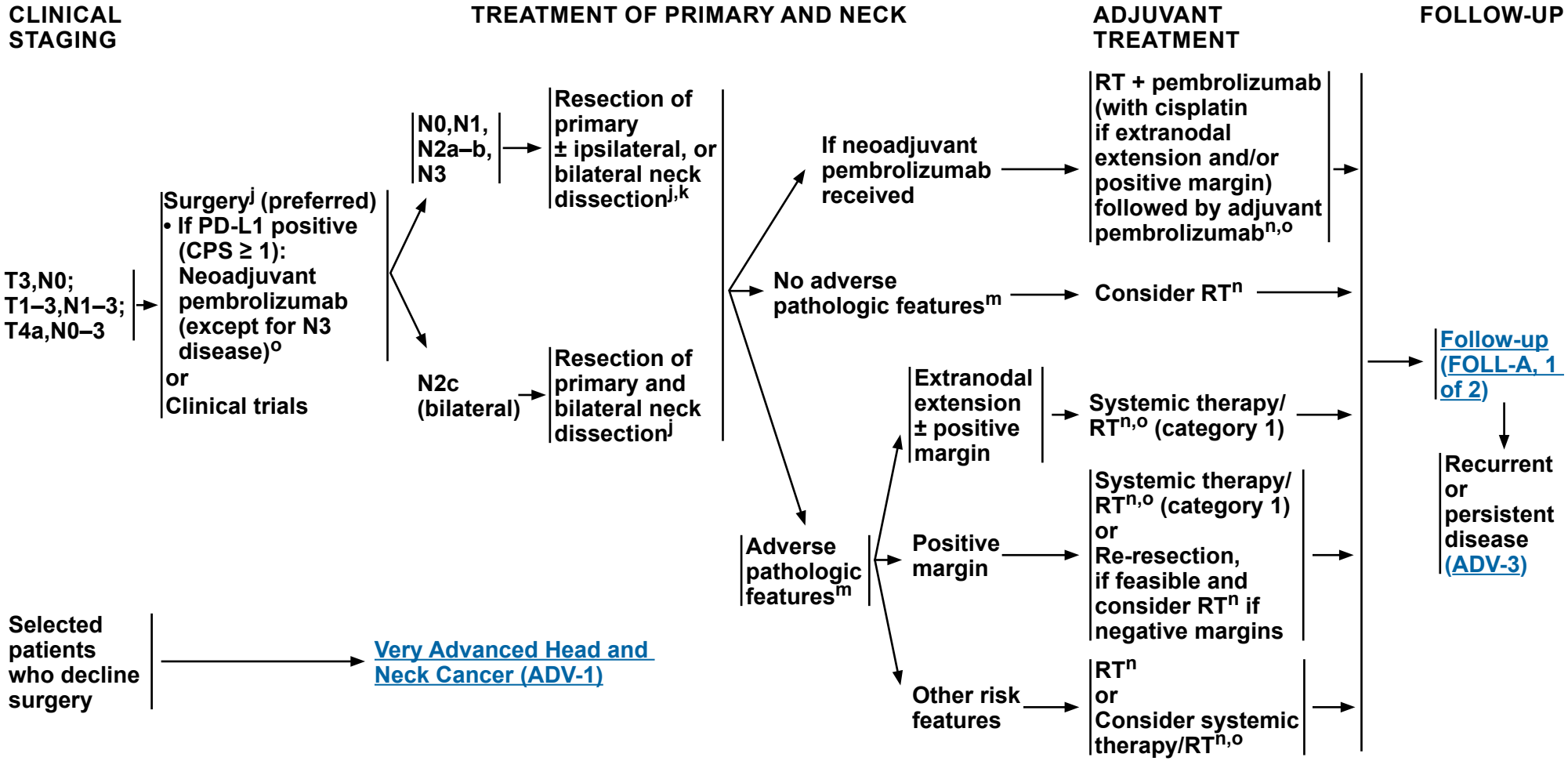

[a] Cutaneous squamous cell carcinoma of the vermilion lip is not included in this guideline. See NCCN Guidelines for Squamous Cell Skin Cancer.
[j] Principles of Surgery (SURG-A).
[k] Neck dissection is generally not indicated for T1–3,N0 mucosal lip.

[m] Adverse pathologic features: extranodal extension, positive margins, close margins, pT3 or pT4 primary, pN2 or pN3 nodal disease, nodal disease in levels IV or V, perineural invasion, vascular invasion, and lymphatic invasion (Discussion).
[n] Principles of Radiation Therapy (OR-A).
[o] Principles of Systemic Therapy for Non-Nasopharyngeal Cancers (SYST-A).

Note: All recommendations are category 2A unless otherwise indicated.

Version 1.2026, 12/08/2025 © 2025 National Comprehensive Cancer Network® (NCCN®), All rights reserved. NCCN Guidelines® and this illustration may not be reproduced in any form without the express written permission of NCCN.

PLEASE NOTE that use of this NCCN Content is governed by the End-User License Agreement, and you MAY NOT distribute this Content or use it with any artificial intelligence model or tool.
Printed by Galya Basol Kochav on 1/4/2026 9:40:35 AM. Copyright © 2026 National Comprehensive Cancer Network, Inc. All Rights Reserved.

PRINCIPLES OF RADIATION THERAPY[a]

DEFINITIVE:

RT Alone

- **Planning target volume (PTV)**
  - **High risk: Primary tumor and involved lymph nodes [this includes possible local subclinical infiltration at the primary site and at the high-risk level lymph node(s)]:**
    - ◊ **Fractionation:**
      - – **66 Gy (2.2 Gy/fraction) to 70 Gy (2.0 Gy/fraction); daily Monday–Friday in 6–7 weeks[b]**
      - – **Concomitant boost accelerated RT:**
        - – **72 Gy/6 weeks (1.8 Gy/fraction, large field; 1.5 Gy boost as second daily fraction during last 12 treatment days)**
        - – **66–70 Gy (2.0 Gy/fraction; 6 fractions/wk accelerated)**
      - – **Hyperfractionation: 81.6 Gy/7 weeks (1.2 Gy/fraction, twice daily)**
  - **Low to intermediate risk: Sites of suspected subclinical spread**
    - ◊ **45–50 Gy (1.8 Gy/fraction) to 54–63 Gy (1.6–1.8 Gy/fraction)[c]**
- **Brachytherapy**
  - **Interstitial brachytherapy is considered for selected cases.[d,e]**
    - ◊ **Low dose-rate (LDR) brachytherapy (0.4–0.5 Gy/h):**
      - – **Consider LDR boost 20–35 Gy if combined with 50 Gy external beam RT (EBRT) or 60–70 Gy over several days if using LDR as sole therapy.**
    - ◊ **High dose-rate (HDR) brachytherapy:**
      - – **Consider HDR boost 21 Gy at 3 Gy/fraction if combined with 40–50 Gy EBRT or 45–60 Gy at 3–6 Gy/fraction if using HDR as sole therapy.**

For unresectable disease, see ADV-1.

Intensity-modulated RT (IMRT) (preferred) is recommended.

[a] See Principles of Radiation Techniques (RAD-A) and Discussion.
[b] For doses >70 Gy, some clinicians think that the fractionation should be slightly modified (eg, <2.0 Gy/fraction for at least some of the treatment) to minimize toxicity. An additional 2–3 doses can be added depending on clinical circumstances.
[c] Suggest 45–50 Gy in sequentially planned IMRT or 54–63 Gy with IMRT dose painting technique (dependent on dose per fraction).
[d] Brachytherapy should be performed at centers where there is expertise in this modality (Nag S, Cano ER, Demanes DJ, et al. The American Brachytherapy Society recommendations for high-dose-rate brachytherapy for head-neck carcinomas. Int J Radiat Oncol Biol Phys 2001;50:1190-1198; Mazeron JJ, Ardiet JM, Hale-Meder C, et al. GEC-ESTRO recommendations for brachytherapy for head and neck squamous cell carcinomas. Radiother Oncol 2009;91:150-156.)
[e] The interval between EBRT and brachytherapy should be as short as possible (1–2 weeks) depending on recovery from acute toxicity. The interval between HDR fractions should be at least 6 hours.

Note: All recommendations are category 2A unless otherwise indicated.

Version 1.2026, 12/08/2025 © 2025 National Comprehensive Cancer Network® (NCCN®), All rights reserved. NCCN Guidelines® and this illustration may not be reproduced in any form without the express written permission of NCCN.

PLEASE NOTE that use of this NCCN Content is governed by the End-User License Agreement, and you MAY NOT distribute this Content or use it with any artificial intelligence model or tool.
Printed by Galya Basol Kochav on 1/4/2026 9:40:35 AM. Copyright © 2026 National Comprehensive Cancer Network, Inc. All Rights Reserved.

PRINCIPLES OF RADIATION THERAPY[a]

POSTOPERATIVE:

RT or Concurrent Systemic Therapy/RT[f,1-4]

- **Preferred interval between resection and initiation of postoperative RT is ≤6 weeks.**
- **PTV**
  - **High risk: Adverse pathologic features such as positive margins (see footnote m on OR-3)**
    - **60–66 Gy (2.0 Gy/fraction); daily Monday–Friday in 6–6.5 weeks**
  - **Low to intermediate risk: Sites of suspected subclinical spread**
    - **45–50 Gy (1.8 Gy/fraction) to 54–63 Gy (1.6–1.8 Gy/fraction)[c]**

IMRT (preferred) is recommended.

For T1–T2 simple lip lesions, treat with postoperative RT as per skin cancers excluding melanoma.

- **NCCN Guidelines for Basal Cell Skin Cancer**
- **NCCN Guidelines for Squamous Cell Skin Cancer**

[a] See Principles of Radiation Techniques (RAD-A) and Discussion.
[c] Suggest 45–50 Gy in sequentially planned IMRT or 54–63 Gy with IMRT dose painting technique (dependent on dose per fraction).
[f] Principles of Systemic Therapy for Non-Nasopharyngeal Cancers (SYST-A).

[1] Bernier J, Domenge C, Ozsahin M, et al. Postoperative irradiation with or without concomitant chemotherapy for locally advanced head and neck cancer. N Engl J Med 2004;350:1945-1952.
[2] Cooper JS, Pajak TF, Forastiere AA, et al. Postoperative concurrent radiotherapy and chemotherapy for high-risk squamous-cell carcinoma of the head and neck. N Engl J Med 2004;350:1937-1944.
[3] Bernier J, Cooper JS, Pajak TF, et al. Defining risk levels in locally advanced head and neck cancers: A comparative analysis of concurrent postoperative radiation plus chemotherapy trials of the EORTC (#22931) and RTOG (#9501). Head Neck 2005;27:843-850.
[4] Cooper JS, Zhang Q, Pajak TF, et al. Long-term follow-up of the RTOG 9501/intergroup phase III trial: postoperative concurrent radiation therapy and chemotherapy in high-risk squamous cell carcinoma of the head and neck. Int J Radiat Oncol Biol Phys 2012;84:1198-1205.

Note: All recommendations are category 2A unless otherwise indicated.

Version 1.2026, 12/08/2025 © 2025 National Comprehensive Cancer Network® (NCCN®), All rights reserved. NCCN Guidelines® and this illustration may not be reproduced in any form without the express written permission of NCCN.

PLEASE NOTE that use of this NCCN Content is governed by the End-User License Agreement, and you MAY NOT distribute this Content or use it with any artificial intelligence model or tool.
Printed by Galya Basol Kochav on 1/4/2026 9:40:35 AM. Copyright © 2026 National Comprehensive Cancer Network, Inc. All Rights Reserved.

Base of Tongue/Tonsil/Posterior Pharyngeal Wall/Soft Palate

WORKUP

- Tumor human papillomavirus (HPV) testing by p16 IHC required[a]
- H&P[b,c] including a complete head and neck exam; mirror and fiberoptic examination as clinically indicated
- Biopsy of primary site or fine-needle aspiration (FNA) of the neck[d]
- CT with contrast and/or MRI with and without contrast of primary and neck[e]
- As clinically indicated:
  - EUA with endoscopy[f]
  - Preanesthesia studies
  - FDG-PET/CT[e]
  - Chest CT[e] (with or without contrast)
  - Dental evaluation[g] including Panorex
  - Nutrition, speech, and swallowing evaluation/therapy, and audiogram[h]
  - Smoking cessation counseling[b]
  - Fertility/reproductive counseling[i]
  - Screening for hepatitis B
  - PD-L1 testing by IHC (CPS)
- Multidisciplinary consultation as clinically indicated

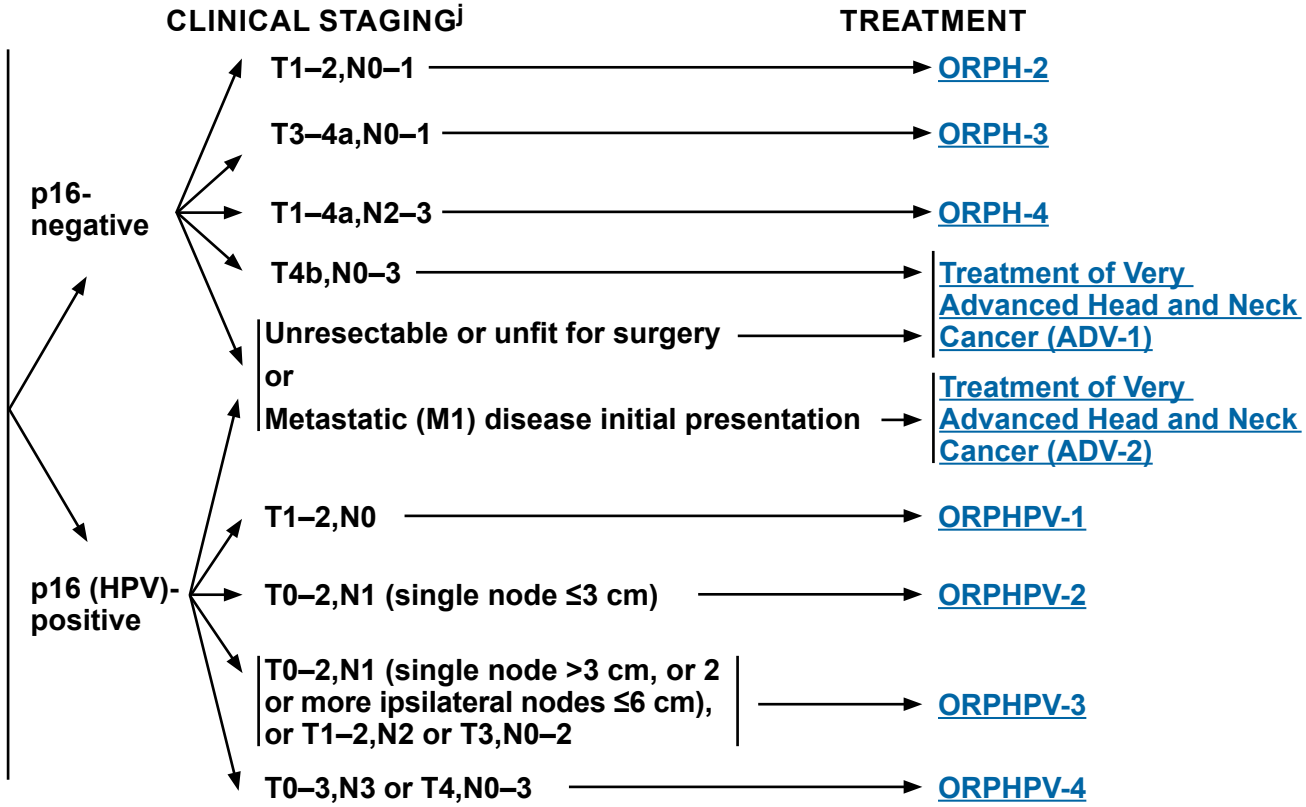

[a] Principles of p16 Testing for HPV-Mediated Oropharyngeal Cancer (ORPH-B).
[b] H&P should include documentation and quantification (pack years smoked) of tobacco use history, as well as alcohol use and counseling. All patients who currently smoke should be advised to quit smoking, and those who formerly smoked should be advised to remain abstinent from smoking. For additional cessation support, refer to the Smoking Cessation and Treatment Resources in the NCCN Guidelines for Smoking Cessation.
[c] Screen for distress. Refer to the NCCN Distress Thermometer and Problem List, which includes social determinants of health. See NCCN Guidelines for Distress Management (DIS-A).
[d] Image-guided (US or CT) needle biopsy of cystic neck nodes may offer better diagnostic yield than FNA by palpation alone for initial diagnosis in this setting. For unresectable or metastatic disease where there is a plan for systemic therapy, a core biopsy would allow for biomarker testing.
[e] Principles of Imaging (IMG-A).
[f] Prior to treatment, EUA with biopsy confirmation of the oropharyngeal primary site is recommended for patients presenting with a p16+ cervical lymph node. See Principles of Surgical Management (SURG-A).
[g] Principles of Oral/Dental Evaluation and Management (DENT-A).
[h] Principles of Nutrition: Management and Supportive Care (NUTR-A).
[i] See fertility and reproductive endocrine considerations in the NCCN Guidelines for Adolescent and Young Adult (AYA) Oncology.
[j] The clinical staging definitions are based on the AJCC 8th edition for oropharynx cancer (see ST-4 for p16-, and see ST-7 for p16+). Definitions for nodal staging criteria previously used in clinical trials (AJCC 7th edition) on the management of oropharynx cancer are included.

Note: All recommendations are category 2A unless otherwise indicated.

Version 1.2026, 12/08/2025 © 2025 National Comprehensive Cancer Network® (NCCN®), All rights reserved. NCCN Guidelines® and this illustration may not be reproduced in any form without the express written permission of NCCN.

PLEASE NOTE that use of this NCCN Content is governed by the End-User License Agreement, and you MAY NOT distribute this Content or use it with any artificial intelligence model or tool.
Printed by Galya Basol Kochav on 1/4/2026 9:40:35 AM. Copyright © 2026 National Comprehensive Cancer Network, Inc. All Rights Reserved.

Base of Tongue/Tonsil/Posterior Pharyngeal Wall/Soft Palate

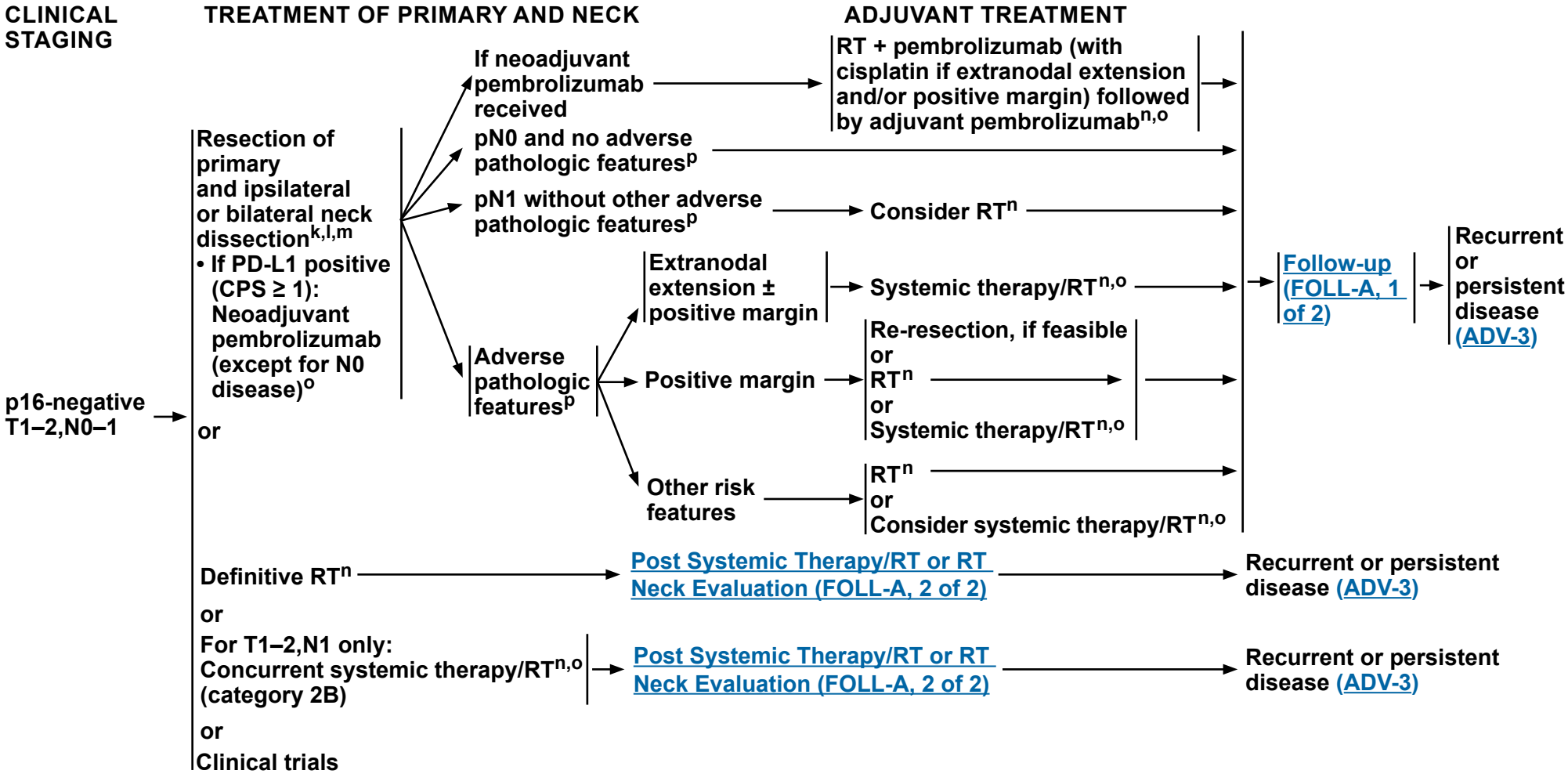

[k] Principles of Surgery (SURG-A).
[l] Tumors in the base of tongue, posterior pharyngeal wall, and soft palate require consideration of bilateral neck treatment as do tumors of the tonsil invading the tongue base.
[m] For pN0–N1 and no poor pathologic risk features, single-modality treatment should be considered whenever possible. For T1–T2 primary tumors near midline and resected to adequate margins and with no adverse pathologic features, a staged contralateral neck dissection can be performed in order to avoid RT. Lateral tumors pN0–N1 resected with favorable pathologic features can be observed.
[n] Principles of Radiation Therapy (ORPH-A).
[o] Principles of Systemic Therapy for Non-Nasopharyngeal Cancers (SYST-A).
[p] Adverse pathologic features: extranodal extension, positive margins, close margins, pT3 or pT4 primary, pN2 or pN3 nodal disease, nodal disease in levels IV or V, perineural invasion, vascular invasion, and lymphatic invasion (Discussion).

Note: All recommendations are category 2A unless otherwise indicated.

Version 1.2026, 12/08/2025 © 2025 National Comprehensive Cancer Network® (NCCN®), All rights reserved. NCCN Guidelines® and this illustration may not be reproduced in any form without the express written permission of NCCN.

PLEASE NOTE that use of this NCCN Content is governed by the End-User License Agreement, and you MAY NOT distribute this Content or use it with any artificial intelligence model or tool.
Printed by Galya Basol Kochav on 1/4/2026 9:40:35 AM. Copyright © 2026 National Comprehensive Cancer Network, Inc. All Rights Reserved.

Base of Tongue/Tonsil/Posterior Pharyngeal Wall/Soft Palate

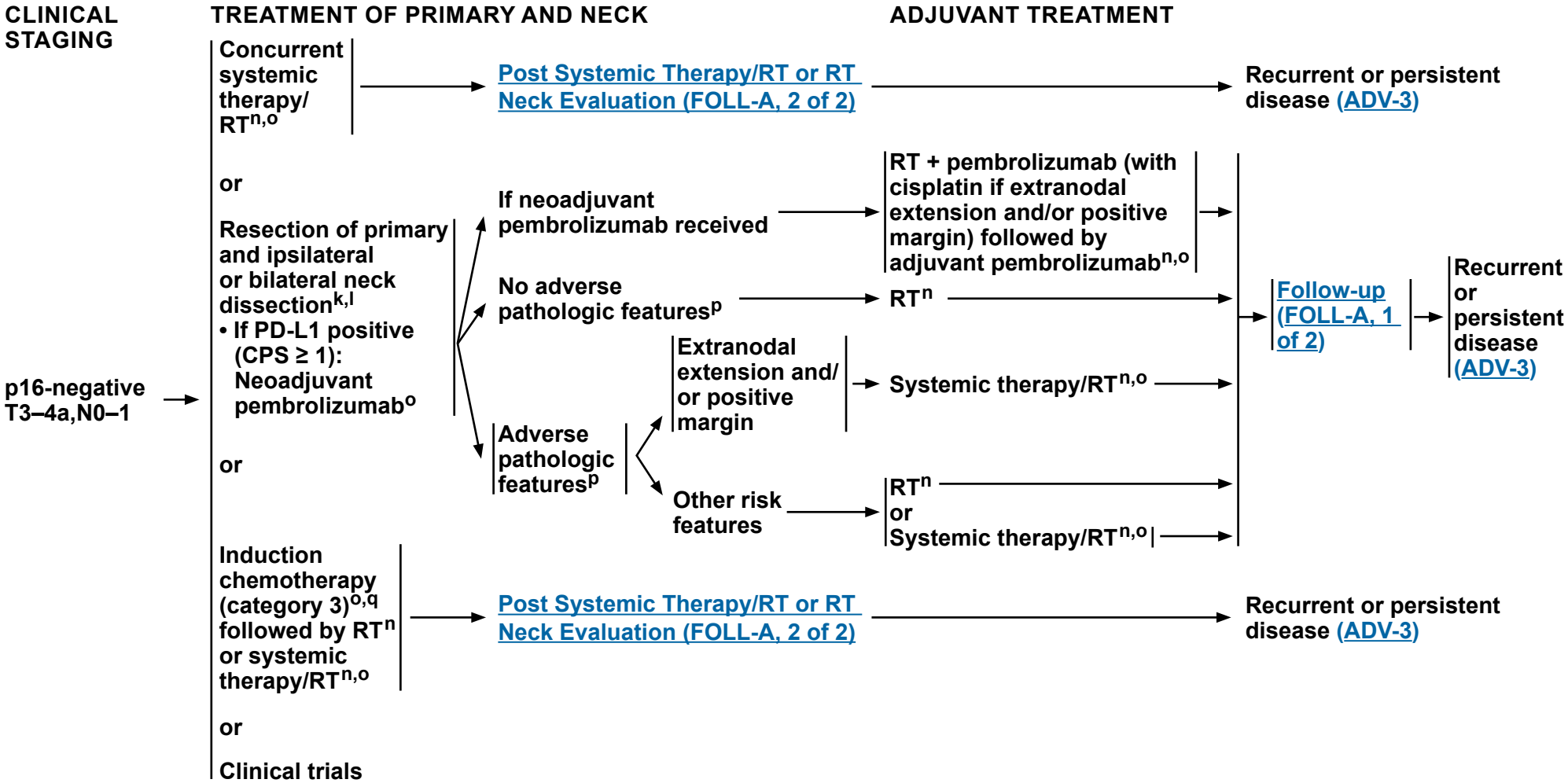

[k] Principles of Surgery (SURG-A).
[l] Tumors in the base of tongue, posterior pharyngeal wall, and soft palate require consideration of bilateral neck treatment as do tumors of the tonsil invading the tongue base.
[n] Principles of Radiation Therapy (ORPH-A).
[o] Principles of Systemic Therapy for Non-Nasopharyngeal Cancers (SYST-A).
[p] Adverse pathologic features: extranodal extension, positive margins, close margins, pT3 or pT4 primary, pN2 or pN3 nodal disease, nodal disease in levels IV or V, perineural invasion, vascular invasion, and lymphatic invasion (Discussion).
[q] See Discussion on induction chemotherapy.

Note: All recommendations are category 2A unless otherwise indicated.

Version 1.2026, 12/08/2025 © 2025 National Comprehensive Cancer Network® (NCCN®), All rights reserved. NCCN Guidelines® and this illustration may not be reproduced in any form without the express written permission of NCCN.

PLEASE NOTE that use of this NCCN Content is governed by the End-User License Agreement, and you MAY NOT distribute this Content or use it with any artificial intelligence model or tool.
Printed by Galya Basol Kochav on 1/4/2026 9:40:35 AM. Copyright © 2026 National Comprehensive Cancer Network, Inc. All Rights Reserved.

Base of Tongue/Tonsil/Posterior Pharyngeal Wall/Soft Palate

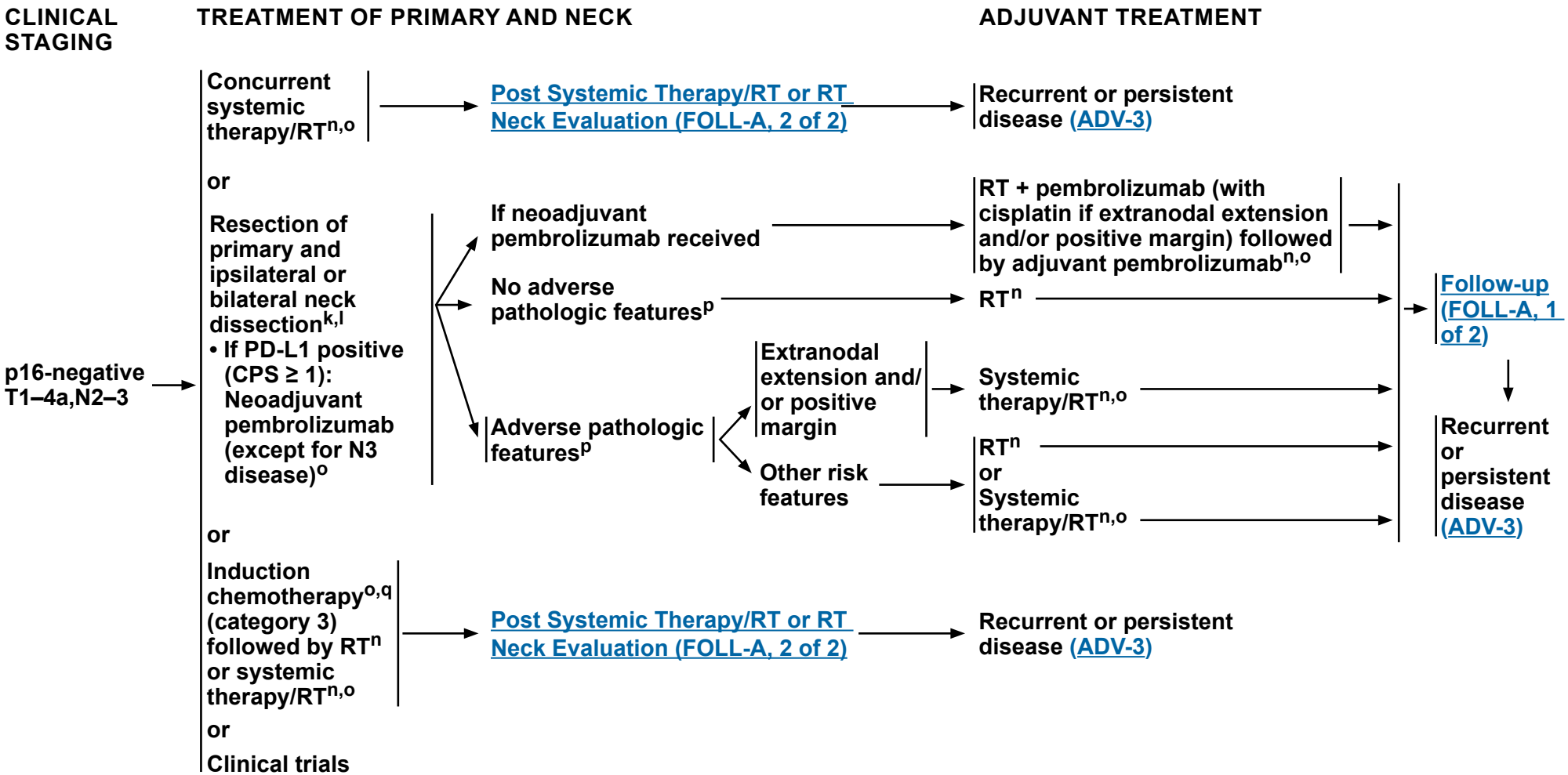

[k] Principles of Surgery (SURG-A).
[l] Tumors in the base of tongue, posterior pharyngeal wall, and soft palate require consideration of bilateral neck treatment as do tumors of the tonsil invading the tongue base.
[n] Principles of Radiation Therapy (ORPH-A).
[o] Principles of Systemic Therapy for Non-Nasopharyngeal Cancers (SYST-A).
[p] Adverse pathologic features: extranodal extension, positive margins, close margins, pT3 or pT4 primary, pN2 or pN3 nodal disease, nodal disease in levels IV or V, perineural invasion, vascular invasion, and lymphatic invasion (Discussion).
[q] See Discussion on induction chemotherapy.

Note: All recommendations are category 2A unless otherwise indicated.

Version 1.2026, 12/08/2025 © 2025 National Comprehensive Cancer Network® (NCCN®), All rights reserved. NCCN Guidelines® and this illustration may not be reproduced in any form without the express written permission of NCCN.

PLEASE NOTE that use of this NCCN Content is governed by the End-User License Agreement, and you MAY NOT distribute this Content or use it with any artificial intelligence model or tool.
Printed by Galya Basol Kochav on 1/4/2026 9:40:35 AM. Copyright © 2026 National Comprehensive Cancer Network, Inc. All Rights Reserved.

Base of Tongue/Tonsil/Posterior Pharyngeal Wall/Soft Palate

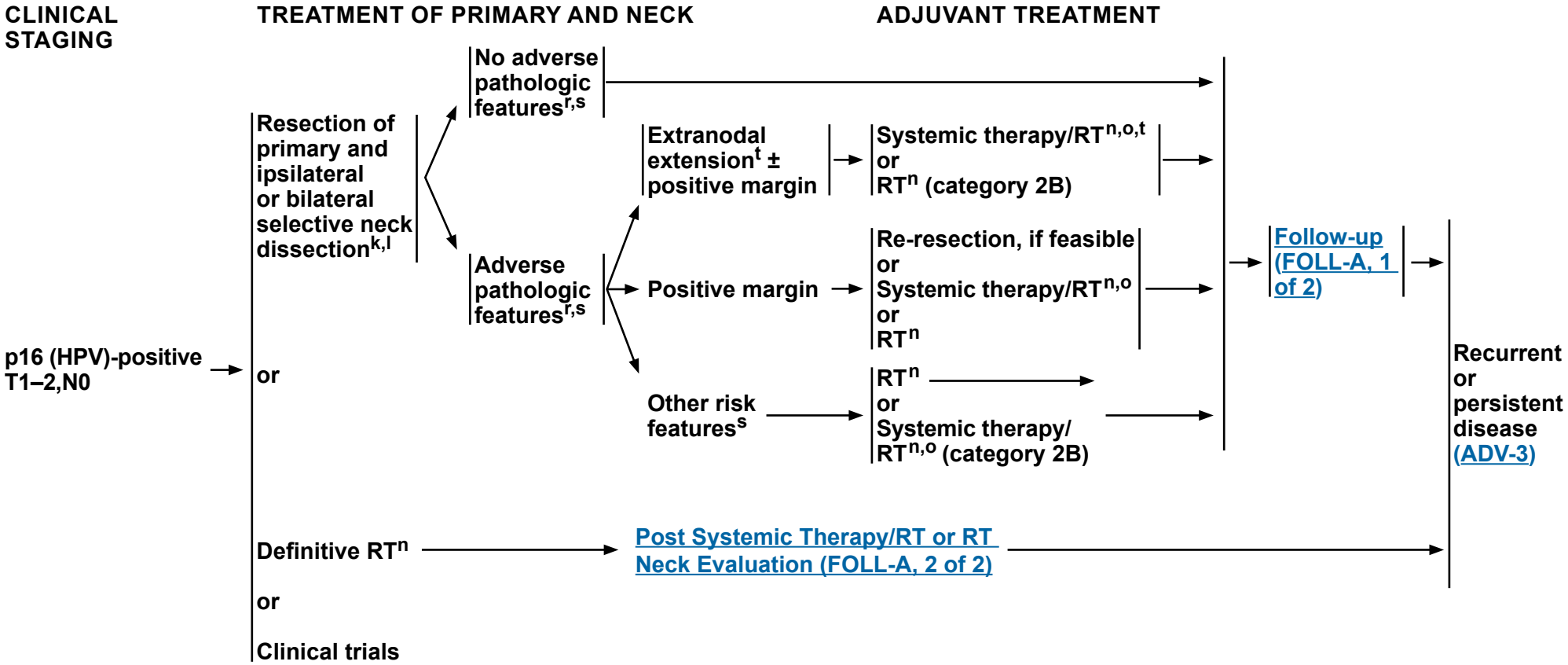

[k] Principles of Surgery (SURG-A).
[l] Tumors in the base of tongue, posterior pharyngeal wall, and soft palate require consideration of bilateral neck treatment as do tumors of the tonsil invading the tongue base.
[n] Principles of Radiation Therapy (ORPH-A).
[o] Principles of Systemic Therapy for Non-Nasopharyngeal Cancers (SYST-A).
[r] Pathologic staging criteria differ from clinical staging criteria in HPV-mediated oropharyngeal cancer. For pathologic stage following resection, see AJCC 8th edition for appropriate staging criteria (ST-7).
[s] Adverse pathologic features: extranodal extension, positive margins, close margins (<3 mm), pT3 or pT4 primary, one positive node >3 cm or multiple positive nodes, nodal disease in levels IV or V, perineural invasion, vascular invasion, and lymphatic invasion (Discussion). The definition of an adverse pathologic feature in the context of HPV+ disease is an area of active research. This includes the presence and extent of extranodal extension, and the number of involved nodes.
[t] The recommendations for patients at high risk with extranodal extension + positive margins are based on randomized studies involving patients for whom the HPV status of their tumors was not specified.

Note: All recommendations are category 2A unless otherwise indicated.

Version 1.2026, 12/08/2025 © 2025 National Comprehensive Cancer Network® (NCCN®), All rights reserved. NCCN Guidelines® and this illustration may not be reproduced in any form without the express written permission of NCCN.

PLEASE NOTE that use of this NCCN Content is governed by the End-User License Agreement, and you MAY NOT distribute this Content or use it with any artificial intelligence model or tool.
Printed by Galya Basol Kochav on 1/4/2026 9:40:35 AM. Copyright © 2026 National Comprehensive Cancer Network, Inc. All Rights Reserved.

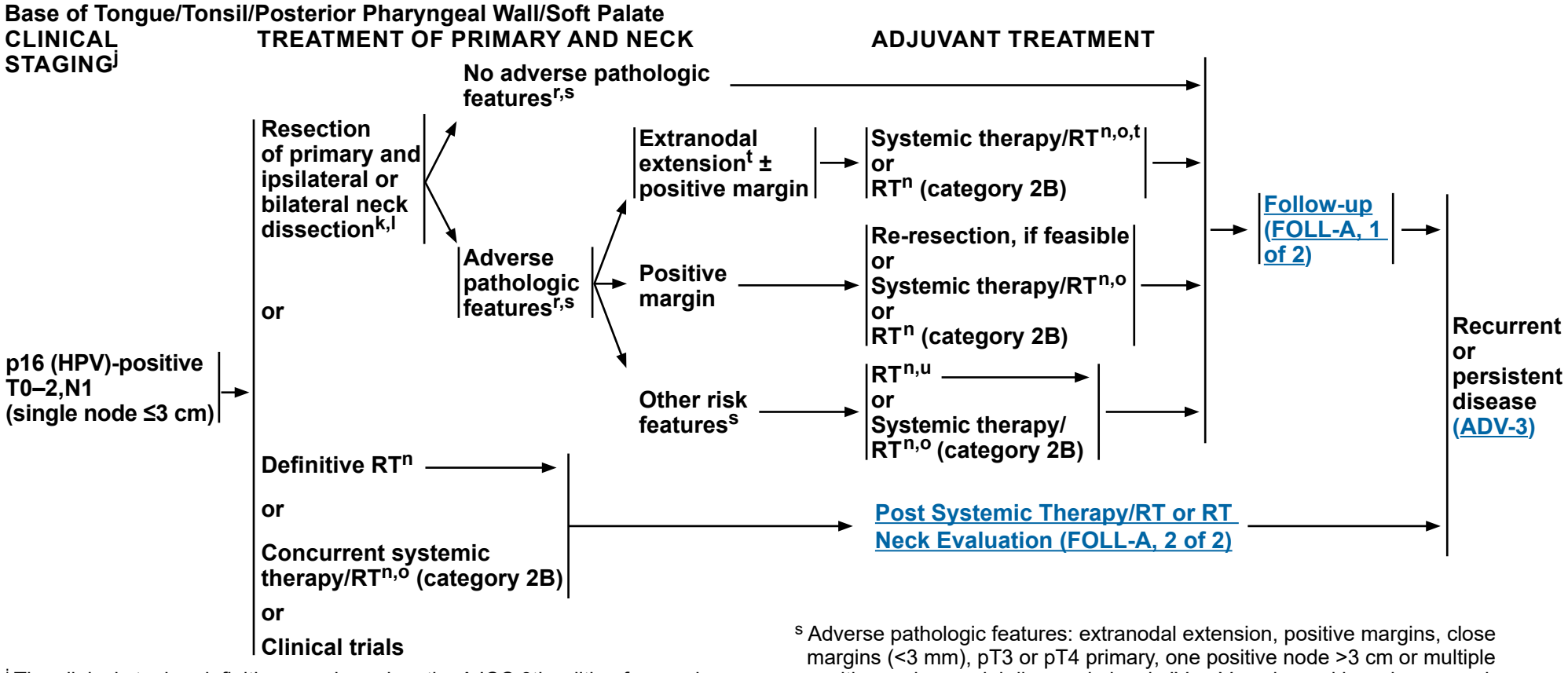

[j] The clinical staging definitions are based on the AJCC 8th edition for oropharynx cancer (see ST-4 for p16-, and see ST-7 for p16+). Definitions for nodal staging criteria previously used in clinical trials (AJCC 7th edition) on the management of oropharynx cancer are included.

[k] Principles of Surgery (SURG-A).

[l] Tumors in the base of tongue, posterior pharyngeal wall, and soft palate require consideration of bilateral neck treatment as do tumors of the tonsil invading the tongue base.

[n] Principles of Radiation Therapy (ORPH-A).

[o] Principles of Systemic Therapy for Non-Nasopharyngeal Cancers (SYST-A).

[r] Pathologic staging criteria differ from clinical staging criteria in HPV-mediated oropharyngeal cancer. For pathologic stage following resection, see AJCC 8th edition for appropriate staging criteria (ST-7).

[s] Adverse pathologic features: extranodal extension, positive margins, close margins (<3 mm), pT3 or pT4 primary, one positive node >3 cm or multiple positive nodes, nodal disease in levels IV or V, perineural invasion, vascular invasion, and lymphatic invasion (Discussion). The definition of an adverse pathologic feature in the context of HPV+ disease is an area of active research. This includes the presence and extent of extranodal extension, and the number of involved nodes.

[t] The recommendations for patients at high risk with extranodal extension + positive margins are based on randomized studies involving patients for whom the HPV status of their tumors was not specified.

[u] De-escalation to 50 Gy may be considered in patients with p16 (HPV)-positive oropharynx cancer who have ≤4 positive ipsilateral lymph nodes with the largest ≤6 cm, T1–T2 resected to negative or close margins (<3 mm) with ≤1 mm extranodal extension based on ECOG 3311 Intermediate Risk criteria (Ferris RL, et al. J Clin Oncol 2022;40:138-149) (category 2B).

Note: All recommendations are category 2A unless otherwise indicated.

Version 1.2026, 12/08/2025 © 2025 National Comprehensive Cancer Network® (NCCN®), All rights reserved. NCCN Guidelines® and this illustration may not be reproduced in any form without the express written permission of NCCN.

PLEASE NOTE that use of this NCCN Content is governed by the End-User License Agreement, and you MAY NOT distribute this Content or use it with any artificial intelligence model or tool.
Printed by Galya Basol Kochav on 1/4/2026 9:40:35 AM. Copyright © 2026 National Comprehensive Cancer Network, Inc. All Rights Reserved.

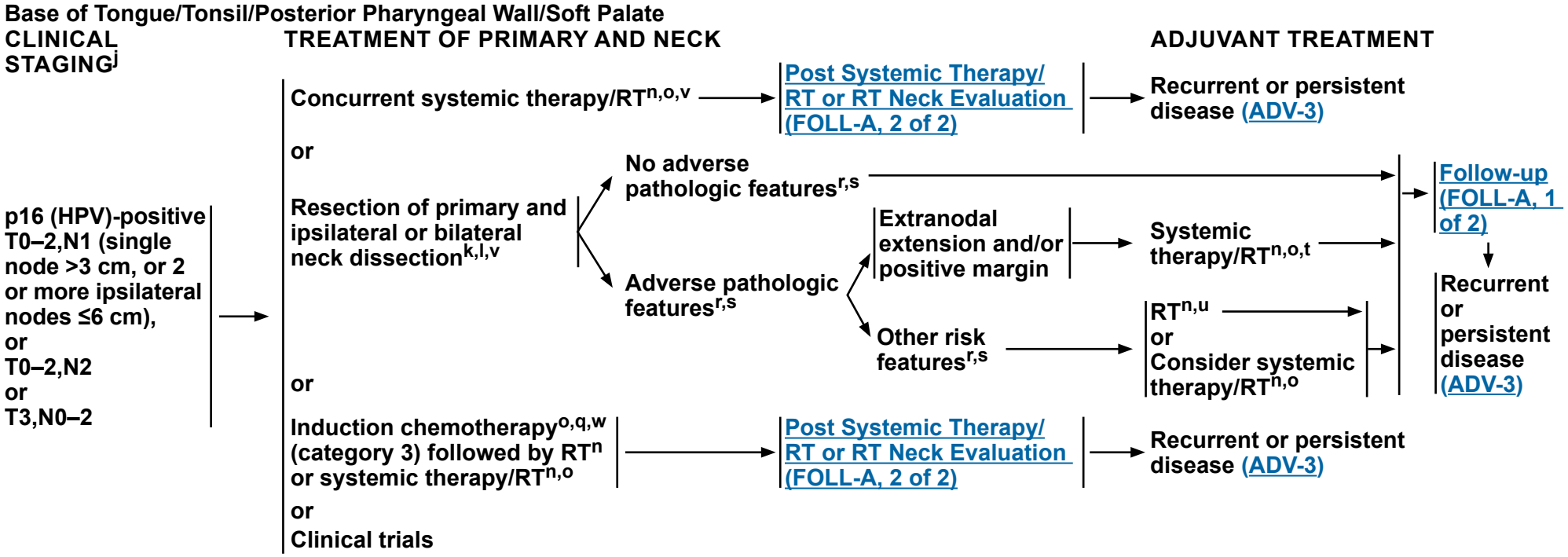

[j] The clinical staging definitions are based on the AJCC 8th edition for oropharynx cancer (see ST-4 for p16-, and see ST-7 for p16+). Definitions for nodal staging criteria previously used in clinical trials (AJCC 7th edition) on the management of oropharynx cancer are included.
[k] Principles of Surgery (SURG-A).
[l] Tumors in the base of tongue, posterior pharyngeal wall, and soft palate require consideration of bilateral neck treatment as do tumors of the tonsil invading the tongue base.
[n] Principles of Radiation Therapy (ORPH-A).
[o] Principles of Systemic Therapy for Non-Nasopharyngeal Cancers (SYST-A).
[q] See Discussion on induction chemotherapy.
[r] Pathologic staging criteria differ from clinical staging criteria in HPV-mediated oropharyngeal cancer. For pathologic stage following resection, see AJCC 8th edition for appropriate staging criteria (ST-7).
[s] Adverse pathologic features: extranodal extension, positive margins, close margins (<3 mm), pT3 or pT4 primary, one positive node >3 cm or multiple positive nodes, nodal disease in levels IV or V, perineural invasion, vascular invasion, and lymphatic invasion (Discussion). The definition of an adverse pathologic feature in the context of HPV+ disease is an area of active research. This includes the presence and extent of extranodal extension, and the number of involved nodes.
[t] The recommendations for patients at high risk with extranodal extension + positive margins are based on randomized studies involving patients for whom the HPV status of their tumors was not specified.
[u] De-escalation to 50 Gy may be considered in patients with p16 (HPV)-positive oropharynx cancer who have ≤4 positive ipsilateral lymph nodes with the largest ≤6 cm, T1–T2 resected to negative or close margins (<3 mm) with ≤1 mm extranodal extension based on ECOG 3311 Intermediate Risk criteria (Ferris RL, et al. J Clin Oncol 2022;40:138-149) (category 2B).
[v] For those with clinical evidence of fixed or matted nodes or obvious extranodal extension, resection is not recommended and concurrent systemic therapy/RT is preferred.
[w] Surgical intervention may be an option for select patients with disease that does not respond to induction chemotherapy.

Note: All recommendations are category 2A unless otherwise indicated.

Version 1.2026, 12/08/2025 © 2025 National Comprehensive Cancer Network® (NCCN®), All rights reserved. NCCN Guidelines® and this illustration may not be reproduced in any form without the express written permission of NCCN.

PLEASE NOTE that use of this NCCN Content is governed by the End-User License Agreement, and you MAY NOT distribute this Content or use it with any artificial intelligence model or tool.
Printed by Galya Basol Kochav on 1/4/2026 9:40:35 AM. Copyright © 2026 National Comprehensive Cancer Network, Inc. All Rights Reserved.

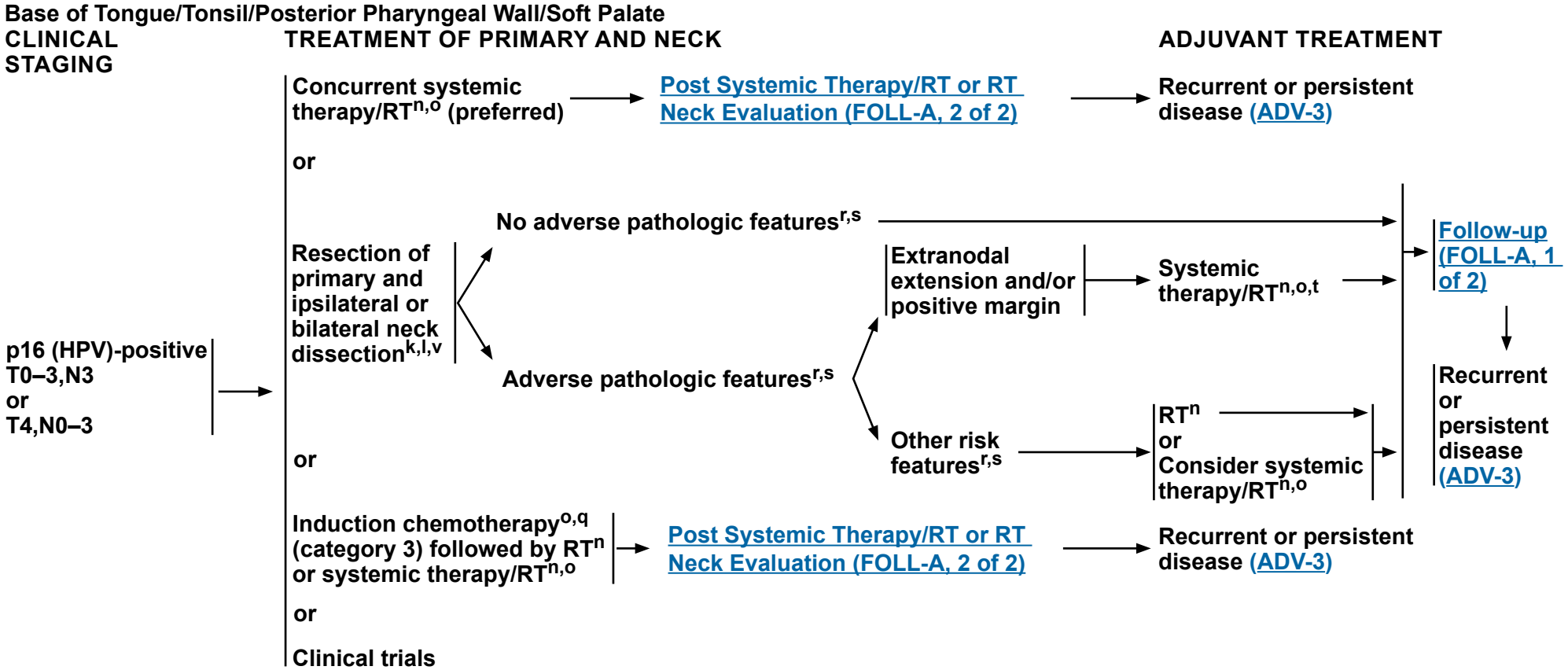

[k] Principles of Surgery (SURG-A).
[l] Tumors in the base of tongue, posterior pharyngeal wall, and soft palate require consideration of bilateral neck treatment as do tumors of the tonsil invading the tongue base.
[n] Principles of Radiation Therapy (ORPH-A).
[o] Principles of Systemic Therapy for Non-Nasopharyngeal Cancers (SYST-A).
[q] See Discussion on induction chemotherapy.
[r] Pathologic staging criteria differ from clinical staging criteria in HPV-mediated oropharyngeal cancer. For pathologic stage following resection, see AJCC 8th edition for appropriate staging criteria (ST-7).
[s] Adverse pathologic features: extranodal extension, positive margins, close margins (<3 mm), pT3 or pT4 primary, one positive node >3 cm or multiple positive nodes, nodal disease in levels IV or V, perineural invasion, vascular invasion, and lymphatic invasion (Discussion). The definition of an adverse pathologic feature in the context of HPV+ disease is an area of active research. This includes the presence and extent of extranodal extension, and the number of involved nodes.
[t] The recommendations for patients at high risk with extranodal extension + positive margins are based on randomized studies involving patients for whom the HPV status of their tumors was not specified.
[v] For those with clinical evidence of fixed or matted nodes or obvious extranodal extension, resection is not recommended and concurrent systemic therapy/RT is preferred.

Note: All recommendations are category 2A unless otherwise indicated.

Version 1.2026, 12/08/2025 © 2025 National Comprehensive Cancer Network® (NCCN®), All rights reserved. NCCN Guidelines® and this illustration may not be reproduced in any form without the express written permission of NCCN.

PLEASE NOTE that use of this NCCN Content is governed by the End-User License Agreement, and you MAY NOT distribute this Content or use it with any artificial intelligence model or tool.
Printed by Galya Basol Kochav on 1/4/2026 9:40:35 AM. Copyright © 2026 National Comprehensive Cancer Network, Inc. All Rights Reserved.

PRINCIPLES OF RADIATION THERAPY[a]

DEFINITIVE:

RT Alone

- **PTV**
  - **High risk: Primary tumor and involved lymph nodes (this includes possible local subclinical infiltration at the primary site and at the high-risk level lymph node[s])**
    - **Fractionation:**
      - **IMRT planning can consist of sequential IMRT (S-IMRT) or simultaneous integrated boost (SIB) techniques. Equivalent doses in 2 Gy (EQD2) can be used to determine appropriate fractionation schemes when using SIB techniques.**
      - **66 Gy (2.2 Gy/fraction) to 70 Gy (2.0 Gy/fraction)[1]; daily Monday–Friday in 6–7 weeks[b]**
      - **Concomitant boost accelerated RT:**
        - **72 Gy/6 weeks (1.8 Gy/fraction, large field; 1.5 Gy boost as second daily fraction during last 12 treatment days)**
        - **66–70 Gy (2.0 Gy/fraction; 6 fractions/wk accelerated)**
      - **Hyperfractionation for T2,N0–1 disease: 74.4–81.6 Gy/6–7 weeks (1.2 Gy/fraction, twice daily)**
      - **69.96 Gy (2.12 Gy/fraction) daily Monday–Friday in 6–7 weeks**
  - **Low to intermediate risk: Sites of suspected subclinical spread**
    - **44–50 Gy (2.0 Gy/fraction) used for S-IMRT or the use of an anterior neck field and to 54–63 Gy (1.6–1.8 Gy/fraction) when using SIB techniques[c]**
- **Treatment deintensification is an area of active research, with several published phase II studies demonstrating promising rates of progression-free survival with dose-reduced radiotherapy.[2]**

CONCURRENT SYSTEMIC THERAPY/RT[d,e]:

- **PTV**
  - **High risk: Typically 70 Gy (2.0 Gy/fraction)**
  - **Low to intermediate risk: 44–50 Gy (2.0 Gy/fraction) to 54–63 Gy (1.6–1.8 Gy/fraction)[c]**

IMRT (preferred) is recommended for cancers of the oropharynx in order to minimize dose to critical structures. Use of proton therapy is an area of active investigation. Proton therapy may be considered when normal tissue constraints cannot be met by photon-based therapy, or when photon-based therapy causes compromise of standard radiation dosing to tumor or postoperative volumes.

[a] See Principles of Radiation Techniques (RAD-A) and Discussion.
[b] For doses >70 Gy, some clinicians think that the fractionation should be slightly modified (eg, <2.0 Gy/fraction for at least some of the treatment) to minimize toxicity. An additional 2–3 doses can be added depending on clinical circumstances.
[c] Suggest 44–50 Gy in sequentially planned IMRT or 54–63 Gy with IMRT dose painting technique (dependent on dose per fraction).
[d] Principles of Systemic Therapy for Non-Nasopharyngeal Cancers (SYST-A).
[e] Based on published data, concurrent systemic therapy/RT most commonly uses conventional fractionation at 2.0 Gy per fraction to a typical dose of 70 Gy in 7 weeks with single-agent cisplatin given every 3 weeks at 100 mg/m^2; 2–3 cycles of chemotherapy are used depending on the radiation fractionation scheme (RTOG 0129) (Ang KK, et al. N Engl J Med 2010;363:24-35). When carboplatin and fluorouracil are used, the recommended regimen is standard fractionation plus 3 cycles of chemotherapy (Bourhis J, et al. Lancet Oncol 2012;13:145-153). Other fraction sizes (eg, 1.8 Gy, conventional), multiagent chemotherapy, other dosing schedules of cisplatin, or altered fractionation with chemotherapy are efficacious, and there is no consensus on the optimal approach. In general, the use of concurrent systemic therapy/RT carries a high toxicity burden; multiagent chemotherapy will likely further increase the toxicity burden. For any systemic therapy/RT approach, close attention should be paid to published reports for the specific chemotherapy agent, dose, and schedule of administration. Systemic therapy/RT should be performed by an experienced team and should include substantial supportive care. See Discussion.

[1] Eisbruch A, et al. Int J Radiat Oncol Biol Phys 2010;76:1333-1338.
[2] Yom SS, et al. J Clin Oncol 2021;39:956-965; Chera BS, et al. J Clin Oncol 2019;37:2661-2669.

Note: All recommendations are category 2A unless otherwise indicated.

Version 1.2026, 12/08/2025 © 2025 National Comprehensive Cancer Network® (NCCN®), All rights reserved. NCCN Guidelines® and this illustration may not be reproduced in any form without the express written permission of NCCN.

PLEASE NOTE that use of this NCCN Content is governed by the End-User License Agreement, and you MAY NOT distribute this Content or use it with any artificial intelligence model or tool.
Printed by Galya Basol Kochav on 1/4/2026 9:40:35 AM. Copyright © 2026 National Comprehensive Cancer Network, Inc. All Rights Reserved.

PRINCIPLES OF RADIATION THERAPY[a]

POSTOPERATIVE:

RT or Concurrent Systemic Therapy/RT[f,3-6]

- **Preferred interval between resection and initiation of postoperative RT is ≤6 weeks.**
- **PTV**
  - **High risk: Adverse pathologic features such as positive margins[g,h]**
    - **60–66 Gy (2.0 Gy/fraction); daily Monday–Friday in 6–6.5 weeks**
  - **Low to intermediate risk: Sites of suspected subclinical spread**
    - **44–50 Gy (2.0 Gy/fraction) to 54–63 Gy (1.6–1.8 Gy/fraction)[c]**
    - **De-escalation to 50 Gy may be considered in patients with p16 (HPV)-positive oropharynx cancer who have ≤4 positive lymph nodes, T1–T2 resected to negative or close margins (<3 mm), and/or N1–N2 disease (excluding bilateral disease based on ECOG 3311 criteria) with ≤1 mm extranodal extension (category 2B).[7]**

IMRT (preferred) is recommended for cancers of the oropharynx in order to minimize dose to critical structures. Use of proton therapy is an area of active investigation. Proton therapy may be considered when normal tissue constraints cannot be met by photon-based therapy, or when photon-based therapy causes compromise of standard radiation dosing to tumor or postoperative volumes.

[a] See Principles of Radiation Techniques (RAD-A) and Discussion.
[c] Suggest 44–50 Gy in sequentially planned IMRT or 54–63 Gy with IMRT dose painting technique (dependent on dose per fraction).
[f] Principles of Systemic Therapy for Non-Nasopharyngeal Cancers (SYST-A).
[g] Adverse pathologic features for p16(HPV)-negative disease: extranodal extension, positive margins, close margins, pT3 or pT4 primary, pN2 or pN3 nodal disease, nodal disease in levels IV or V, perineural invasion, vascular invasion, and lymphatic invasion (Discussion).
[h] Adverse pathologic features for p16 (HPV)-positive disease: extranodal extension, positive margins, close margins (<3 mm), pT3 or pT4 primary, one positive node >3 cm or multiple positive nodes, nodal disease in levels IV or V, perineural invasion, vascular invasion, and lymphatic invasion (Discussion). The definition of an adverse pathologic feature in the context of HPV+ disease is an area of active research. This includes the presence and extent of extranodal extension, and the number of involved nodes.

[3] Bernier J, et al. N Engl J Med 2004;350:1945-1952.
[4] Cooper JS, et al. N Engl J Med 2004;350:1937-1944.
[5] Bernier J, et al. Head Neck 2005;27:843-850.
[6] Cooper JS, et al. Int J Radiat Oncol Biol Phys 2012;84:1198-1205.
[7] Ferris RL, et al. J Clin Oncol 2022;40:138-149.

Note: All recommendations are category 2A unless otherwise indicated.

Version 1.2026, 12/08/2025 © 2025 National Comprehensive Cancer Network® (NCCN®), All rights reserved. NCCN Guidelines® and this illustration may not be reproduced in any form without the express written permission of NCCN.

PLEASE NOTE that use of this NCCN Content is governed by the End-User License Agreement, and you MAY NOT distribute this Content or use it with any artificial intelligence model or tool.
Printed by Galya Basol Kochav on 1/4/2026 9:40:35 AM. Copyright © 2026 National Comprehensive Cancer Network, Inc. All Rights Reserved.

PRINCIPLES OF P16 TESTING FOR HPV-MEDIATED OROPHARYNGEAL CANCER

- **P16 expression correlates with HPV status in geographic regions where HPV is etiologically responsible for a high proportion of cancers. Confirmatory HPV direct testing is recommended, especially for clinical trials. Clinical centers are recommended to ascertain concordance rate of p16 and direct HPV testing, as this may vary by region, if considering use of p16 IHC alone as a surrogate.**
- **Distinguishing patients with p16+ tumors by HPV tumor status informs prognosis. Patients with p16+ and HPV+ tumors have an improved prognosis compared to patients with p16+ and HPV-negative tumors.[1]**
- **Direct HPV confirmatory tests include polymerase chain reaction (PCR) and RNA in situ hybridization (ISH).**
- **PCR may provide additional sensitivity while ISH provides increased specificity.[2-5]**
- **Sufficient pathologic material for HPV testing can be obtained through FNA.[5,6]**
- **A small proportion of tumors at non-oropharyngeal sites (eg, paranasal sinus, oral cavity, larynx) are HPV-related. However, given the small proportion and lack of consistent evidence in support of prognostic significance, routine HPV testing or p16 testing of cancers outside of the oropharynx and sinonasal tract is not recommended.**
- **Guidelines for testing are available from the College of American Pathologists.[7]**
- **When using p16 testing, the 70% cutoff with nuclear and cytoplasmic expression with at least moderate to strong intensity is recommended.[7]**

[1] Mehanna H, Taberna M, von Buchwald C, et al. Prognostic implications of p16 and HPV discordance in oropharyngeal cancer (HNCIG-EPIC-OPC): A multicentre, multinational, individual patient data analysis. Lancet Oncol 2023;24:239-251.
[2] Cantley RL, Gabrielli E, Montebelli F, et al. Ancillary studies in determining human papillomavirus status of squamous cell carcinoma of the oropharynx: a review. Patholog Res Int 2011;2011:138469.
[3] Singhi AD, Westra WH. Comparison of human papillomavirus in situ hybridization and p16 immunohistochemistry in the detection of human papillomavirus-associated head and neck cancer based on a prospective clinical experience. Cancer 2010;116:2166-2173.
[4] Thavaraj S, Stokes A, Guerra E, et al. Evaluation of human papillomavirus testing for squamous cell carcinoma of the tonsil in clinical practice. J Clin Pathol 2011;64:308-312.
[5] Snow AN, Laudadio J. Human papillomavirus detection in head and neck squamous cell carcinomas. Adv Anat Pathol 2010;17:394-403.
[6] Begum S, Gillison ML, Nicol TL, Westra WH. Detection of human papillomavirus-16 in fine-needle aspirates to determine tumor origin in patients with metastatic squamous cell carcinoma of the head and neck. Clin Cancer Res 2007;13:1186-1191.
[7] Lewis JS Jr, Beadle B, Bishop JA, et al. Human papillomavirus testing in head and neck carcinomas: Guideline from the College of American Pathologists. Arch Pathol Lab Med 2025;149:e115-e150.

Note: All recommendations are category 2A unless otherwise indicated.

Version 1.2026, 12/08/2025 © 2025 National Comprehensive Cancer Network® (NCCN®), All rights reserved. NCCN Guidelines® and this illustration may not be reproduced in any form without the express written permission of NCCN.

PLEASE NOTE that use of this NCCN Content is governed by the End-User License Agreement, and you MAY NOT distribute this Content or use it with any artificial intelligence model or tool.
Printed by Galya Basol Kochav on 1/4/2026 9:40:35 AM. Copyright © 2026 National Comprehensive Cancer Network, Inc. All Rights Reserved.

WORKUP

- H&P[a,b] including a complete head and neck exam; mirror and/or fiberoptic examination as clinically indicated
- Biopsy of primary site or FNA of neck[c]
- CT with contrast and/or MRI with and without contrast of primary and neck[d]
- EUA with endoscopy
- As clinically indicated:
  - Chest CT (with or without contrast)[d]
  - Consider FDG-PET/CT[d]
  - Preanesthesia studies
  - Consider pulmonary function tests (PFTs) for conservation surgery candidates
  - Screening for hepatitis B
  - PD-L1 testing by IHC (CPS)
- Dental/prosthodontic evaluation[e]
  - Nutrition, speech, and swallowing evaluation/therapy, and audiogram[f]
  - Smoking cessation counseling[a]
  - Fertility/reproductive counseling[g]
- Multidisciplinary consultation as clinically indicated

CLINICAL STAGING

- Amenable to larynx-preserving (conservation) surgery (most T1,N0, and selected T2,N0) → Treatment of Primary and Neck (HYPO-2)
- Advanced cancer requiring (amenable to) pharyngectomy with total laryngectomy
  - T1–3,N0–3 → Treatment of Primary and Neck (HYPO-3)
  - T4a,N0–3 → Treatment of Primary and Neck (HYPO-5)
- T4b,N0–3 or Unresectable nodal disease or Unfit for surgery → Treatment of Very Advanced Head and Neck Cancer (ADV-1)
- Metastatic (M1) disease at initial presentation → Treatment of Very Advanced Head and Neck Cancer (ADV-2)

[a] H&P should include documentation and quantification (pack years smoked) of tobacco use history, as well as alcohol use and counseling. All patients who currently smoke should be advised to quit smoking, and those who formerly smoked should be advised to remain abstinent from smoking. For additional cessation support, refer to the Smoking Cessation and Treatment Resources in the NCCN Guidelines for Smoking Cessation.

[b] Screen for distress. Refer to the NCCN Distress Thermometer and Problem List, which includes social determinants of health. See NCCN Guidelines for Distress Management (DIS-A).

[c] Image-guided (US or CT) needle biopsy of cystic neck nodes may offer better diagnostic yield than FNA by palpation alone for initial diagnosis in this setting. For unresectable or metastatic disease where there is a plan for systemic therapy, a core biopsy would allow for biomarker testing.

[d] Principles of Imaging (IMG-A).

[e] Principles of Oral/Dental Evaluation and Management (DENT-A).

[f] Principles of Nutrition: Management and Supportive Care (NUTR-A).

[g] See fertility and reproductive endocrine considerations in the NCCN Guidelines for Adolescent and Young Adult (AYA) Oncology.

Note: All recommendations are category 2A unless otherwise indicated.

Version 1.2026, 12/08/2025 © 2025 National Comprehensive Cancer Network® (NCCN®), All rights reserved. NCCN Guidelines® and this illustration may not be reproduced in any form without the express written permission of NCCN.

PLEASE NOTE that use of this NCCN Content is governed by the End-User License Agreement, and you MAY NOT distribute this Content or use it with any artificial intelligence model or tool.
Printed by Galya Basol Kochav on 1/4/2026 9:40:35 AM. Copyright © 2026 National Comprehensive Cancer Network, Inc. All Rights Reserved.

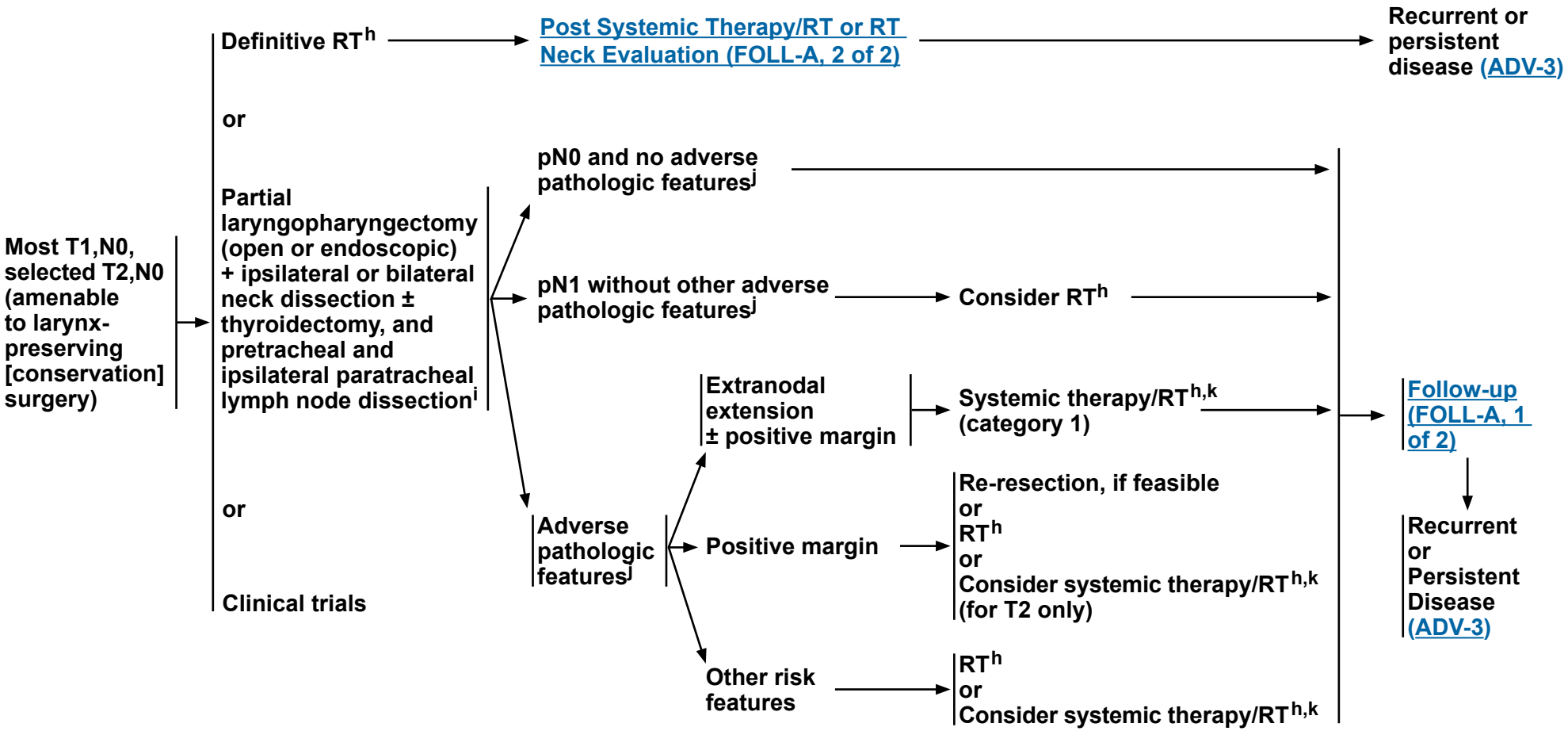

[h] Principles of Radiation Therapy (HYPO-A).
[i] Principles of Surgery (SURG-A).
[j] Adverse pathologic features: extranodal extension, positive margins, close margins, pT3 or pT4 primary, pN2 or pN3 nodal disease, perineural invasion, vascular invasion, and lymphatic invasion (Discussion).
[k] Principles of Systemic Therapy for Non-Nasopharyngeal Cancers (SYST-A).

Note: All recommendations are category 2A unless otherwise indicated.

Version 1.2026, 12/08/2025 © 2025 National Comprehensive Cancer Network® (NCCN®), All rights reserved. NCCN Guidelines® and this illustration may not be reproduced in any form without the express written permission of NCCN.

PLEASE NOTE that use of this NCCN Content is governed by the End-User License Agreement, and you MAY NOT distribute this Content or use it with any artificial intelligence model or tool.
Printed by Galya Basol Kochav on 1/4/2026 9:40:35 AM. Copyright © 2026 National Comprehensive Cancer Network, Inc. All Rights Reserved.

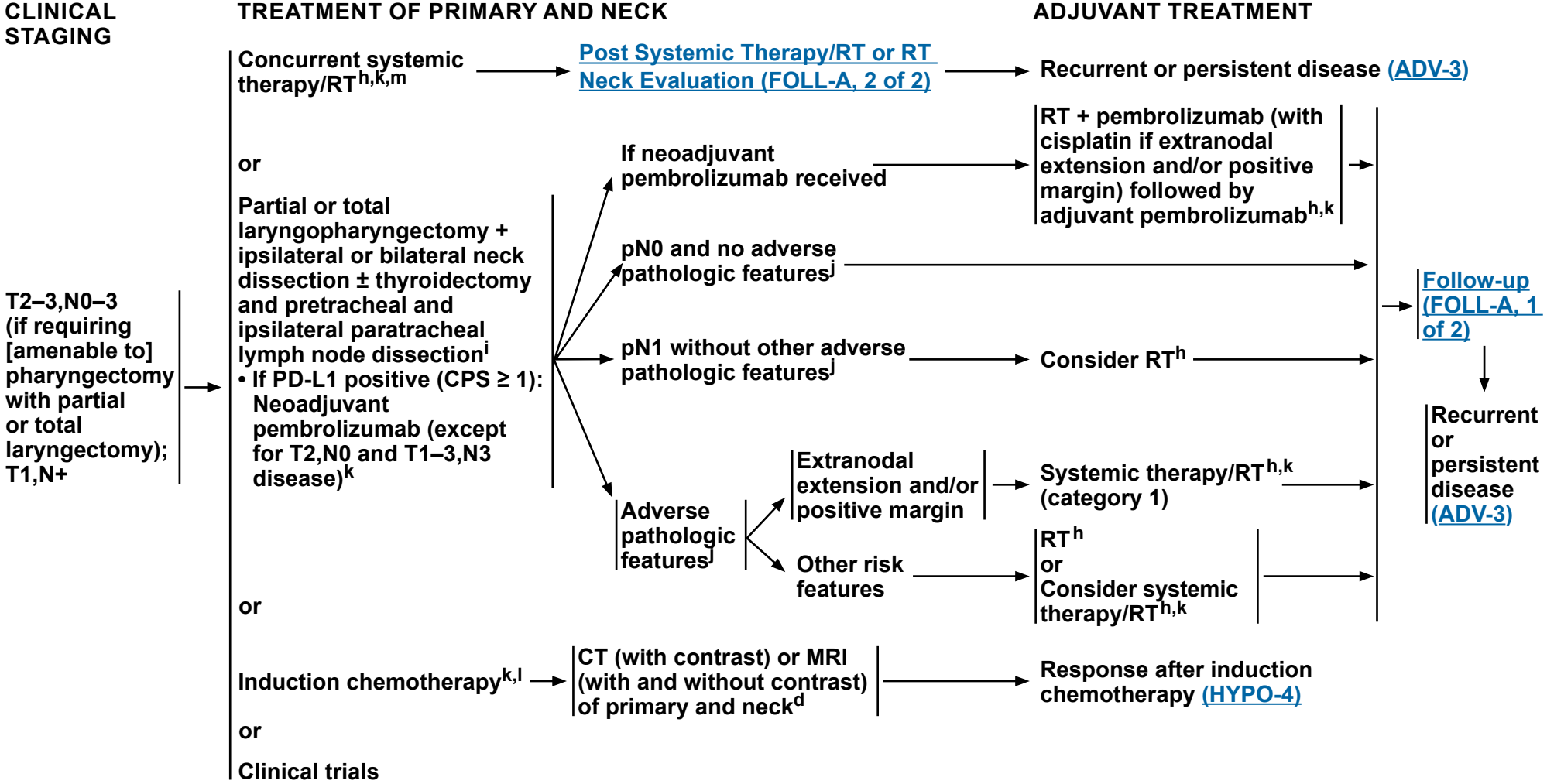

[d] Principles of Imaging (IMG-A).
[h] Principles of Radiation Therapy (HYPO-A).
[i] Principles of Surgery (SURG-A).
[j] Adverse pathologic features: extranodal extension, positive margins, close margins, pT3 or pT4 primary, pN2 or pN3 nodal disease, perineural invasion, vascular invasion, and lymphatic invasion (Discussion).
[k] Principles of Systemic Therapy for Non-Nasopharyngeal Cancers (SYST-A).
[l] In randomized clinical trials, assessment of response has been done after 2 or 3 cycles.
[m] When using concurrent systemic therapy/RT, the preferred agent is cisplatin (category 1). See Principles of Systemic Therapy for Non-Nasopharyngeal Cancers (SYST-A).

Note: All recommendations are category 2A unless otherwise indicated.

Version 1.2026, 12/08/2025 © 2025 National Comprehensive Cancer Network® (NCCN®), All rights reserved. NCCN Guidelines® and this illustration may not be reproduced in any form without the express written permission of NCCN.

PLEASE NOTE that use of this NCCN Content is governed by the End-User License Agreement, and you MAY NOT distribute this Content or use it with any artificial intelligence model or tool.
Printed by Galya Basol Kochav on 1/4/2026 9:40:35 AM. Copyright © 2026 National Comprehensive Cancer Network, Inc. All Rights Reserved.

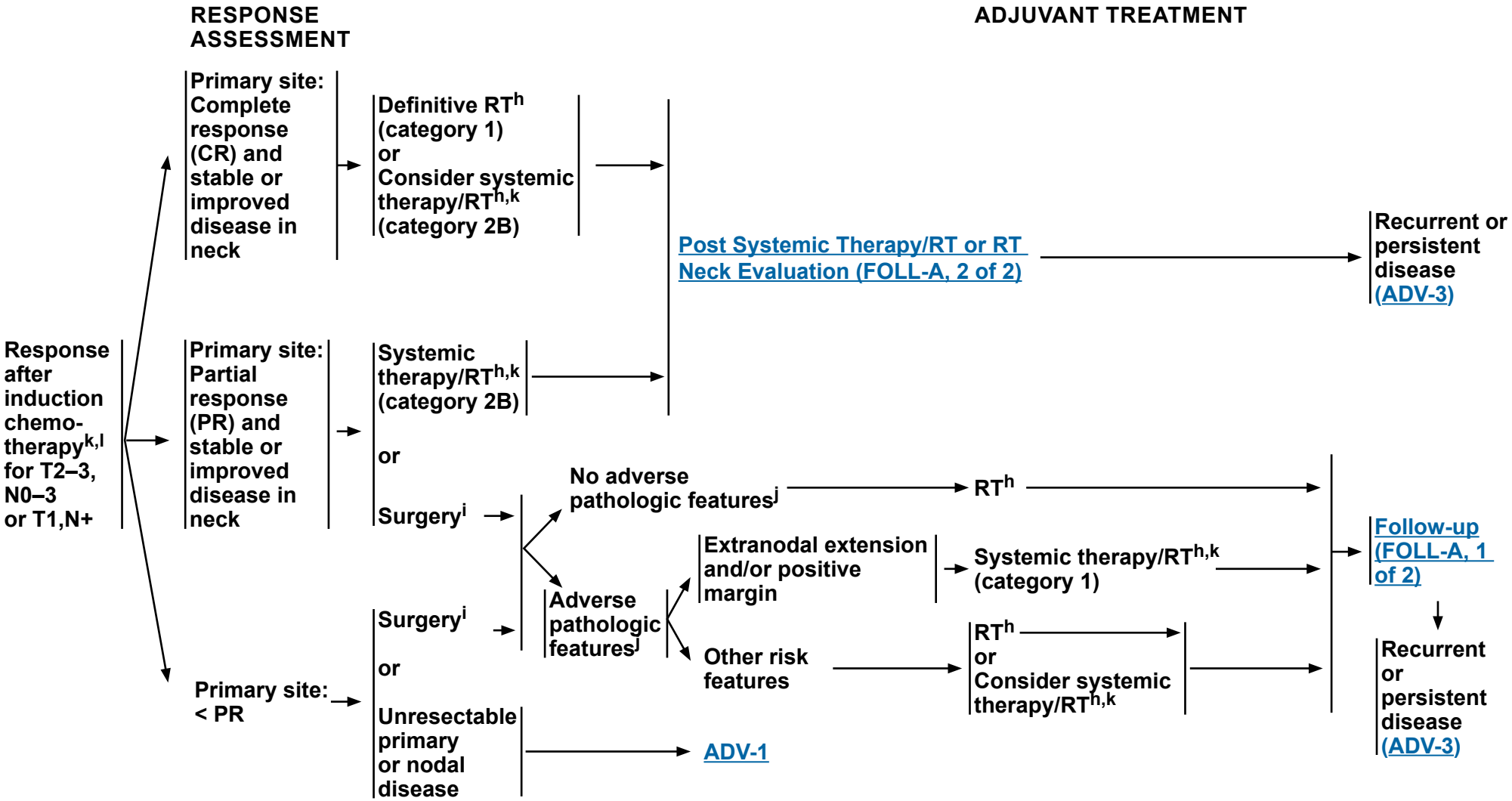

[h] Principles of Radiation Therapy (HYPO-A).
[i] Principles of Surgery (SURG-A).
[j] Adverse pathologic features: extranodal extension, positive margins, close margins, pT3 or pT4 primary, pN2 or pN3 nodal disease, perineural invasion, vascular invasion, and lymphatic invasion (Discussion).
[k] Principles of Systemic Therapy for Non-Nasopharyngeal Cancers (SYST-A).
[l] In randomized clinical trials, assessment of response has been done after 2 or 3 cycles.

Note: All recommendations are category 2A unless otherwise indicated.

Version 1.2026, 12/08/2025 © 2025 National Comprehensive Cancer Network® (NCCN®), All rights reserved. NCCN Guidelines® and this illustration may not be reproduced in any form without the express written permission of NCCN.

PLEASE NOTE that use of this NCCN Content is governed by the End-User License Agreement, and you MAY NOT distribute this Content or use it with any artificial intelligence model or tool.
Printed by Galya Basol Kochav on 1/4/2026 9:40:35 AM. Copyright © 2026 National Comprehensive Cancer Network, Inc. All Rights Reserved.

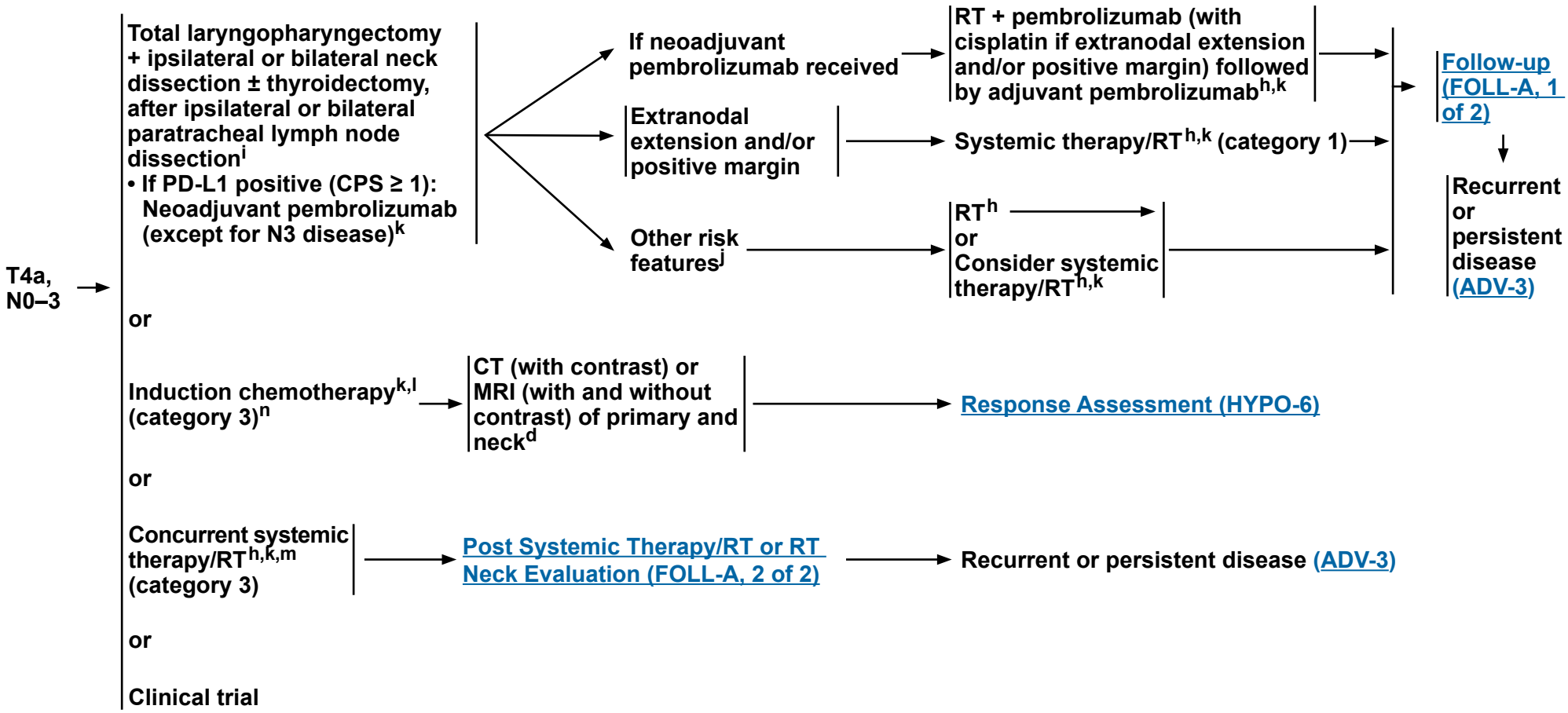

[d] Principles of Imaging (IMG-A).
[h] Principles of Radiation Therapy (HYPO-A).
[i] Principles of Surgery (SURG-A).
[j] Adverse pathologic features: extranodal extension, positive margins, close margins, pT3 or pT4 primary, pN2 or pN3 nodal disease, perineural invasion, vascular invasion, and lymphatic invasion (Discussion).
[k] Principles of Systemic Therapy for Non-Nasopharyngeal Cancers (SYST-A).
[l] In randomized clinical trials, assessment of response has been done after 2 or 3 cycles.
[m] When using concurrent systemic therapy/RT, the preferred agent is cisplatin (category 1). See Principles of Systemic Therapy for Non-Nasopharyngeal Cancers (SYST-A).
[n] See Discussion on induction chemotherapy.

Note: All recommendations are category 2A unless otherwise indicated.

Version 1.2026, 12/08/2025 © 2025 National Comprehensive Cancer Network® (NCCN®), All rights reserved. NCCN Guidelines® and this illustration may not be reproduced in any form without the express written permission of NCCN.

PLEASE NOTE that use of this NCCN Content is governed by the End-User License Agreement, and you MAY NOT distribute this Content or use it with any artificial intelligence model or tool.
Printed by Galya Basol Kochav on 1/4/2026 9:40:35 AM. Copyright © 2026 National Comprehensive Cancer Network, Inc. All Rights Reserved.

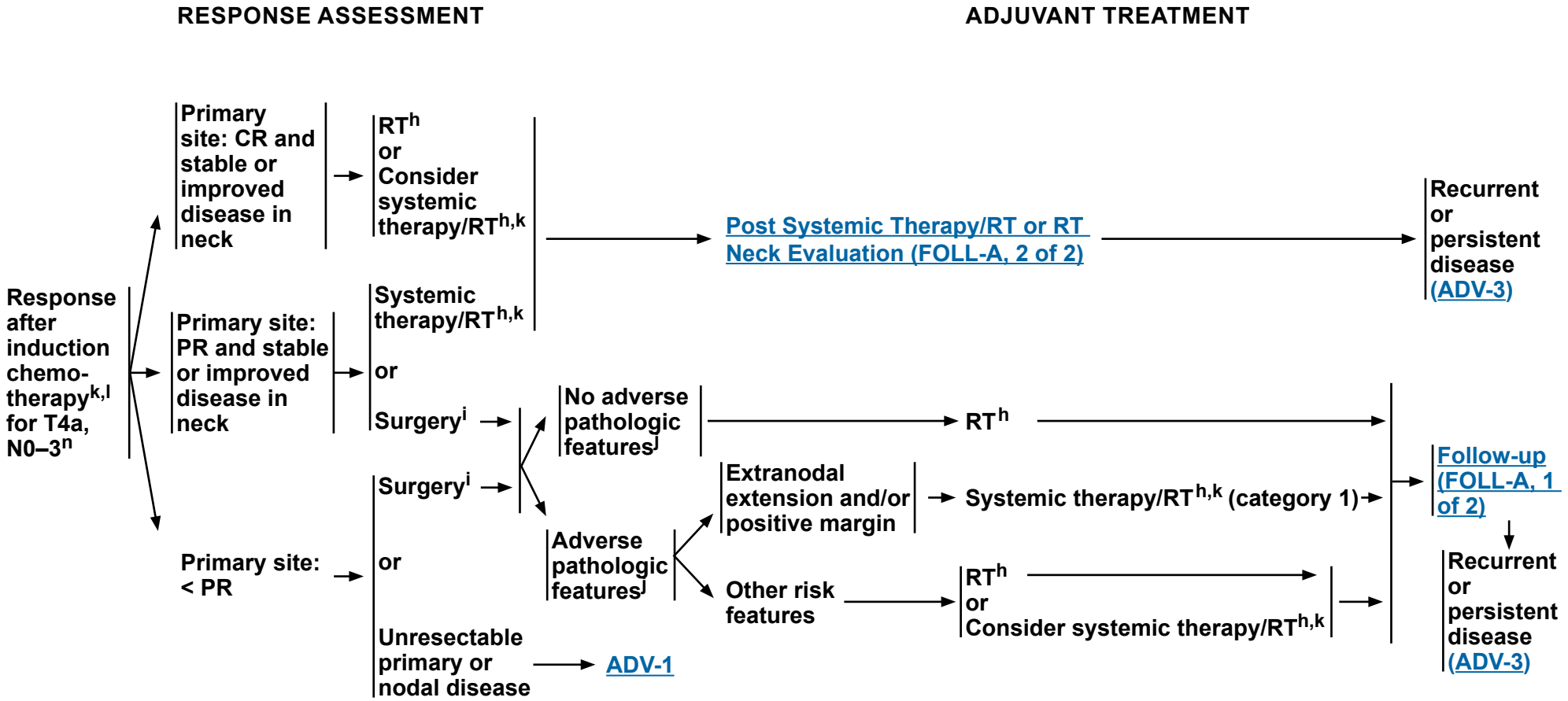

[h] Principles of Radiation Therapy (HYPO-A).
[i] Principles of Surgery (SURG-A).
[j] Adverse pathologic features: extranodal extension, positive margins, close margins, pT3 or pT4 primary, pN2 or pN3 nodal disease, perineural invasion, vascular invasion, and lymphatic invasion (Discussion).
[k] Principles of Systemic Therapy for Non-Nasopharyngeal Cancers (SYST-A).
[l] In randomized clinical trials, assessment of response has been done after 2 or 3 cycles.
[n] See Discussion on induction chemotherapy.

Note: All recommendations are category 2A unless otherwise indicated.

Version 1.2026, 12/08/2025 © 2025 National Comprehensive Cancer Network® (NCCN®), All rights reserved. NCCN Guidelines® and this illustration may not be reproduced in any form without the express written permission of NCCN.

PLEASE NOTE that use of this NCCN Content is governed by the End-User License Agreement, and you MAY NOT distribute this Content or use it with any artificial intelligence model or tool.
Printed by Galya Basol Kochav on 1/4/2026 9:40:35 AM. Copyright © 2026 National Comprehensive Cancer Network, Inc. All Rights Reserved.

PRINCIPLES OF RADIATION THERAPY[a,b]

DEFINITIVE:

RT Alone

- **PTV**
  - **High risk: Primary tumor and involved lymph nodes (this includes possible local subclinical infiltration at the primary site and at the high-risk level lymph node[s])**
    - **Fractionation:**
      - **66 Gy (2.2 Gy/fraction) to 70 Gy (2.0 Gy/fraction); daily Monday–Friday in 6–7 weeks[c,1]**
      - **69.96 Gy (2.12 Gy/fraction) daily Monday–Friday in 6–7 weeks**
      - **Concomitant boost accelerated RT:**
        - **72 Gy/6 weeks (1.8 Gy/fraction, large field; 1.5 Gy boost as second daily fraction during last 12 treatment days)**
        - **66–70 Gy (2.0 Gy/fraction; 6 fractions/wk accelerated)**
      - **Hyperfractionation: 81.6 Gy/7 weeks (1.2 Gy/fraction, twice daily)**
  - **Low to intermediate risk: Sites of suspected subclinical spread**
    - **44–50 Gy (2.0 Gy/fraction) to 54–63 Gy (1.6–1.8 Gy/fraction)[d]**

CONCURRENT SYSTEMIC THERAPY/RT[e,f]:

- **PTV**
  - **High risk: Typically 70 Gy (2.0 Gy/fraction)**
  - **Low to intermediate risk: 44–50 Gy (2.0 Gy/fraction) to 54–63 Gy (1.6–1.8 Gy/fraction)[d]**

IMRT (preferred) is recommended.

[1] Eisbruch A, Harris J, Garden AS, et al. Multi-institutional trial of accelerated hypofractionated intensity-modulated radiation therapy for early-stage oropharyngeal cancer (RTOG 00-22). Int J Radiat Oncol Biol Phys 2010;76:1333-1338.

[a] See Principles of Radiation Techniques (RAD-A) and Discussion.
[b] Particular attention to speech and swallowing is needed during therapy.
[c] For doses >70 Gy, some clinicians think that the fractionation should be slightly modified (eg, <2.0 Gy/fraction for at least some of the treatment) to minimize toxicity. An additional 2–3 doses can be added depending on clinical circumstances.
[d] Suggest 44–50 Gy in sequentially planned IMRT or 54–63 Gy with IMRT dose painting technique (dependent on dose per fraction).
[e] Principles of Systemic Therapy for Non-Nasopharyngeal Cancers (SYST-A).
[f] Based on published data, concurrent systemic therapy/RT most commonly uses conventional fractionation at 2.0 Gy per fraction to a typical dose of 70 Gy in 7 weeks with single-agent cisplatin given every 3 weeks at 100 mg/m^2; 2–3 cycles of chemotherapy are used depending on the radiation fractionation scheme (RTOG 0129) (Ang KK, Harris J, Wheeler R, et al. Human papillomavirus and survival of patients with oropharyngeal cancer. N Engl J Med 2010;363:24-35). When carboplatin and fluorouracil are used, the recommended regimen is standard fractionation plus 3 cycles of chemotherapy [Bourhis J, Sire C, Graff P, et al. Concomitant chemoradiotherapy versus acceleration of radiotherapy with or without concomitant chemotherapy in locally advanced head and neck carcinoma (GORTEC 99-02): an open-label phase 3 randomised trial. Lancet Oncol 2012;13:145-153]. Other fraction sizes (eg, 1.8 Gy, conventional), multiagent chemotherapy, other dosing schedules of cisplatin, or altered fractionation with chemotherapy are efficacious, and there is no consensus on the optimal approach. In general, the use of concurrent systemic therapy/RT carries a high toxicity burden; multiagent chemotherapy will likely further increase the toxicity burden. For any systemic therapy/RT approach, close attention should be paid to published reports for the specific chemotherapy agent, dose, and schedule of administration. Systemic therapy/RT should be performed by an experienced team and should include substantial supportive care.

Note: All recommendations are category 2A unless otherwise indicated.

Version 1.2026, 12/08/2025 © 2025 National Comprehensive Cancer Network® (NCCN®), All rights reserved. NCCN Guidelines® and this illustration may not be reproduced in any form without the express written permission of NCCN.

PLEASE NOTE that use of this NCCN Content is governed by the End-User License Agreement, and you MAY NOT distribute this Content or use it with any artificial intelligence model or tool.
Printed by Galya Basol Kochav on 1/4/2026 9:40:35 AM. Copyright © 2026 National Comprehensive Cancer Network, Inc. All Rights Reserved.

PRINCIPLES OF RADIATION THERAPY[a,b]

POSTOPERATIVE:

RT or Concurrent Systemic Therapy/RT[e,2-5]

- **Preferred interval between resection and initiation of postoperative RT is ≤6 weeks.**
- **PTV**
  - **High risk: Adverse pathologic features such as positive margins (see footnote j on HYPO-3)**
    - **60–66 Gy (2.0 Gy/fraction; daily Monday–Friday) in 6–6.5 weeks**
  - **Low to intermediate risk: Sites of suspected subclinical spread**
    - **44–50 Gy (2.0 Gy/fraction) to 54–63 Gy (1.6–1.8 Gy/fraction)[d]**

IMRT (preferred) is recommended.

[a] See Principles of Radiation Techniques (RAD-A) and Discussion.
[b] Particular attention to speech and swallowing is needed during therapy.
[d] Suggest 44–50 Gy in sequentially planned IMRT or 54–63 Gy with IMRT dose painting technique (dependent on dose per fraction).
[e] Principles of Systemic Therapy for Non-Nasopharyngeal Cancers (SYST-A).

[2] Bernier J, Domenge C, Ozsahin M, et al. Postoperative irradiation with or without concomitant chemotherapy for locally advanced head and neck cancer. N Engl J Med 2004;350:1945-1952.
[3] Cooper JS, Pajak TF, Forastiere AA, et al. Postoperative concurrent radiotherapy and chemotherapy for high-risk squamous-cell carcinoma of the head and neck. N Engl J Med 2004;350:1937-1944.
[4] Bernier J, Cooper JS, Pajak TF, et al. Defining risk levels in locally advanced head and neck cancers: A comparative analysis of concurrent postoperative radiation plus chemotherapy trials of the EORTC (#22931) and RTOG (#9501). Head Neck 2005;27:843-850.
[5] Cooper JS, Zhang Q, Pajak TF, et al. Long-term follow-up of the RTOG 9501/intergroup phase III trial: postoperative concurrent radiation therapy and chemotherapy in high-risk squamous cell carcinoma of the head and neck. Int J Radiat Oncol Biol Phys 2012;84:1198-1205.

Note: All recommendations are category 2A unless otherwise indicated.

Version 1.2026, 12/08/2025 © 2025 National Comprehensive Cancer Network® (NCCN®), All rights reserved. NCCN Guidelines® and this illustration may not be reproduced in any form without the express written permission of NCCN.

PLEASE NOTE that use of this NCCN Content is governed by the End-User License Agreement, and you MAY NOT distribute this Content or use it with any artificial intelligence model or tool.
Printed by Galya Basol Kochav on 1/4/2026 9:40:35 AM. Copyright © 2026 National Comprehensive Cancer Network, Inc. All Rights Reserved.

WORKUP

- **H&P[a,b] including a complete head and neck exam; mirror examination as clinically indicated**
- **Nasopharyngeal fiberoptic examination**
- **Biopsy of primary site or FNA of the neck[c]**
- **MRI with and without contrast of skull base to clavicle ± CT of skull base/neck with contrast to evaluate skull base erosion**
- **Imaging for distant metastases with FDG-PET/CT and/or chest CT with contrast; bone scan if PET/CT not done [d]**
- **Epstein-Barr virus (EBV)/DNA testing[e]**
- **Consider HPV testing (may inform etiology)**
- **As clinically indicated:**
  - **Dental/prosthodontic evaluation[f]**
  - **Nutrition, speech, and swallowing evaluations/therapy[g]**
  - **Audiogram**
  - **Consider ophthalmologic and endocrine evaluation**
  - **Smoking cessation counseling[a]**
  - **Fertility/reproductive counseling[h]**
  - **Screening for hepatitis B**
- **Multidisciplinary consultation as clinically indicated**

CLINICAL STAGING

M0 → **NASO-2**

M1 → **NASO-3**

[a] H&P should include documentation and quantification (pack years smoked) of tobacco use history, as well as alcohol use and counseling. All patients who currently smoke should be advised to quit smoking, and those who formerly smoked should be advised to remain abstinent from smoking. For additional cessation support, refer to the Smoking Cessation and Treatment Resources in the NCCN Guidelines for Smoking Cessation.

[b] Screen for distress. Refer to the NCCN Distress Thermometer and Problem List, which includes social determinants of health. See NCCN Guidelines for Distress Management (DIS-A).

[c] Image-guided (US or CT) needle biopsy of cystic neck nodes may offer better diagnostic yield than FNA by palpation alone for initial diagnosis in this setting. For unresectable or metastatic disease where there is a plan for systemic therapy, a core biopsy would allow for biomarker testing.

[d] Principles of Imaging (IMG-A).

[e] For nonkeratinizing or undifferentiated histology, consider testing for EBV in tumor tissue and blood. Common means for detecting EBV in pathologic specimens include ISH for EBV-encoded RNA (EBER) or IHC staining for latent membrane protein (LMP). The EBV DNA load within the serum or plasma may be quantified using PCR targeting genomic sequences of the EBV DNA such as BamHI-W, Epstein-Barr virus nuclear antigen (EBNA), or LMP; these tests vary in their sensitivity. The EBV DNA load may reflect prognosis and change in response to therapy.

[f] Principles of Oral/Dental Evaluation and Management (DENT-A).

[g] Principles of Nutrition: Management and Supportive Care (NUTR-A).

[h] See fertility and reproductive endocrine considerations in the NCCN Guidelines for Adolescent and Young Adult (AYA) Oncology.

Note: All recommendations are category 2A unless otherwise indicated.

Version 1.2026, 12/08/2025 © 2025 National Comprehensive Cancer Network® (NCCN®), All rights reserved. NCCN Guidelines® and this illustration may not be reproduced in any form without the express written permission of NCCN.

PLEASE NOTE that use of this NCCN Content is governed by the End-User License Agreement, and you MAY NOT distribute this Content or use it with any artificial intelligence model or tool.
Printed by Galya Basol Kochav on 1/4/2026 9:40:35 AM. Copyright © 2026 National Comprehensive Cancer Network, Inc. All Rights Reserved.

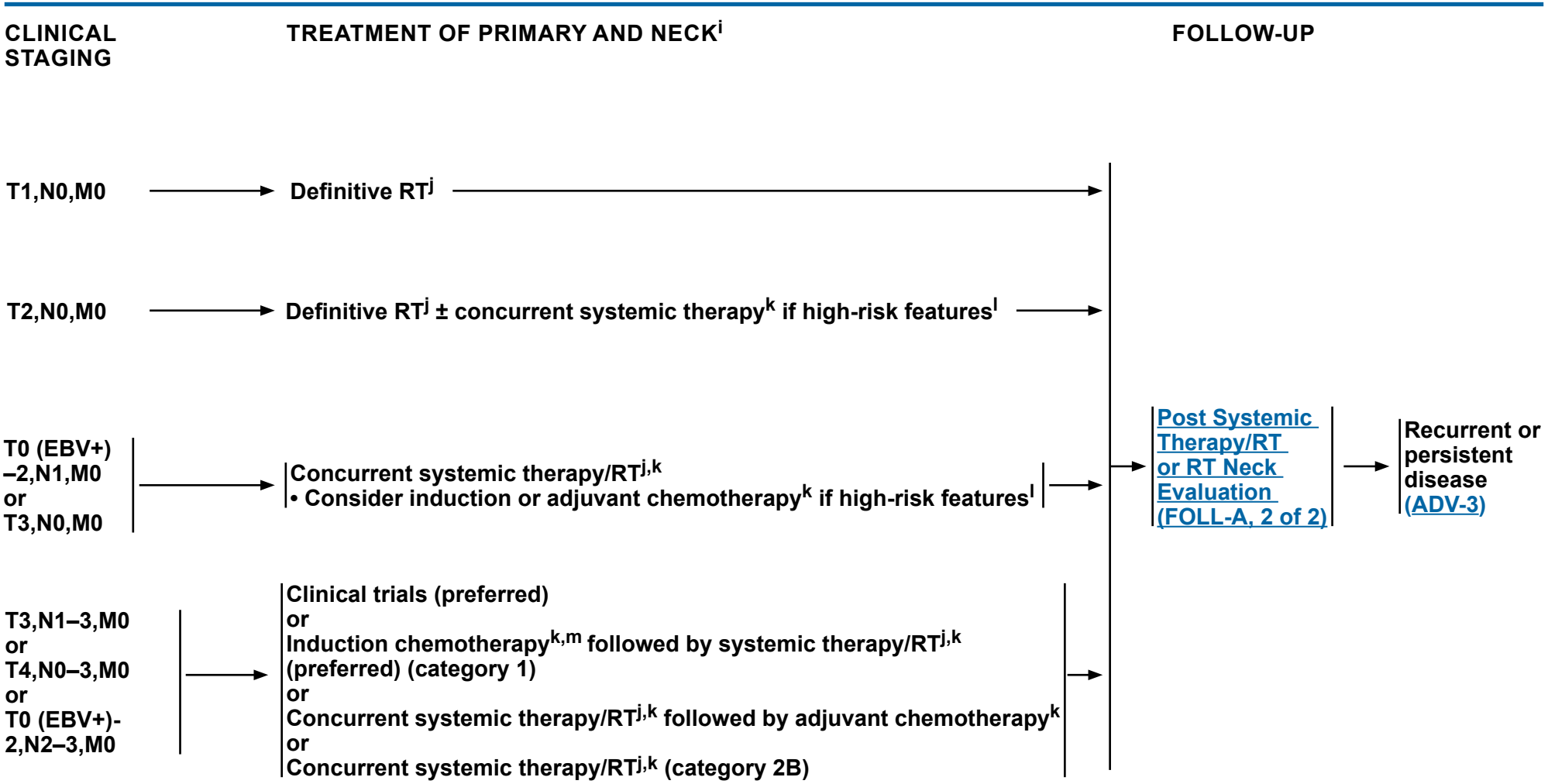

[i] The recommendations are based on clinical trial data for those with EBV-associated nasopharynx cancer (Discussion).
[j] Principles of Radiation Therapy (NASO-A).
[k] Systemic Therapy for Nasopharyngeal Cancers (NASO-B).
[l] High-risk features include bulky tumor volume and high serum EBV DNA copy number.
[m] See Discussion on induction chemotherapy.

Note: All recommendations are category 2A unless otherwise indicated.

Version 1.2026, 12/08/2025 © 2025 National Comprehensive Cancer Network® (NCCN®), All rights reserved. NCCN Guidelines® and this illustration may not be reproduced in any form without the express written permission of NCCN.

PLEASE NOTE that use of this NCCN Content is governed by the End-User License Agreement, and you MAY NOT distribute this Content or use it with any artificial intelligence model or tool.
Printed by Galya Basol Kochav on 1/4/2026 9:40:35 AM. Copyright © 2026 National Comprehensive Cancer Network, Inc. All Rights Reserved.

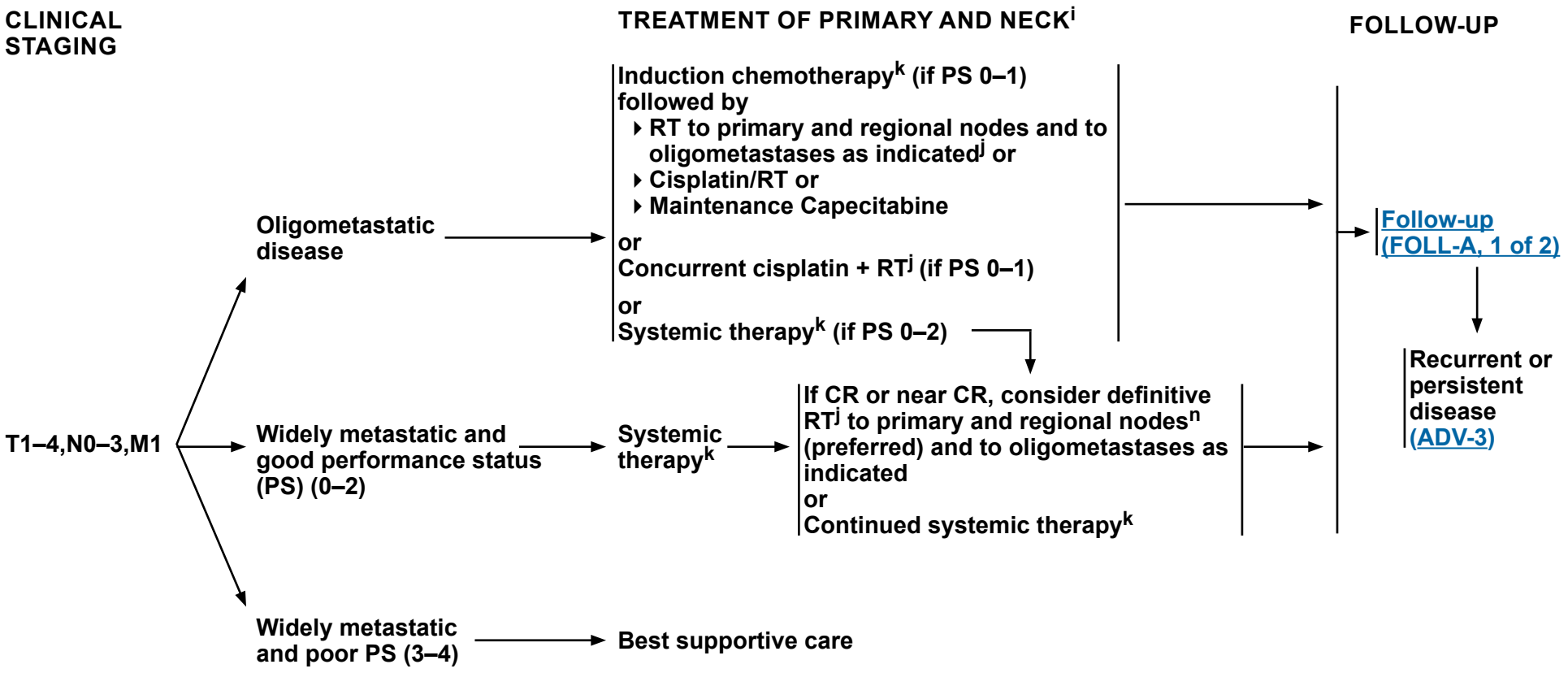

[i] The recommendations are based on clinical trial data for those with EBV-associated nasopharynx cancer (Discussion).

[j] Principles of Radiation Therapy (NASO-A).
[k] Systemic Therapy for Nasopharyngeal Cancers (NASO-B).
[n] You R, et al. JAMA Oncol 2020;6:1345-1352.

Note: All recommendations are category 2A unless otherwise indicated.

Version 1.2026, 12/08/2025 © 2025 National Comprehensive Cancer Network® (NCCN®), All rights reserved. NCCN Guidelines® and this illustration may not be reproduced in any form without the express written permission of NCCN.

PLEASE NOTE that use of this NCCN Content is governed by the End-User License Agreement, and you MAY NOT distribute this Content or use it with any artificial intelligence model or tool.
Printed by Galya Basol Kochav on 1/4/2026 9:40:35 AM. Copyright © 2026 National Comprehensive Cancer Network, Inc. All Rights Reserved.

PRINCIPLES OF RADIATION THERAPY[a]

DEFINITIVE:
RT Alone (for T1,N0 or patients who are not eligible to receive chemotherapy)
- **PTV**
  - **High risk: Primary tumor and involved lymph nodes (this includes possible local subclinical infiltration at the primary site and at the high-risk level lymph node[s])**
    - **70–70.2 Gy (1.8–2.0 Gy/fraction); daily Monday–Friday in 7–8 weeks[b,c]**
    - **69.96 Gy (2.12 Gy/fraction) daily Monday–Friday in 6–7 weeks[1]**
  - **Low to intermediate risk: Sites of suspected subclinical spread**
    - **44–50 Gy (2.0 Gy/fraction) to 54–63 Gy (1.6–1.8 Gy/fraction)[d]**
  - **For T1,N0,M0 disease, neck targets for elective RT to the neck include levels 7A/B, II, III, and VA.**

CONCURRENT SYSTEMIC THERAPY/RT[e]:
(preferred for patients eligible for chemotherapy)
- **PTV**
  - **High risk: Typically 70–70.2 Gy (1.8–2.0 Gy/fraction); daily Monday–Friday in 7–8 weeks[b]**
  - **Low to intermediate risk: 44–50 Gy (2.0 Gy/fraction) to 54–63 Gy (1.6–1.8 Gy/fraction)[d]**

Hyperfractionation for locally advanced nasopharyngeal carcinoma: See RAD-A for irradiation dosing schedule.

IMRT is recommended for cancers of the nasopharynx to minimize dose to critical structures. Proton therapy can be considered when normal tissue constraints cannot be met by photon-based therapy, or when photon-based therapy causes compromise of standard radiation dosing to tumor or postoperative volumes.

[a] See Principles of Radiation Techniques (RAD-A) and Discussion.
[b] Care should be taken to avoid critical neural structures; therefore, 1.8 Gy/fraction can be considered.
[c] For doses >70 Gy, some clinicians think that the fractionation should be slightly modified (eg, <2.0 Gy/fraction for at least some of the treatment) to minimize toxicity. An additional 2–3 doses can be added depending on clinical circumstances.
[d] Suggest 44–50 Gy in sequentially planned IMRT or 54–63 Gy with IMRT dose painting technique (dependent on dose per fraction).
[e] Systemic Therapy for Nasopharyngeal Cancers (NASO-B).

[1] Lee NY, Zhang Q, Pfister DG, et al. Addition of bevacizumab to standard systemic therapy/RT for locoregionally advanced nasopharyngeal carcinoma (RTOG 0615): a phase 2 multi-institutional trial. Lancet Oncol 2012;13:172-180.

Note: All recommendations are category 2A unless otherwise indicated.

Version 1.2026, 12/08/2025 © 2025 National Comprehensive Cancer Network® (NCCN®), All rights reserved. NCCN Guidelines® and this illustration may not be reproduced in any form without the express written permission of NCCN.

PLEASE NOTE that use of this NCCN Content is governed by the End-User License Agreement, and you MAY NOT distribute this Content or use it with any artificial intelligence model or tool.
Printed by Galya Basol Kochav on 1/4/2026 9:40:35 AM. Copyright © 2026 National Comprehensive Cancer Network, Inc. All Rights Reserved.

SYSTEMIC THERAPY FOR NASOPHARYNGEAL CANCERS[a,b]

- **The choice of systemic therapy should be individualized based on patient characteristics and goals of therapy.**
- **Use multigene panel testing (MGPT) and other appropriate biomarker testing to test for at least PD-L1 expression, tumor mutational burden (TMB), and mismatch repair (MMR) prior to treatment. (category 2B)**
- **Nivolumab and hyaluronidase-nvhy subcutaneous injection may be substituted for IV nivolumab. Nivolumab and hyaluronidase-nvhy has different dosing and administration instructions compared to IV nivolumab.**
- **Pembrolizumab and berahyaluronidase alfa-pmph subcutaneous injection may be substituted for IV pembrolizumab. Pembrolizumab and berahyaluronidase alfa-pmph has different dosing and administration instructions compared to IV pembrolizumab.**

Induction[c]/Sequential Systemic Therapy

Preferred
- Cisplatin/Gemcitabine (category 1 for EBV-associated disease, category 2A for non–EBV-associated disease)[1]
- Dose-Adjusted Cisplatin/Docetaxel/Infusional Fluorouracil (category 1 for EBV-associated disease, category 2A for non–EBV-associated disease)[2-4]

Other Recommended
- Cisplatin/Infusional Fluorouracil[5]
- Cisplatin/Docetaxel (category 2B)[6]
- Following induction, agents used with concurrent systemic therapy/RT typically include Weekly Cisplatin[7] or Carboplatin.[8]

Useful in Certain Circumstances
- For M1 oligometastatic disease (PS 0–1), maintenance Capecitabine without concurrent RT following induction chemotherapy is an option.[9]

Systemic Therapy/RT Followed by Adjuvant Chemotherapy

Preferred
- Cisplatin + RT followed by Cisplatin/Infusional Fluorouracil[7,10]

Other Recommended
- Cisplatin + RT followed by Carboplatin/Infusional Fluorouracil[11]
- Cisplatin + RT without adjuvant chemotherapy[d,12]

Useful in Certain Circumstances
- If Cisplatin ineligible or intolerant, Carboplatin may be used as an alternative:
  - Carboplatin + RT followed by Carboplatin/Infusional Fluorouracil[8,13]
- Cisplatin + RT followed by Capecitabine ± induction chemotherapy[e] (for EBV-associated disease) (for T4,N1–3 or any T,N2–3)[14,15]

Reirradiation + Concurrent Systemic Therapy

- Platinum-based regimens (eg, Cisplatin, or Carboplatin only if Cisplatin ineligible/intolerant)[16,17]

[a] The recommendations are based on clinical trial data for those with EBV-associated nasopharynx cancer.
[b] For more information regarding *DPYD* testing, see the NCCN Guidelines for Colon Cancer.
[c] The categories of evidence and consensus for induction therapy vary depending on site (see disease-specific site in the Head and Neck Table of Contents).
[d] Use of cisplatin + RT without adjuvant chemotherapy is a category 2B recommendation for stage T3,N1–3,M0 or T4,N0–3,M0 or T0 (EBV+)–2,N2–3,M0 disease; it is a category 2A recommendation for all other stages when indicated.
[e] In a randomized phase 3 trial, 77% of patients who received metronomic capecitabine received induction chemotherapy prior to cisplatin/RT (Chen YP, et al. Lancet 2021;398:303-313).

Note: All recommendations are category 2A unless otherwise indicated.

References

Version 1.2026, 12/08/2025 © 2025 National Comprehensive Cancer Network® (NCCN®), All rights reserved. NCCN Guidelines® and this illustration may not be reproduced in any form without the express written permission of NCCN.

PLEASE NOTE that use of this NCCN Content is governed by the End-User License Agreement, and you MAY NOT distribute this Content or use it with any artificial intelligence model or tool.
Printed by Galya Basol Kochav on 1/4/2026 9:40:35 AM. Copyright © 2026 National Comprehensive Cancer Network, Inc. All Rights Reserved.

SYSTEMIC THERAPY FOR NASOPHARYNGEAL CANCERS[a,b]

Recurrent, Unresectable, Oligometastatic, or Metastatic Disease (with no surgery or RT option)

Preferred

First-Line[f]
- Cisplatin/Gemcitabine + Toripalimab-tpzi (category 1)[18]

Subsequent-Line
- Toripalimab-tpzi (if disease progression on or after platinum-containing therapy)[19]

Other Recommended

First-Line[f]
- Combination Therapy
  - Cisplatin/Gemcitabine (category 1)[20,21]
  - Cisplatin/Gemcitabine + other PD-1 inhibitor (eg, Pembrolizumab or Nivolumab)[18,22,23]
  - Cisplatin/Infusional Fluorouracil[24,25]
  - Cisplatin or Carboplatin/Docetaxel[26] or Paclitaxel[24]
  - Carboplatin + Cetuximab[27]
  - Carboplatin/Gemcitabine[1]
  - Carboplatin/Gemcitabine + Penpulimab-kcqx if non-keratinizing disease (category 2B)[28]
  - Cisplatin/Gemcitabine + Penpulimab-kcqx if non-keratinizing disease (category 2B)[28]
  - Cisplatin/Gemcitabine + Tislelizumab-jsgr[29] (category 2B)
- Single Agents
  - Capecitabine[30]
  - Carboplatin[31]
  - Cisplatin[32,33]
  - Docetaxel[34,35]
  - Infusional Fluorouracil[32]
  - Gemcitabine[36]
  - Methotrexate[26,37]
  - Paclitaxel[38]

Subsequent-Line
- Immunotherapy
  - Nivolumab if previously treated, recurrent or metastatic non-keratinizing disease (category 2B)[39,40]
  - Pembrolizumab if previously treated, PD-L1–positive, recurrent or metastatic disease (category 2B)[41]
  - Penpulimab-kcqx if non-keratinizing disease with progression on or after platinum-based chemotherapy and at least one other prior line of therapy (category 2B)[42]
  - Tislelizumab-jsgr[43] (category 2B)

Useful in Certain Circumstances

Subsequent-Line
- Pembrolizumab (for tumor mutational burden-high [TMB-H] tumors [≥10 mut/Mb])[44]

[a] The recommendations are based on clinical trial data for those with EBV-associated nasopharynx cancer.
[b] For more information regarding *DPYD* testing, see the NCCN Guidelines for Colon Cancer.
[f] If not previously used, these regimens may be considered in subsequent-line therapy as other recommended regimens.

Note: All recommendations are category 2A unless otherwise indicated.

References

Version 1.2026, 12/08/2025 © 2025 National Comprehensive Cancer Network® (NCCN®), All rights reserved. NCCN Guidelines® and this illustration may not be reproduced in any form without the express written permission of NCCN.

PLEASE NOTE that use of this NCCN Content is governed by the End-User License Agreement, and you MAY NOT distribute this Content or use it with any artificial intelligence model or tool.
Printed by Galya Basol Kochav on 1/4/2026 9:40:35 AM. Copyright © 2026 National Comprehensive Cancer Network, Inc. All Rights Reserved.

SYSTEMIC THERAPY FOR NASOPHARYNGEAL CANCERS
REFERENCES

[1] Zhang Y, Chen L, Hu GQ, et al. Gemcitabine and cisplatin induction chemotherapy in nasopharyngeal carcinoma. N Engl J Med 2019;381:1124-1135.
[2] Bae WK, Hwang JE, Shim HJ, et al. Phase II study of docetaxel, cisplatin, and 5-FU induction chemotherapy followed by chemoradiotherapy in locoregionally advanced nasopharyngeal cancer. Cancer Chemother Pharmacol 2010;65:589-595.
[3] Chen YP, Tang LL, Yang Q, et al. Induction chemotherapy plus concurrent chemoradiotherapy in endemic nasopharyngeal carcinoma: individual patient data pooled analysis of four randomized trials. Clin Cancer Res 2018;24:1824-1833.
[4] Sun Y, Li WF, Chen NY, et al. Induction chemotherapy plus concurrent chemoradiotherapy versus concurrent chemoradiotherapy alone in locoregionally advanced nasopharyngeal carcinoma: a phase 3, multicentre, randomised controlled trial. Lancet Oncol 2016;17:1509-1520.
[5] Posner MR, Hershock DM, Blajman CR, et al. Cisplatin and fluorouracil alone or with docetaxel in head and neck cancer. N Engl J Med 2007;357:1705-1715.
[6] Hui EP, Ma BB, Leung SF, et al. Randomized phase II trial of concurrent cisplatin-radiotherapy with or without neoadjuvant docetaxel and cisplatin in advanced nasopharyngeal carcinoma. J Clin Oncol 2009;27:242-249.
[7] Chan AT, Leung SF, Ngan RK, et al. Overall survival after concurrent cisplatin-radiotherapy compared with radiotherapy alone in locoregionally advanced nasopharyngeal carcinoma. J Natl Cancer Inst 2005;97:536-539.
[8] Chitapanarux I, Lorvidhaya V, Kamnerdsupaphon P, et al. Systemic therapy/RT comparing cisplatin versus carboplatin in locally advanced nasopharyngeal cancer: randomised, non-inferiority, open trial. Eur J Cancer 2007;43:1399-1406.
[9] Liu GY, Li WZ, Wang DS, et al. Effect of capecitabine maintenance therapy plus best supportive care vs best supportive care alone on progression-free survival among patients with newly diagnosed metastatic nasopharyngeal carcinoma who had received induction chemotherapy: A phase 3 randomized clinical trial. JAMA Oncol 2022;8:553-561.
[10] Al-Sarraf M, LeBlanc M, Giri PG, et al. Chemoradiotherapy versus radiotherapy in patients with advanced nasopharyngeal cancer: phase III randomized Intergroup study 0099. J Clin Oncol 1998;16:1310-1317.
[11] Dechaphunkul T, Pruegsanusak K, Sangthawan D, Sunpaweravong P. Concurrent chemoradiotherapy with carboplatin followed by carboplatin and 5-fluorouracil in locally advanced nasopharyngeal carcinoma. Head Neck Oncol 2011;3:30.
[12] Chen L, Hu CS, Chen XZ, et al. Concurrent chemoradiotherapy plus adjuvant chemotherapy versus concurrent chemoradiotherapy alone in patients with locoregionally advanced nasopharyngeal carcinoma: a phase 3 multicentre randomised controlled trial. Lancet Oncol 2012;13:163-171.
[13] Denis F, Garaud P, Bardet E, et al. Final results of the 94-01 French Head and Neck Oncology and Radiotherapy Group randomized trial comparing radiotherapy alone with concomitant radiochemotherapy in advanced-stage oropharynx carcinoma. J Clin Oncol 2004;22:69-76.
[14] Chen YP, Liu X, Zhou Q, et al. Metronomic capecitabine as adjuvant therapy in locoregionally advanced nasopharyngeal carcinoma: A multicentre, open-label, parallel-group, randomised, controlled, phase 3 trial. Lancet 2021;398:303-313.
[15] Miao J, Wang L, Tan SH, et al. Adjuvant capecitabine following concurrent chemoradiotherapy in locoregionally advanced nasopharyngeal carcinoma: A randomized clinical trial. JAMA Oncol 2022;8:1776-1785.
[16] Kong F, Zhou J, Du C, et al. Long-term survival and late complications of intensity-modulated radiotherapy for recurrent nasopharyngeal carcinoma. BMC Cancer 2018;18:1139.
[17] Lee VHF, Kwong DL, Leung T-W, et al. Hyperfractionation compared to standard fractionation in intensity-modulated radiation therapy for patients with locally advanced recurrent nasopharyngeal carcinoma. Eur Arch Otorhinolaryngol 2017;274:1067-1078.
[18] Mai HQ, Chen QY, Chen D, et al. Toripalimab plus chemotherapy for recurrent or metastatic nasopharyngeal carcinoma: the JUPITER-02 randomized clinical trial. JAMA 2023;330:1961-1970.
[19] Wang FH, Wei XL, Feng J, et al. Efficacy, safety, and correlative biomarkers of toripalimab in previously treated recurrent or metastatic nasopharyngeal carcinoma: a phase II clinical trial (POLARIS-02). J Clin Oncol 2021;39:704-712.
[20] Jin Y, Cai XY, Shi YX, et al. Comparison of five cisplatin-based regimens frequently used as the first-line protocols in metastatic nasopharyngeal carcinoma. J Cancer Res Clin Oncol 2012;138:1717-1725.
[21] Hong S, Zhang Y, Yu G, et al. Gemcitabine plus cisplatin versus fluorouracil plus cisplatin as first-line therapy for recurrent or metastatic nasopharyngeal carcinoma: Final overall survival analysis of GEM20110714 phase III study. J Clin Oncol 2021;39:3273-3282.
[22] Yang Y, Pan J, Wang H, et al. Tislelizumab plus chemotherapy as first-line treatment for recurrent or metastatic nasopharyngeal cancer: A multicenter phase 3 trial (RATIONALE-309). Cancer Cell 2023;41:1061-1072.
[23] Mai H-Q, Chen Q-Y, Chen D, et al. Toripalimab or placebo plus chemotherapy as first-line treatment in advanced nasopharyngeal carcinoma: A multicenter randomized phase 3 trial. Nat Med 2021;27:1536-1543.
[24] Gibson MK, Li Y, Murphy B, et al. Randomized phase III evaluation of cisplatin plus fluorouracil versus cisplatin plus paclitaxel in advanced head and neck cancer (E1395): an intergroup trial of the Eastern Cooperative Oncology Group. J Clin Oncol 2005;23:3562-3567.

Continued

Note: All recommendations are category 2A unless otherwise indicated.

Version 1.2026, 12/08/2025 © 2025 National Comprehensive Cancer Network® (NCCN®), All rights reserved. NCCN Guidelines® and this illustration may not be reproduced in any form without the express written permission of NCCN.

PLEASE NOTE that use of this NCCN Content is governed by the End-User License Agreement, and you MAY NOT distribute this Content or use it with any artificial intelligence model or tool.
Printed by Galya Basol Kochav on 1/4/2026 9:40:35 AM. Copyright © 2026 National Comprehensive Cancer Network, Inc. All Rights Reserved.

SYSTEMIC THERAPY FOR NASOPHARYNGEAL CANCERS
REFERENCES

[25] Forastiere AA, Metch B, Schuller DE, et al. Randomized comparison of cisplatin plus fluorouracil and carboplatin plus fluorouracil versus methotrexate in advanced squamous-cell carcinoma of the head and neck: a Southwest Oncology Group study. J Clin Oncol 1992;10:1245-1251.
[26] Samlowski WE, Moon J, Kuebler JP, et al. Evaluation of the combination of docetaxel/carboplatin in patients with metastatic or recurrent squamous cell carcinoma of the head and neck (SCCHN): a Southwest Oncology Group Phase II study. Cancer Invest 2007;25:182-188.
[27] Chan ATC, Hsu M-M, Goh BC, et al. Multicenter, phase II study of cetuximab in combination with carboplatin in patients with recurrent or metastatic nasopharyngeal carcinoma. J Clin Oncol 2005;23:3568-3576.
[28] Hu C, Chen X, Xu T, et al. Penpulimab versus placebo in combination with chemotherapy as first-line treatment for recurrent or metastatic nasopharyngeal carcinoma: a global, multicenter, randomized, double-blind, phase 3 trial (AK105-304). Cancer Res 2025;85:CT011–CT011.
[29] Yang Y, Qu S, Li J, et al. Camrelizumab versus placebo in combination with gemcitabine and cisplatin as first-line treatment for recurrent or metastatic nasopharyngeal carcinoma (captain-1st): A multicentre, randomised, double-blind, phase 3 trial. Lancet Oncol 2021;22:1162-1174.
[30] Martinez-Trufero J, Isla D, Adansa JC, et al. Phase II study of capecitabine as palliative treatment for patients with recurrent and metastatic squamous head and neck cancer after previous platinum-based treatment. Br J Cancer 2010;102:1687-1691.
[31] Al-Sarraf M, Metch B, Kish J, et al. Platinum analogs in recurrent and advanced head and neck cancer: a Southwest Oncology Group and Wayne State University Study. Cancer Treat Rep 1987;71:723-726.
[32] Burtness B, Goldwasser MA, Flood W, et al. Phase III randomized trial of cisplatin plus placebo compared with cisplatin plus cetuximab in metastatic/recurrent head and neck cancer: an Eastern Cooperative Oncology Group study. J Clin Oncol 2005;23:8646-8654.
[33] Jacobs C, Lyman G, Velez-Garcia E, et al. A phase III randomized study comparing cisplatin and fluorouracil as single agents and in combination for advanced squamous cell carcinoma of the head and neck. J Clin Oncol 1992;10:257-263.
[34] Catimel G, Verweij J, Mattijssen V, et al. Docetaxel (Taxotere): an active drug for the treatment of patients with advanced squamous cell carcinoma of the head and neck. EORTC Early Clinical Trials Group. Ann Oncol 1994;5:533-537.
[35] Guardiola E, Peyrade F, Chaigneau L, et al. Results of a randomised phase II study comparing docetaxel with methotrexate in patients with recurrent head and neck cancer. Eur J Cancer 2004;40:2071-2076.
[36] Zhang L, Zhang Y, Huang P-Y, et al. Phase II clinical study of gemcitabine in the treatment of patients with advanced nasopharyngeal carcinoma after the failure of platinum-based chemotherapy. Cancer Chemother Pharmacol 2008;61:33-38.
[37] Stewart JS, Cohen EE, Licitra L, et al. Phase III study of gefitinib compared with intravenous methotrexate for recurrent squamous cell carcinoma of the head and neck [corrected]. J Clin Oncol 2009;27:1864-1871.
[38] Grau JJ, Caballero M, Verger E, et al. Weekly paclitaxel for platin-resistant stage IV head and neck cancer patients. Acta Otolaryngol 2009;129:1294-1299.
[39] Delord JP, Hollebecque A, de Boer JP, et al. An open-label, multicohort, phase I/II study to evaluate nivolumab in patients with virus-associated tumors (CheckMate 358): Efficacy and safety in recurrent or metastatic (R/M) nasopharyngeal carcinoma (NPC) [abstract]. J Clin Oncol 2017;35(Suppl): Abstract 6025.
[40] Ma BBY, Lim WT, Goh BC, et al. Antitumor activity of nivolumab in recurrent and metastatic nasopharyngeal carcinoma: an international, multicenter study of the Mayo Clinic Phase 2 Consortium (NCI-9742). J Clin Oncol 2018;36:1412-1418.
[41] Hsu C, Lee SH, Ejadi S, et al. Safety and antitumor activity of pembrolizumab in patients with programmed death-ligand 1-positive nasopharyngeal carcinoma: results of the KEYNOTE-028 study. J Clin Oncol 2017;35:4050-4056.
[42] Chen X, Wang W, Zou Q, et al. Penpulimab, an anti-PD-1 antibody, for heavily pretreated metastatic nasopharyngeal carcinoma: a single-arm phase II study. Signal Transduct Target Ther 2024;9:148.
[43] Shen L, Guo J, Zhang Q, et al. Tislelizumab in Chinese patients with advanced solid tumors: an open-label, non comparative, phase 1/2 study. J Immunother Cancer 2020;8:e000437.
[44] Marabelle A, Fakih M, Lopez J, et al. Association of tumour mutational burden with outcomes in patients with advanced solid tumours treated with pembrolizumab: prospective biomarker analysis of the multicohort, open-label, phase 2 KEYNOTE-158 study. Lancet Oncol 2020;21:1353-1365.

Note: All recommendations are category 2A unless otherwise indicated.

Version 1.2026, 12/08/2025 © 2025 National Comprehensive Cancer Network® (NCCN®), All rights reserved. NCCN Guidelines® and this illustration may not be reproduced in any form without the express written permission of NCCN.

PLEASE NOTE that use of this NCCN Content is governed by the End-User License Agreement, and you MAY NOT distribute this Content or use it with any artificial intelligence model or tool.
Printed by Galya Basol Kochav on 1/4/2026 9:40:35 AM. Copyright © 2026 National Comprehensive Cancer Network, Inc. All Rights Reserved.

WORKUP[a]

- H&P[b,c] including a complete head and neck exam; mirror and/or fiberoptic examination as clinically indicated
- Biopsy of primary site or FNA of the neck[d]
- CT with contrast and thin angled cuts or cuts ≤1.25 mm through larynx and/or MRI with and without contrast of primary and neck[e]
- EUA with endoscopy
- As clinically indicated:
  - Chest CT (with or without contrast)[e]
  - Consider FDG-PET/CT[e]
  - Preanesthesia studies
  - Pulmonary function evaluation for conservation surgery candidates
  - Consider videostrobe for select patients
  - Dental evaluation[f]
  - Nutrition, speech, and swallowing evaluation/therapy[g]
  - Audiogram
  - Smoking cessation counseling[b]
  - Fertility/reproductive counseling[h]
  - Screening for hepatitis B
  - PD-L1 testing by IHC (CPS)
- Multidisciplinary consultation as clinically indicated

CLINICAL STAGING	TREATMENT OF PRIMARY AND NECK
Carcinoma in situ	Treatment (GLOT-2)
Amenable to larynx-preserving (conservation) surgery (T1–T2,N0 or select T3,N0)[i]	Treatment (GLOT-2)
T3 requiring (amenable to) total laryngectomy (N0–1)	Treatment of Primary and Neck (GLOT-3)
T3 requiring (amenable to) total laryngectomy (N2–3)	Treatment of Primary and Neck (GLOT-4)
T4a disease	Treatment of Primary and Neck (GLOT-6)
T4b,N0–3 or Unresectable nodal disease or Unfit for surgery	Treatment of Very Advanced Head and Neck Cancer (ADV-1)
Metastatic (M1) disease at initial presentation	Treatment of Very Advanced Head and Neck Cancer (ADV-2)

[a] Complete workup may not be indicated for Tis,T1, but H&P examination and biopsy are required. Direct laryngoscopy under anesthesia is generally recommended for all cases.
[b] H&P should include documentation and quantification (pack years smoked) of tobacco use history, as well as alcohol use and counseling. All patients who currently smoke should be advised to quit smoking, and those who formerly smoked should be advised to remain abstinent from smoking. For additional cessation support, refer to the Smoking Cessation and Treatment Resources in the NCCN Guidelines for Smoking Cessation.
[c] Screen for distress. Refer to the NCCN Distress Thermometer and Problem List, which includes social determinants of health. See NCCN Guidelines for Distress Management (DIS-A).
[d] Image-guided (US or CT) needle biopsy of cystic neck nodes may offer better diagnostic yield than FNA by palpation alone for initial diagnosis in this setting. For unresectable or metastatic disease where there is a plan for systemic therapy, a core biopsy would allow for biomarker testing.
[e] Principles of Imaging (IMG-A).
[f] Principles of Oral/Dental Evaluation and Management (DENT-A).
[g] Principles of Nutrition: Management and Supportive Care (NUTR-A).
[h] See fertility and reproductive endocrine considerations in the NCCN Guidelines for Adolescent and Young Adult (AYA) Oncology.
[i] Nodal disease in such glottic tumors is rare. See Discussion.

Note: All recommendations are category 2A unless otherwise indicated.

Version 1.2026, 12/08/2025 © 2025 National Comprehensive Cancer Network® (NCCN®), All rights reserved. NCCN Guidelines® and this illustration may not be reproduced in any form without the express written permission of NCCN.

PLEASE NOTE that use of this NCCN Content is governed by the End-User License Agreement, and you MAY NOT distribute this Content or use it with any artificial intelligence model or tool.
Printed by Galya Basol Kochav on 1/4/2026 9:40:35 AM. Copyright © 2026 National Comprehensive Cancer Network, Inc. All Rights Reserved.

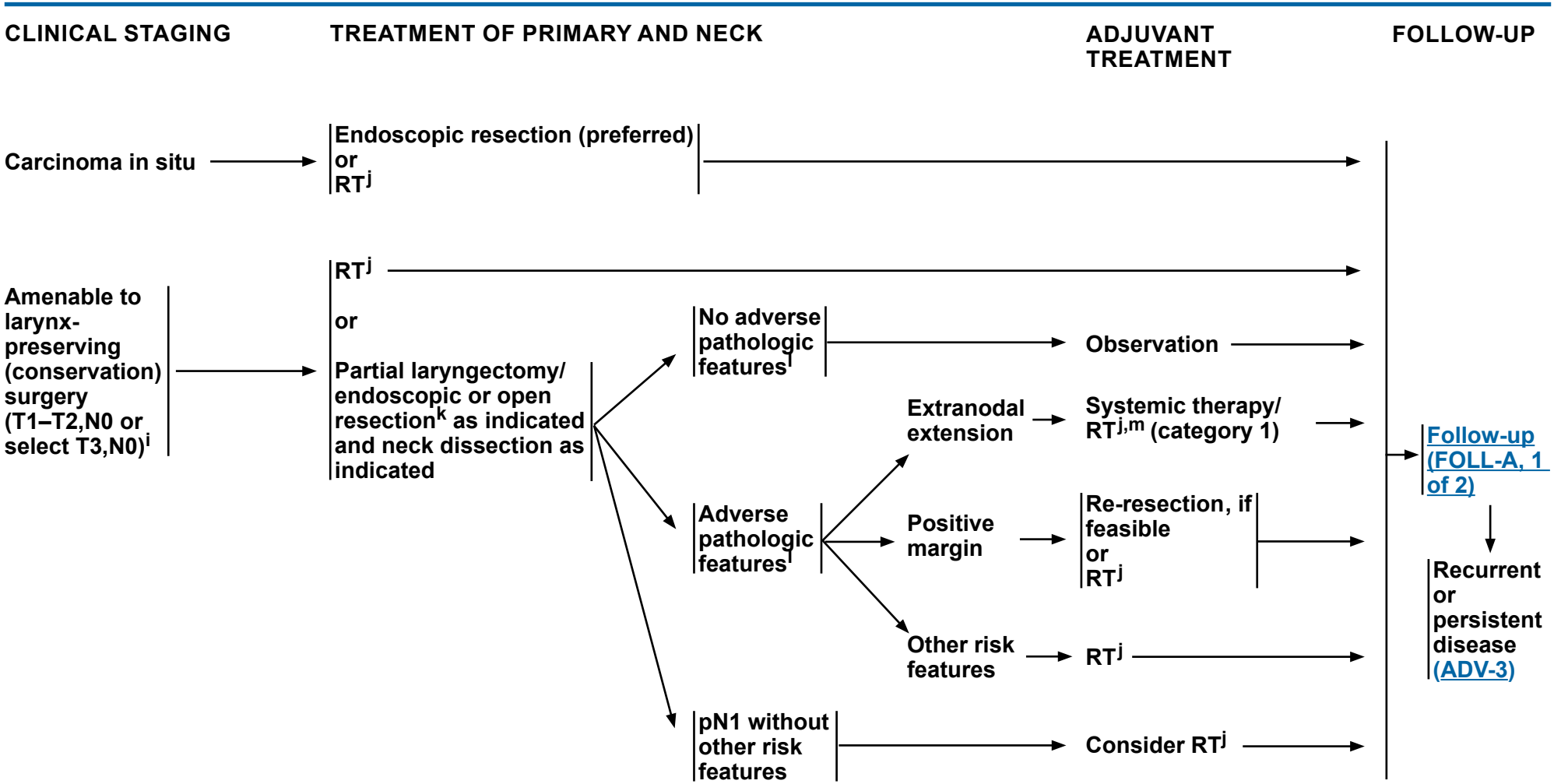

[i] Nodal disease in such glottic tumors is rare. See Discussion.
[j] Principles of Radiation Therapy (GLOT-A).
[k] Principles of Surgery (SURG-A).

[l] Adverse pathologic features: extranodal extension, positive margins, close margins, pT4 primary, pN2 or pN3 nodal disease, perineural invasion, vascular invasion, lymphatic invasion, and subglottic extension (Discussion).
[m] Principles of Systemic Therapy for Non-Nasopharyngeal Cancers (SYST-A).

Note: All recommendations are category 2A unless otherwise indicated.

Version 1.2026, 12/08/2025 © 2025 National Comprehensive Cancer Network® (NCCN®), All rights reserved. NCCN Guidelines® and this illustration may not be reproduced in any form without the express written permission of NCCN.

PLEASE NOTE that use of this NCCN Content is governed by the End-User License Agreement, and you MAY NOT distribute this Content or use it with any artificial intelligence model or tool.
Printed by Galya Basol Kochav on 1/4/2026 9:40:35 AM. Copyright © 2026 National Comprehensive Cancer Network, Inc. All Rights Reserved.

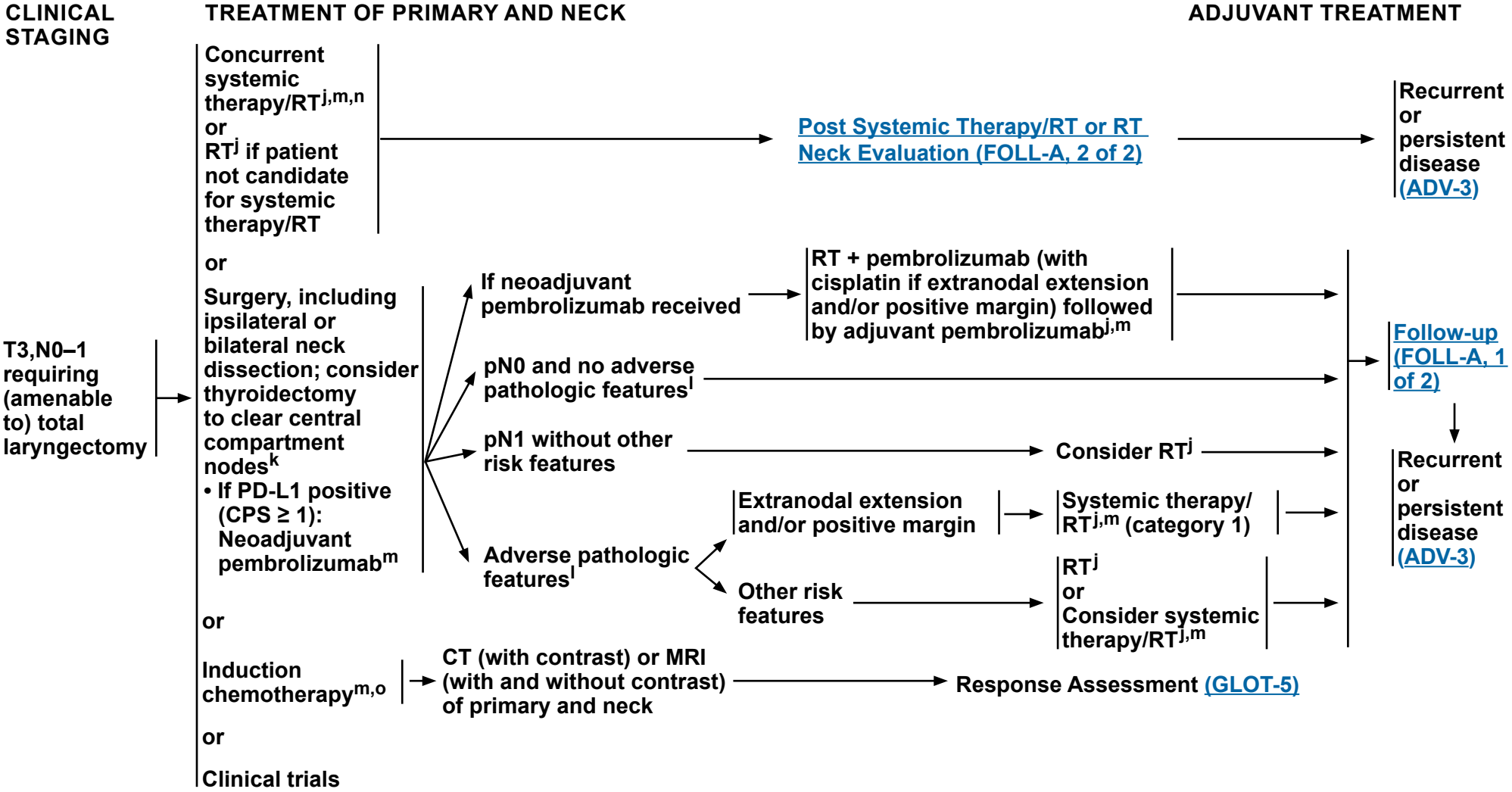

[j] Principles of Radiation Therapy (GLOT-A).
[k] Principles of Surgery (SURG-A).
[l] Adverse pathologic features: extranodal extension, positive margins, close margins, pT4 primary, pN2 or pN3 nodal disease, perineural invasion, vascular invasion, lymphatic invasion, and subglottic extension (Discussion).
[m] Principles of Systemic Therapy for Non-Nasopharyngeal Cancers (SYST-A).
[n] When using concurrent systemic therapy/RT, the preferred agent is cisplatin (category 1). See Principles of Systemic Therapy for Non-Nasopharyngeal Cancers (SYST-A).
[o] See Discussion on induction chemotherapy.

Note: All recommendations are category 2A unless otherwise indicated.

Version 1.2026, 12/08/2025 © 2025 National Comprehensive Cancer Network® (NCCN®), All rights reserved. NCCN Guidelines® and this illustration may not be reproduced in any form without the express written permission of NCCN.

PLEASE NOTE that use of this NCCN Content is governed by the End-User License Agreement, and you MAY NOT distribute this Content or use it with any artificial intelligence model or tool.
Printed by Galya Basol Kochav on 1/4/2026 9:40:35 AM. Copyright © 2026 National Comprehensive Cancer Network, Inc. All Rights Reserved.

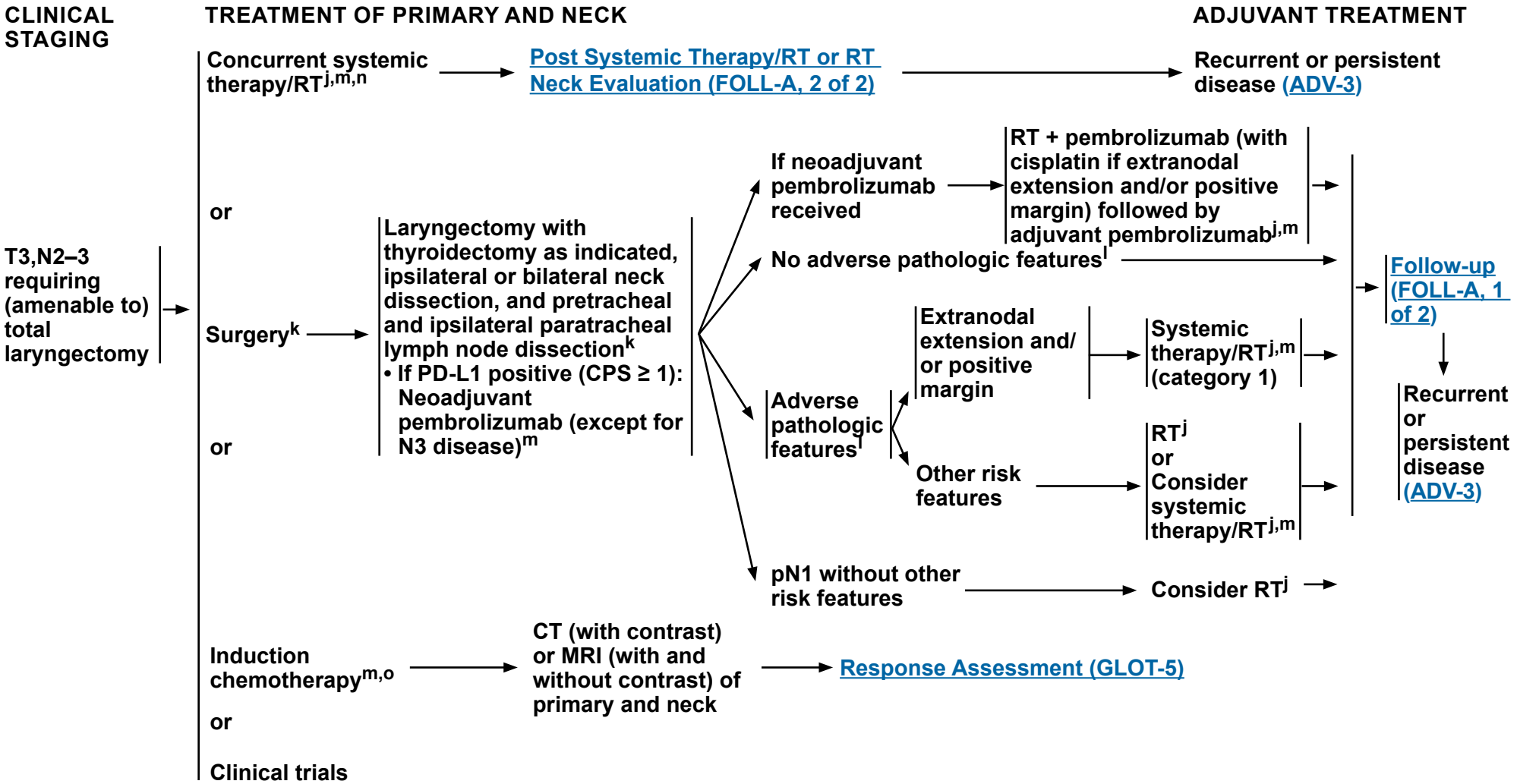

[j] Principles of Radiation Therapy (GLOT-A).
[k] Principles of Surgery (SURG-A).
[l] Adverse pathologic features: extranodal extension, positive margins, close margins, pT4 primary, pN2 or pN3 nodal disease, perineural invasion, vascular invasion, lymphatic invasion, and subglottic extension (Discussion).
[m] Principles of Systemic Therapy for Non-Nasopharyngeal Cancers (SYST-A).
[n] When using concurrent systemic therapy/RT, the preferred agent is cisplatin (category 1). See Principles of Systemic Therapy for Non-Nasopharyngeal Cancers (SYST-A).
[o] See Discussion on induction chemotherapy.

Note: All recommendations are category 2A unless otherwise indicated.

Version 1.2026, 12/08/2025 © 2025 National Comprehensive Cancer Network® (NCCN®), All rights reserved. NCCN Guidelines® and this illustration may not be reproduced in any form without the express written permission of NCCN.

PLEASE NOTE that use of this NCCN Content is governed by the End-User License Agreement, and you MAY NOT distribute this Content or use it with any artificial intelligence model or tool.
Printed by Galya Basol Kochav on 1/4/2026 9:40:35 AM. Copyright © 2026 National Comprehensive Cancer Network, Inc. All Rights Reserved.

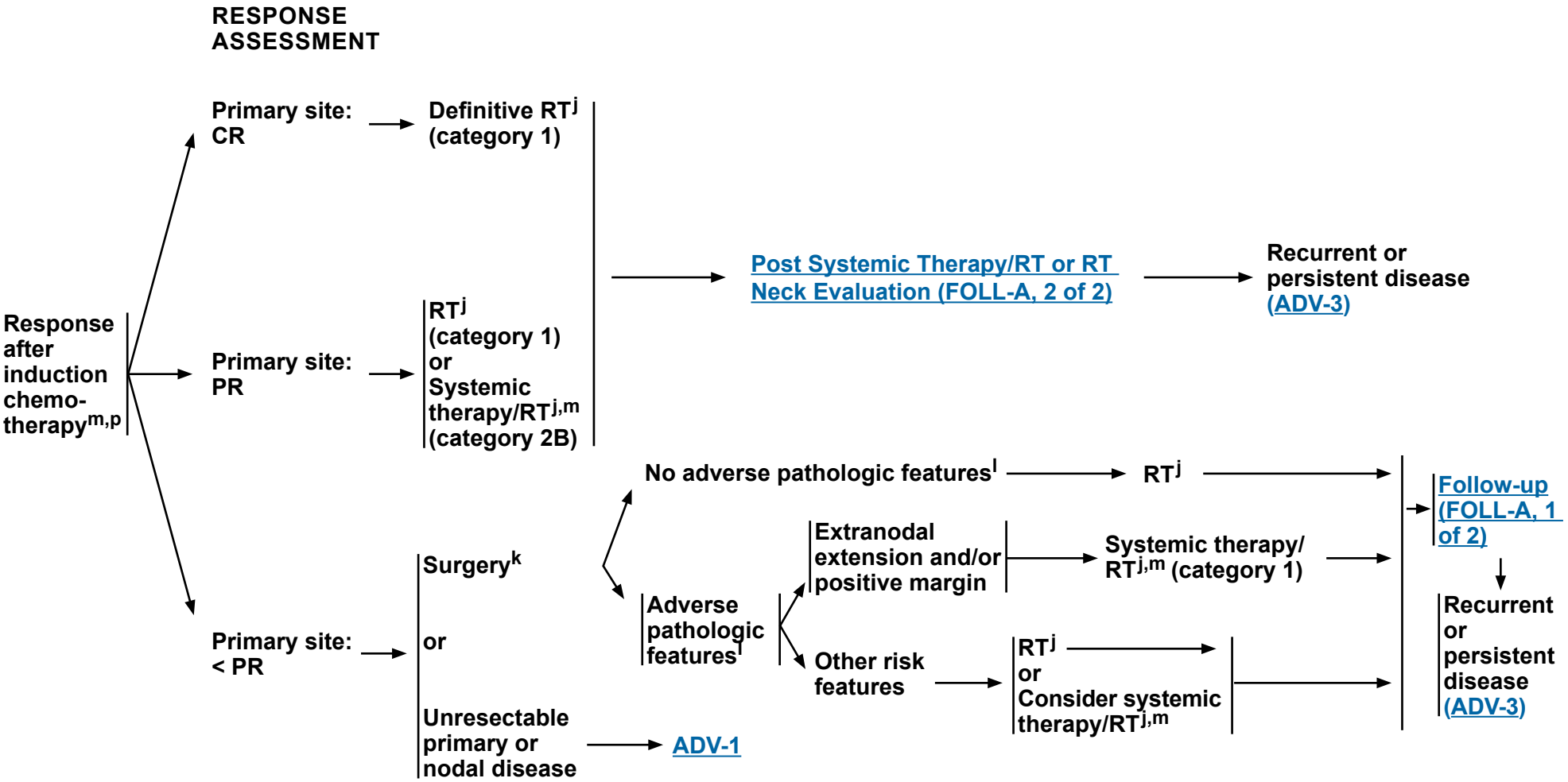

[j] Principles of Radiation Therapy (GLOT-A).
[k] Principles of Surgery (SURG-A).
[l] Adverse pathologic features: extranodal extension, positive margins, close margins, pT4 primary, pN2 or pN3 nodal disease, perineural invasion, vascular invasion, lymphatic invasion, and subglottic extension (Discussion).
[m] Principles of Systemic Therapy for Non-Nasopharyngeal Cancers (SYST-A).
[p] In randomized clinical trials, assessment of response has been done after 2 or 3 cycles.

Note: All recommendations are category 2A unless otherwise indicated.

Version 1.2026, 12/08/2025 © 2025 National Comprehensive Cancer Network® (NCCN®), All rights reserved. NCCN Guidelines® and this illustration may not be reproduced in any form without the express written permission of NCCN.

PLEASE NOTE that use of this NCCN Content is governed by the End-User License Agreement, and you MAY NOT distribute this Content or use it with any artificial intelligence model or tool.
Printed by Galya Basol Kochav on 1/4/2026 9:40:35 AM. Copyright © 2026 National Comprehensive Cancer Network, Inc. All Rights Reserved.

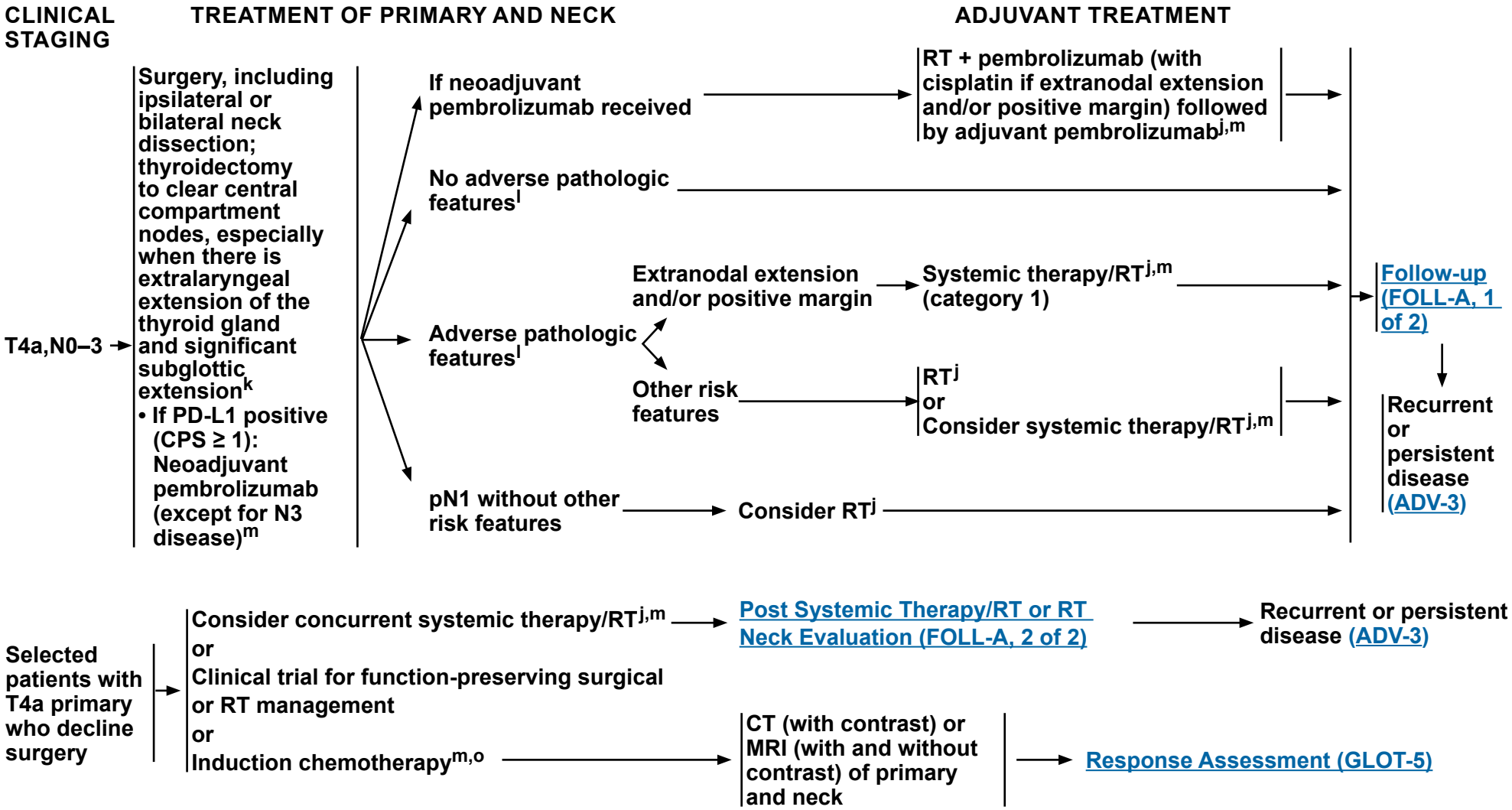

[j] Principles of Radiation Therapy (GLOT-A).
[k] Principles of Surgery (SURG-A).
[l] Adverse pathologic features: extranodal extension, positive margins, close margins, pT4 primary, pN2 or pN3 nodal disease, perineural invasion, vascular invasion, lymphatic invasion, and subglottic extension (Discussion).
[m] Principles of Systemic Therapy for Non-Nasopharyngeal Cancers (SYST-A).
[o] See Discussion on induction chemotherapy.

Note: All recommendations are category 2A unless otherwise indicated.

Version 1.2026, 12/08/2025 © 2025 National Comprehensive Cancer Network® (NCCN®), All rights reserved. NCCN Guidelines® and this illustration may not be reproduced in any form without the express written permission of NCCN.

PLEASE NOTE that use of this NCCN Content is governed by the End-User License Agreement, and you MAY NOT distribute this Content or use it with any artificial intelligence model or tool.
Printed by Galya Basol Kochav on 1/4/2026 9:40:35 AM. Copyright © 2026 National Comprehensive Cancer Network, Inc. All Rights Reserved.

PRINCIPLES OF RADIATION THERAPY[a]

DEFINITIVE:

RT Alone

- **Tis,N0: 60.75 Gy (2.25 Gy/fraction) to 66 Gy (2.0 Gy/fraction)**
- **T1,N0:**
  - **63 Gy (2.25 Gy/fraction, preferred) to 66 Gy (2.0 Gy/fraction)**
    or
  - **60 Gy (2.4 Gy/fraction)[1]**
    or
  - **50 Gy (3.12 Gy/fraction) to 52 Gy (3.28 Gy/fraction)[2]**
- **T2,N0: 64.8(2.4 Gy/fraction) to 70 Gy (2.0 Gy/fraction)[1]**
- **T3,N0 or ≥T2,N1:**
  - **PTV**
    - ◊ **High risk: Primary tumor and involved lymph nodes (this includes possible local subclinical infiltration at the primary site and at the high-risk level lymph node[s])**
      - **Fractionation: 66 Gy (2.2 Gy/fraction) to 70 Gy (2.0 Gy/fraction); daily Monday–Friday in 6–7 weeks[b]**
      - **Concomitant boost accelerated RT:**
        - **72 Gy/6 weeks (1.8 Gy/fraction, large field; 1.5 Gy boost as second daily fraction during last 12 treatment days)**
        - **66–70 Gy (2.0 Gy/fraction; 6 fractions/wk accelerated)**
      - **Hyperfractionation: 79.2–81.6 Gy/7 weeks (1.2 Gy/fraction, twice daily)**
    - ◊ **Low to intermediate risk: Sites of suspected subclinical spread – 44–50 Gy (2.0 Gy/fraction) to 54–63 Gy (1.6–1.8 Gy/fraction)[c]**

IMRT (preferred) is recommended.

CONCURRENT SYSTEMIC THERAPY/RT[d,e]:

- **PTV**
  - **High risk: Typically 70 Gy (2.0 Gy/fraction)**
  - **Low to intermediate risk: 44–50 Gy (2.0 Gy/fraction) to 54–63 Gy (1.6–1.8 Gy/fraction)[c]**

[1] Kodaira T, Kagami Y, Machida R, et al. Long-term follow-up of a randomized controlled trial on accelerated radiation therapy versus standard fractionated radiation therapy for early glottic cancer (JCOG0701A3). Int J Radiat Oncol Biol Phys 2023;117:1118-1124.
[2] Gowda RV, Henk JM, Mais KL, et al. Three weeks radiotherapy for T1 glottic cancer: the Christie and Royal Marsden Hospital Experience. Radiother Oncol 2003;68:105-111.

[a] See Principles of Radiation Techniques (RAD-A) and Discussion.
[b] For doses >70 Gy, some clinicians think that the fractionation should be slightly modified (eg, <2.0 Gy/fraction for at least some of the treatment) to minimize toxicity. An additional 2–3 doses can be added depending on clinical circumstances.
[c] Suggest 44–50 Gy in sequentially planned IMRT or 54–63 Gy with IMRT dose painting technique (dependent on dose per fraction).
[d] Principles of Systemic Therapy for Non-Nasopharyngeal Cancers (SYST-A).
[e] Based on published data, concurrent systemic therapy/RT most commonly uses conventional fractionation at 2.0 Gy per fraction to a typical dose of 70 Gy in 7 weeks with single-agent cisplatin given every 3 weeks at 100 mg/m^2; 2–3 cycles of chemotherapy are used depending on the radiation fractionation scheme (RTOG 0129) (Ang KK, Harris J, Wheeler R, et al. Human papillomavirus and survival of patients with oropharyngeal cancer. N Engl J Med 2010;363:24-35). When carboplatin and fluorouracil are used, then the recommended regimen is standard fractionation plus 3 cycles of chemotherapy (Bourhis J, Sire C, Graff P, et al. Concomitant chemoradiotherapy versus acceleration of radiotherapy with or without concomitant chemotherapy in locally advanced head and neck carcinoma [GORTEC 99-02]: an open-label phase 3 randomised trial. Lancet Oncol 2012;13:145-153). Other fraction sizes (eg, 1.8 Gy, conventional), multiagent chemotherapy, other dosing schedules of cisplatin, or altered fractionation with chemotherapy are efficacious, and there is no consensus on the optimal approach. In general, the use of concurrent systemic therapy/RT carries a high toxicity burden; multiagent chemotherapy will likely further increase the toxicity burden. For any systemic therapy/RT approach, close attention should be paid to published reports for the specific chemotherapy agent, dose, and schedule of administration. Systemic therapy/RT should be performed by an experienced team and should include substantial supportive care.

Note: All recommendations are category 2A unless otherwise indicated.

Version 1.2026, 12/08/2025 © 2025 National Comprehensive Cancer Network® (NCCN®), All rights reserved. NCCN Guidelines® and this illustration may not be reproduced in any form without the express written permission of NCCN.

PLEASE NOTE that use of this NCCN Content is governed by the End-User License Agreement, and you MAY NOT distribute this Content or use it with any artificial intelligence model or tool.
Printed by Galya Basol Kochav on 1/4/2026 9:40:35 AM. Copyright © 2026 National Comprehensive Cancer Network, Inc. All Rights Reserved.

PRINCIPLES OF RADIATION THERAPY[a]

POSTOPERATIVE:

RT or Concurrent Systemic Therapy/RT[d,3-6]

- **Preferred interval between resection and initiation of postoperative RT is ≤6 weeks.**
- **PTV**
  - **High risk: Adverse pathologic features such as positive margins (see footnote l on GLOT-3).**
    - **60–66 Gy (2.0 Gy/fraction); daily Monday–Friday in 6–6.5 weeks**
  - **Low to intermediate risk: Sites of suspected subclinical spread**
    - **44–50 Gy (2.0 Gy/fraction) to 54–63 Gy (1.6–1.8 Gy/fraction)[c]**

IMRT (preferred) is recommended.

[a] See Principles of Radiation Techniques (RAD-A) and Discussion.
[c] Suggest 44–50 Gy in sequentially planned IMRT or 54–63 Gy with IMRT dose painting technique (dependent on dose per fraction).
[d] Principles of Systemic Therapy for Non-Nasopharyngeal Cancers (SYST-A).

[3] Bernier J, Domenge C, Ozsahin M, et al. Postoperative irradiation with or without concomitant chemotherapy for locally advanced head and neck cancer. N Engl J Med 2004;350:1945-1952.
[4] Cooper JS, Pajak TF, Forastiere AA, et al. Postoperative concurrent radiotherapy and chemotherapy for high-risk squamous-cell carcinoma of the head and neck. N Engl J Med 2004;350:1937-1944.
[5] Bernier J, Cooper JS, Pajak TF, et al. Defining risk levels in locally advanced head and neck cancers: A comparative analysis of concurrent postoperative radiation plus chemotherapy trials of the EORTC (#22931) and RTOG (#9501). Head Neck 2005;27:843-850.
[6] Cooper JS, Zhang Q, Pajak TF, et al. Long-term follow-up of the RTOG 9501/intergroup phase III trial: postoperative concurrent radiation therapy and chemotherapy in high-risk squamous cell carcinoma of the head and neck. Int J Radiat Oncol Biol Phys 2012;84:1198-1205.

Note: All recommendations are category 2A unless otherwise indicated.

Version 1.2026, 12/08/2025 © 2025 National Comprehensive Cancer Network® (NCCN®), All rights reserved. NCCN Guidelines® and this illustration may not be reproduced in any form without the express written permission of NCCN.

PLEASE NOTE that use of this NCCN Content is governed by the End-User License Agreement, and you MAY NOT distribute this Content or use it with any artificial intelligence model or tool.
Printed by Galya Basol Kochav on 1/4/2026 9:40:35 AM. Copyright © 2026 National Comprehensive Cancer Network, Inc. All Rights Reserved.

WORKUP

- H&P[a,b] including a complete head and neck exam; mirror and/or fiberoptic examination as clinically indicated
- Biopsy of primary site or FNA of the neck[c]
- Chest CT (with or without contrast) as clinically indicated[d]
- CT with contrast and thin angled cuts or cuts ≤1.25 mm through larynx and/or MRI with and without contrast of primary and neck[d]
- Consider FDG-PET/CT[d]
- EUA with endoscopy
- As clinically indicated:
  - Preanesthesia studies
  - Consider PFTs for conservation surgery candidates
  - Consider videostrobe for select patients
  - Dental evaluation[e]
  - Nutrition, speech, and swallowing evaluation/therapy[f]
  - Audiogram
  - Smoking cessation counseling[a]
  - Fertility/reproductive counseling[g]
  - Screening for hepatitis B
  - PD-L1 testing by IHC (CPS)
- Multidisciplinary consultation as clinically indicated

CLINICAL STAGING

- Amenable to larynx-preserving (conservation) surgery (most T1–2,N0; selected T3) → Treatment of Primary and Neck (SUPRA-2)
- Requiring (amenable to) total laryngectomy (T3,N0) → Treatment of Primary and Neck (SUPRA-3)
- T4a,N0 → Treatment of Primary and Neck (SUPRA-8)
- Node-positive disease → Clinical Staging (SUPRA-4)
- T4b,N0–3 or Unresectable nodal disease or Unfit for surgery → Treatment of Very Advanced Head and Neck Cancer (ADV-1)
- Metastatic (M1) disease at initial presentation → Treatment of Very Advanced Head and Neck Cancer (ADV-2)

[a] H&P should include documentation and quantification (pack years smoked) of tobacco use history, as well as alcohol use and counseling. All patients who currently smoke should be advised to quit smoking, and those who formerly smoked should be advised to remain abstinent from smoking. For additional cessation support, refer to the Smoking Cessation and Treatment Resources in the NCCN Guidelines for Smoking Cessation.

[b] Screen for distress. Refer to the NCCN Distress Thermometer and Problem List, which includes social determinants of health. See NCCN Guidelines for Distress Management (DIS-A).

[c] Image-guided (US or CT) needle biopsy of cystic neck nodes may offer better diagnostic yield than FNA by palpation alone for initial diagnosis in this setting. For unresectable or metastatic disease where there is a plan for systemic therapy, a core biopsy would allow for biomarker testing.

[d] Principles of Imaging (IMG-A).

[e] Principles of Oral/Dental Evaluation and Management (DENT-A).

[f] Principles of Nutrition: Management and Supportive Care (NUTR-A).

[g] See fertility and reproductive endocrine considerations in the NCCN Guidelines for Adolescent and Young Adult (AYA) Oncology.

Note: All recommendations are category 2A unless otherwise indicated.

Version 1.2026, 12/08/2025 © 2025 National Comprehensive Cancer Network® (NCCN®), All rights reserved. NCCN Guidelines® and this illustration may not be reproduced in any form without the express written permission of NCCN.

PLEASE NOTE that use of this NCCN Content is governed by the End-User License Agreement, and you MAY NOT distribute this Content or use it with any artificial intelligence model or tool.
Printed by Galya Basol Kochav on 1/4/2026 9:40:35 AM. Copyright © 2026 National Comprehensive Cancer Network, Inc. All Rights Reserved.

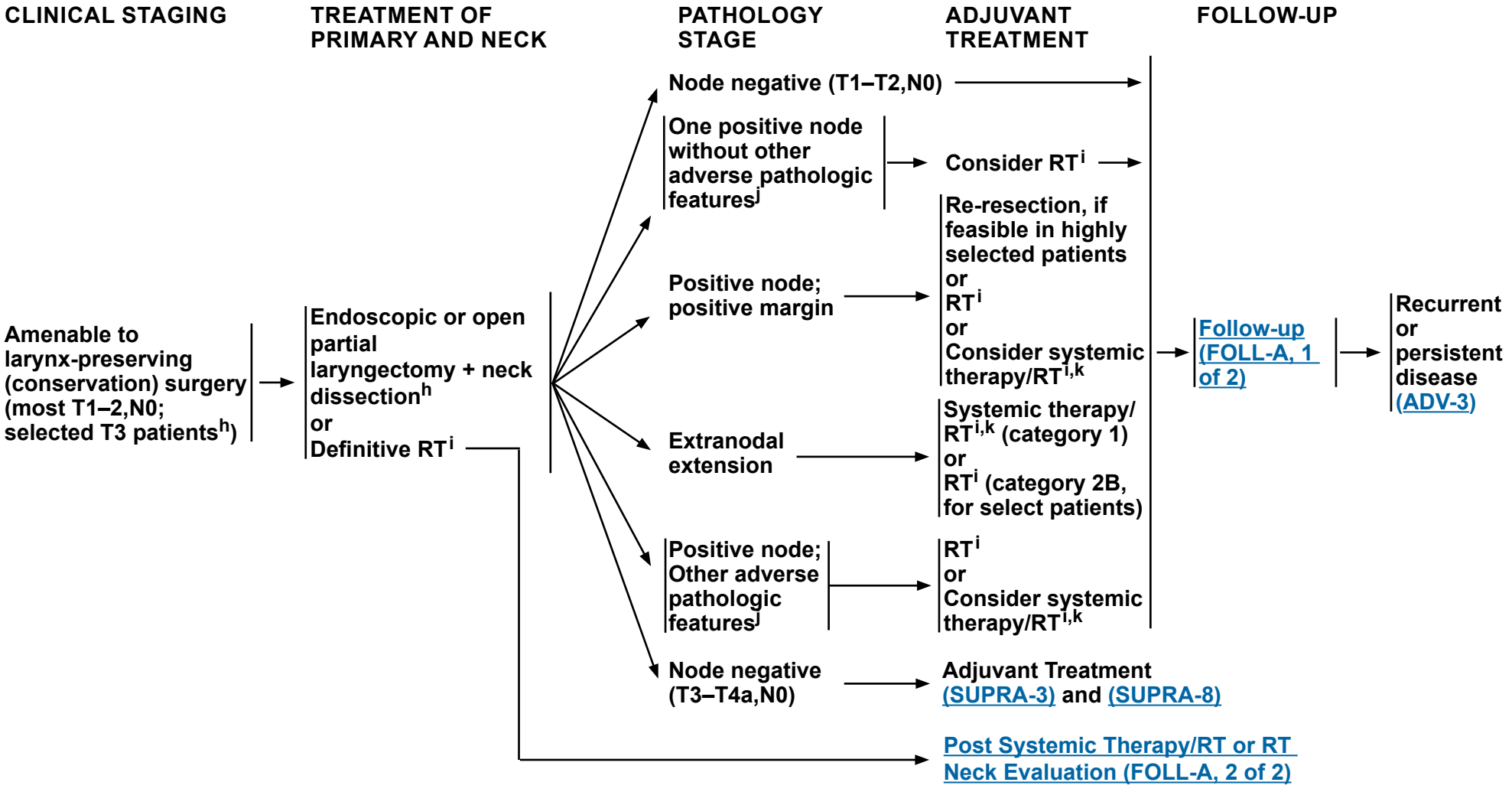

[h] Principles of Surgery (SURG-A).
[i] Principles of Radiation Therapy (SUPRA-A).

[j] Adverse pathologic features: extranodal extension, positive margins, close margins, pT3 or pT4 primary, pN2 or pN3 nodal disease, perineural invasion, vascular invasion, and lymphatic invasion (Discussion).
[k] Principles of Systemic Therapy for Non-Nasopharyngeal Cancers (SYST-A).

Note: All recommendations are category 2A unless otherwise indicated.

Version 1.2026, 12/08/2025 © 2025 National Comprehensive Cancer Network® (NCCN®), All rights reserved. NCCN Guidelines® and this illustration may not be reproduced in any form without the express written permission of NCCN.

PLEASE NOTE that use of this NCCN Content is governed by the End-User License Agreement, and you MAY NOT distribute this Content or use it with any artificial intelligence model or tool.
Printed by Galya Basol Kochav on 1/4/2026 9:40:35 AM. Copyright © 2026 National Comprehensive Cancer Network, Inc. All Rights Reserved.

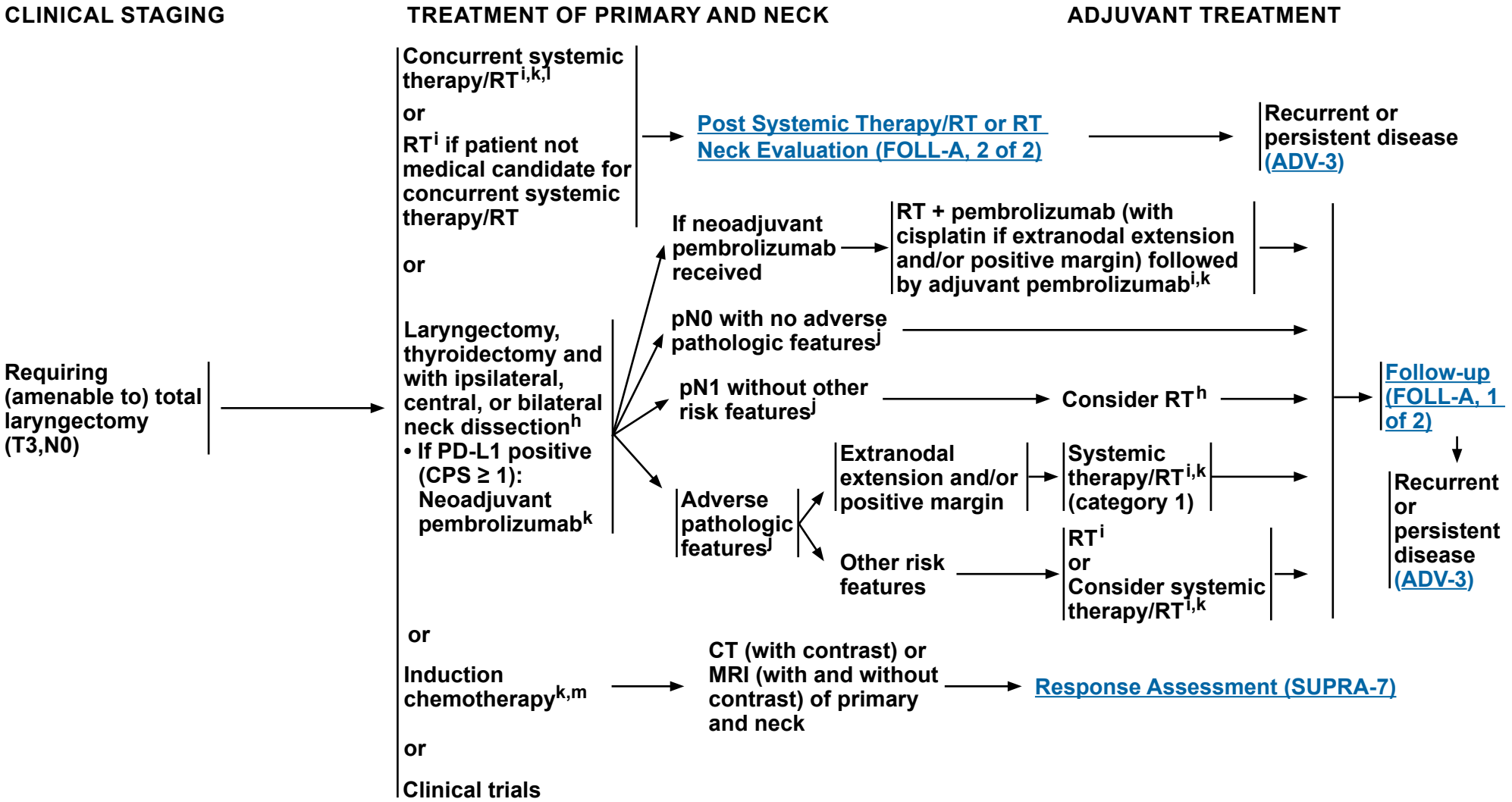

[h] Principles of Surgery (SURG-A).
[i] Principles of Radiation Therapy (SUPRA-A).
[j] Adverse pathologic features: extranodal extension, positive margins, close margins, pT3 or pT4 primary, pN2 or pN3 nodal disease, perineural invasion, vascular invasion, and lymphatic invasion (Discussion).
[k] Principles of Systemic Therapy for Non-Nasopharyngeal Cancers (SYST-A).
[l] When using concurrent systemic therapy/RT, the preferred agent is cisplatin (category 1). See Principles of Systemic Therapy for Non-Nasopharyngeal Cancers (SYST-A).
[m] See Discussion on induction chemotherapy.

Note: All recommendations are category 2A unless otherwise indicated.

Version 1.2026, 12/08/2025 © 2025 National Comprehensive Cancer Network® (NCCN®), All rights reserved. NCCN Guidelines® and this illustration may not be reproduced in any form without the express written permission of NCCN.

PLEASE NOTE that use of this NCCN Content is governed by the End-User License Agreement, and you MAY NOT distribute this Content or use it with any artificial intelligence model or tool.
Printed by Galya Basol Kochav on 1/4/2026 9:40:35 AM. Copyright © 2026 National Comprehensive Cancer Network, Inc. All Rights Reserved.

CLINICAL STAGING

Node-positive disease

- **Amenable to larynx-preserving (conservation) surgery (T1–2,N+ and selected T3,N1)** → **Treatment of Primary and Neck (SUPRA-5)**
- **Requiring (amenable to) total laryngectomy (Most T3,N1–3)** → **Treatment of Primary and Neck (SUPRA-6)**
- **T4a,N1–N3** → **Treatment of Primary and Neck (SUPRA-8)**
- **T4b,N1–3 or Unresectable nodal disease or Unfit for surgery** → **Treatment of Head and Neck Cancer (ADV-1)**

Note: All recommendations are category 2A unless otherwise indicated.

Version 1.2026, 12/08/2025 © 2025 National Comprehensive Cancer Network® (NCCN®), All rights reserved. NCCN Guidelines® and this illustration may not be reproduced in any form without the express written permission of NCCN.

PLEASE NOTE that use of this NCCN Content is governed by the End-User License Agreement, and you MAY NOT distribute this Content or use it with any artificial intelligence model or tool.
Printed by Galya Basol Kochav on 1/4/2026 9:40:35 AM. Copyright © 2026 National Comprehensive Cancer Network, Inc. All Rights Reserved.

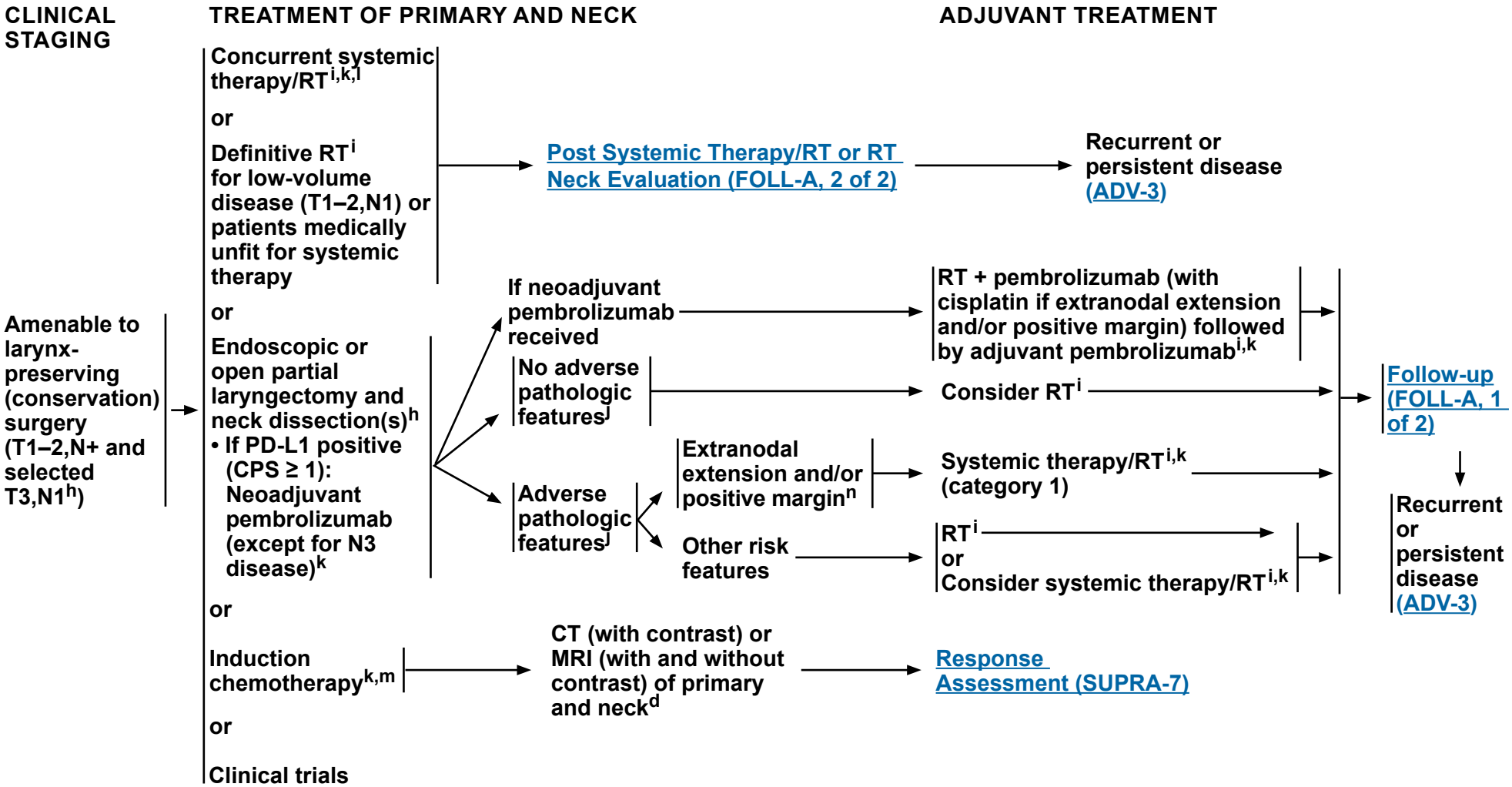

[d] Principles of Imaging (IMG-A).
[h] Principles of Surgery (SURG-A).
[i] Principles of Radiation Therapy (SUPRA-A).
[j] Adverse pathologic features: extranodal extension, positive margins, close margins, pT3 or pT4 primary, pN2 or pN3 nodal disease, perineural invasion, vascular invasion, and lymphatic invasion (Discussion).
[k] Principles of Systemic Therapy for Non-Nasopharyngeal Cancers (SYST-A).
[l] When using concurrent systemic therapy/RT, the preferred agent is cisplatin (category 1). See Principles of Systemic Therapy for Non-Nasopharyngeal Cancers (SYST-A).
[m] See Discussion on induction chemotherapy.
[n] In highly select patients, re-resection (if negative margins are feasible and can be achieved without total laryngectomy) where it would potentially change the subsequent indication for chemotherapy.

Note: All recommendations are category 2A unless otherwise indicated.

Version 1.2026, 12/08/2025 © 2025 National Comprehensive Cancer Network® (NCCN®), All rights reserved. NCCN Guidelines® and this illustration may not be reproduced in any form without the express written permission of NCCN.

PLEASE NOTE that use of this NCCN Content is governed by the End-User License Agreement, and you MAY NOT distribute this Content or use it with any artificial intelligence model or tool.
Printed by Galya Basol Kochav on 1/4/2026 9:40:35 AM. Copyright © 2026 National Comprehensive Cancer Network, Inc. All Rights Reserved.

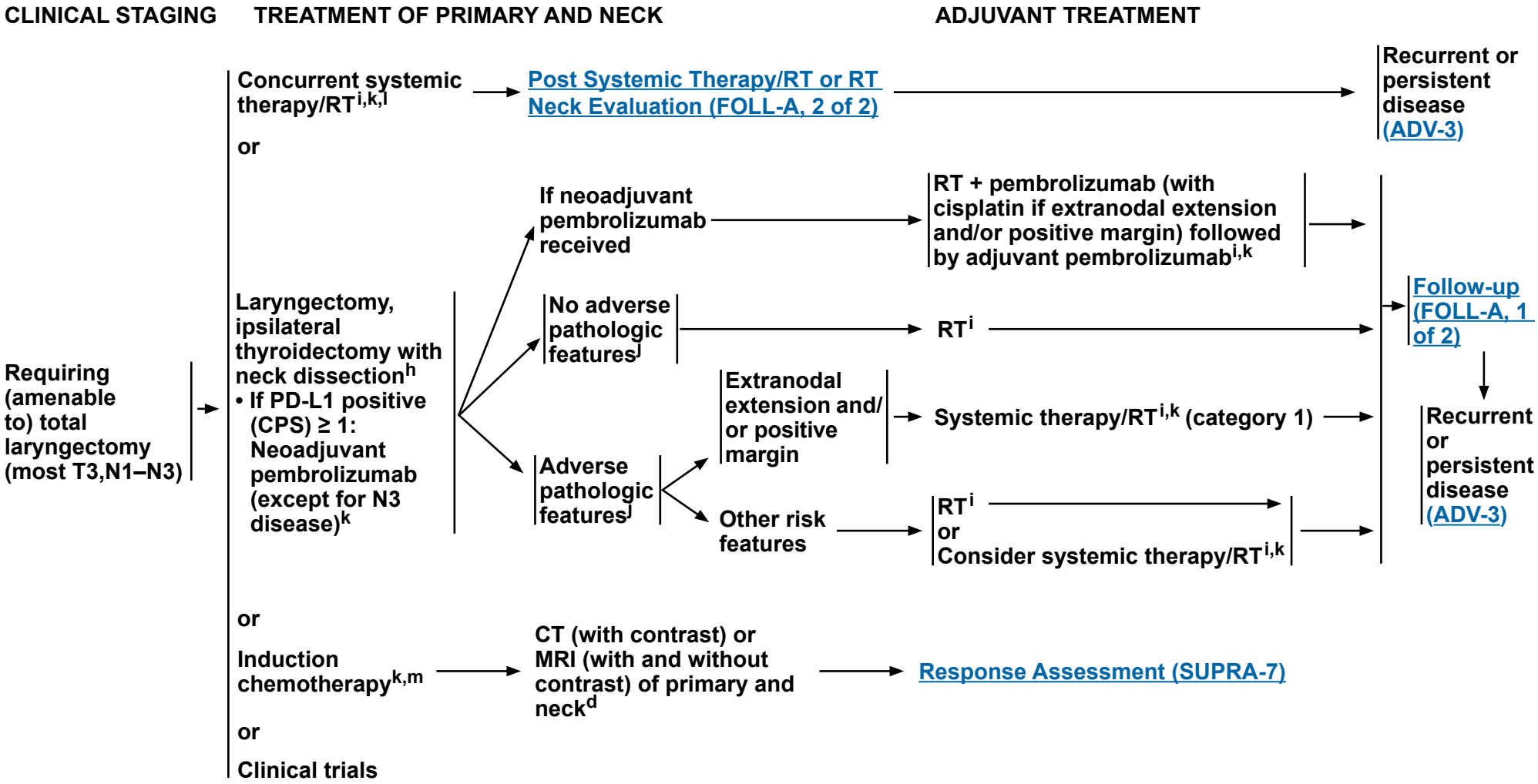

[d] Principles of Imaging (IMG-A).
[h] Principles of Surgery (SURG-A).
[i] Principles of Radiation Therapy (SUPRA-A).
[j] Adverse pathologic features: extranodal extension, positive margins, close margins, pT3 or pT4 primary, pN2 or pN3 nodal disease, perineural invasion, vascular invasion, and lymphatic invasion (Discussion).
[k] Principles of Systemic Therapy for Non-Nasopharyngeal Cancers (SYST-A).
[l] When using concurrent systemic therapy/RT, the preferred agent is cisplatin (category 1). See Principles of Systemic Therapy for Non-Nasopharyngeal Cancers (SYST-A).
[m] See Discussion on induction chemotherapy.

Note: All recommendations are category 2A unless otherwise indicated.

Version 1.2026, 12/08/2025 © 2025 National Comprehensive Cancer Network® (NCCN®), All rights reserved. NCCN Guidelines® and this illustration may not be reproduced in any form without the express written permission of NCCN.

PLEASE NOTE that use of this NCCN Content is governed by the End-User License Agreement, and you MAY NOT distribute this Content or use it with any artificial intelligence model or tool.
Printed by Galya Basol Kochav on 1/4/2026 9:40:35 AM. Copyright © 2026 National Comprehensive Cancer Network, Inc. All Rights Reserved.

RESPONSE ASSESSMENT

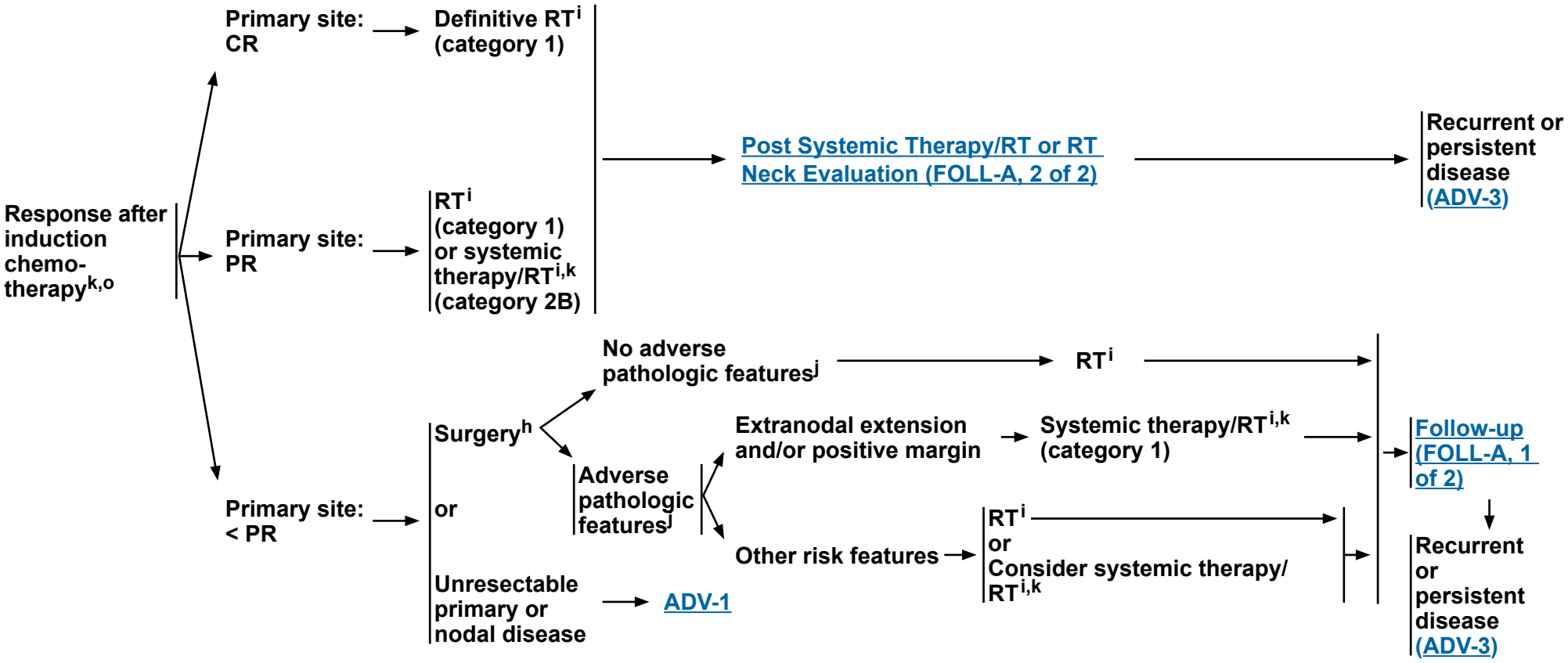

[h] Principles of Surgery (SURG-A).
[i] Principles of Radiation Therapy (SUPRA-A).
[j] Adverse pathologic features: extranodal extension, positive margins, close margins, pT3 or pT4 primary, pN2 or pN3 nodal disease, perineural invasion, vascular invasion, and lymphatic invasion (Discussion).
[k] Principles of Systemic Therapy for Non-Nasopharyngeal Cancers (SYST-A).
[o] In randomized clinical trials, assessment of response has been done after 2 or 3 cycles.

Note: All recommendations are category 2A unless otherwise indicated.

Version 1.2026, 12/08/2025 © 2025 National Comprehensive Cancer Network® (NCCN®), All rights reserved. NCCN Guidelines® and this illustration may not be reproduced in any form without the express written permission of NCCN.

PLEASE NOTE that use of this NCCN Content is governed by the End-User License Agreement, and you MAY NOT distribute this Content or use it with any artificial intelligence model or tool.
Printed by Galya Basol Kochav on 1/4/2026 9:40:35 AM. Copyright © 2026 National Comprehensive Cancer Network, Inc. All Rights Reserved.

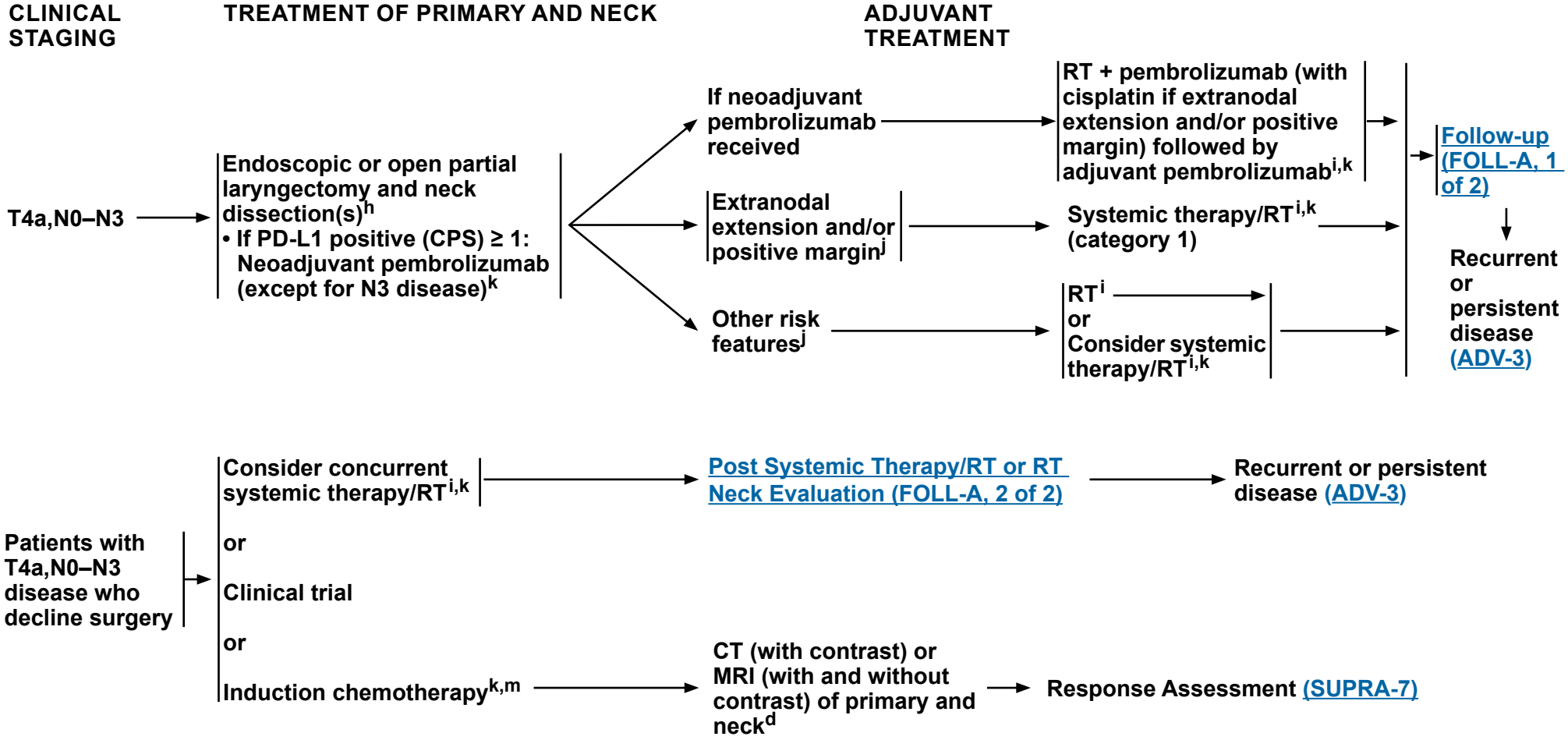

[d] Principles of Imaging (IMG-A).
[h] Principles of Surgery (SURG-A).
[i] Principles of Radiation Therapy (SUPRA-A).

[j] Adverse pathologic features: extranodal extension, positive margins, close margins, pT3 or pT4 primary, pN2 or pN3 nodal disease, perineural invasion, vascular invasion, and lymphatic invasion (Discussion).
[k] Principles of Systemic Therapy for Non-Nasopharyngeal Cancers (SYST-A).
[m] See Discussion on induction chemotherapy.

Note: All recommendations are category 2A unless otherwise indicated.

Version 1.2026, 12/08/2025 © 2025 National Comprehensive Cancer Network® (NCCN®), All rights reserved. NCCN Guidelines® and this illustration may not be reproduced in any form without the express written permission of NCCN.

PLEASE NOTE that use of this NCCN Content is governed by the End-User License Agreement, and you MAY NOT distribute this Content or use it with any artificial intelligence model or tool.
Printed by Galya Basol Kochav on 1/4/2026 9:40:35 AM. Copyright © 2026 National Comprehensive Cancer Network, Inc. All Rights Reserved.

PRINCIPLES OF RADIATION THERAPY[a]

DEFINITIVE:

RT Alone

- **T1–3,N0–1: 66–70 Gy conventional (2.0 Gy/fraction)[b]**
- **PTV**
  - **High risk: Primary tumor and involved lymph nodes (this includes possible local subclinical infiltration at the primary site and at the high-risk level lymph node[s])**
    - **Fractionation: 66 Gy (2.2 Gy/fraction) to 70 Gy (2.0 Gy/fraction); daily Monday–Friday in 6–7 weeks[c]**
    - **Concomitant boost accelerated RT:**
      - **72 Gy/6 weeks (1.8 Gy/fraction, large field; 1.5 Gy boost as second daily fraction during last 12 treatment days)**
      - **66–70 Gy (2.0 Gy/fraction; 6 fractions/wk accelerated)**
    - **Hyperfractionation: 79.2–81.6 Gy/7 weeks (1.2 Gy/fraction twice daily)**
  - **Low to intermediate risk: Sites of suspected subclinical spread**
    - **44–50 Gy (2.0 Gy/fraction) to 54–63 Gy (1.6–1.8 Gy/fraction)[d]**

CONCURRENT SYSTEMIC THERAPY/RT[e,f]:

- **PTV**
  - **High risk: Typically 70 Gy (2.0 Gy/fraction)**
  - **Low to intermediate and low risk: 44–50 Gy (2.0 Gy/fraction) to 54–63 Gy (1.6–1.8 Gy/fraction)[d]**

IMRT (preferred) is recommended. Use of proton therapy is an area of active investigation. Proton therapy may be considered when normal tissue constraints cannot be met by photon-based therapy, or when photon-based therapy causes compromise of standard radiation dosing to tumor or postoperative volumes.

[a] See Principles of Radiation Techniques (RAD-A) and Discussion.
[b] For select T1–2,N0 tumors, accelerated fractionation may be used.
[c] For doses >70 Gy, some clinicians think that the fractionation should be slightly modified (eg, <2.0 Gy/fraction for at least some of the treatment) to minimize toxicity. An additional 2–3 doses can be added depending on clinical circumstances.
[d] Suggest 44–50 Gy in sequentially planned IMRT or 54–63 Gy with IMRT dose painting technique (dependent on dose per fraction).
[e] Principles of Systemic Therapy for Non-Nasopharyngeal Cancers (SYST-A).
[f] Based on published data, concurrent systemic therapy/RT most commonly uses conventional fractionation at 2.0 Gy per fraction to a typical dose of 70 Gy in 7 weeks with single-agent cisplatin given every 3 weeks at 100 mg/m^2; 2–3 cycles of chemotherapy are used depending on the radiation fractionation scheme (RTOG) (Ang KK, Harris J, Wheeler R, et al. Human papillomavirus and survival of patients with oropharyngeal cancer. N Engl J Med 2010;363:24-35). When carboplatin and fluorouracil are used, the recommended regimen is standard fractionation plus 3 cycles of chemotherapy (Bourhis J, Sire C, Graff P, et al. Concomitant chemoradiotherapy versus acceleration of radiotherapy with or without concomitant chemotherapy in locally advanced head and neck carcinoma [GORTEC 99-02]: an open-label phase 3 randomised trial. Lancet Oncol 2012;13:145-153). Other fraction sizes (eg, 1.8 Gy, conventional), multiagent chemotherapy, other dosing schedules of cisplatin, or altered fractionation with chemotherapy are efficacious, and there is no consensus on the optimal approach. In general, the use of concurrent systemic therapy/RT carries a high toxicity burden; multiagent chemotherapy will likely further increase the toxicity burden. For any systemic therapy/RT approach, close attention should be paid to published reports for the specific chemotherapy agent, dose, and schedule of administration. Systemic therapy/RT should be performed by an experienced team and should include substantial supportive care.

Note: All recommendations are category 2A unless otherwise indicated.

Version 1.2026, 12/08/2025 © 2025 National Comprehensive Cancer Network® (NCCN®), All rights reserved. NCCN Guidelines® and this illustration may not be reproduced in any form without the express written permission of NCCN.

PLEASE NOTE that use of this NCCN Content is governed by the End-User License Agreement, and you MAY NOT distribute this Content or use it with any artificial intelligence model or tool.
Printed by Galya Basol Kochav on 1/4/2026 9:40:35 AM. Copyright © 2026 National Comprehensive Cancer Network, Inc. All Rights Reserved.

PRINCIPLES OF RADIATION THERAPY[a]

POSTOPERATIVE:

RT or Concurrent Systemic Therapy/RT[e,1-4]

- **Preferred interval between resection and initiation of postoperative RT is ≤6 weeks.**
- **PTV**
  - **High risk: Adverse pathologic features such as positive margins (see footnote j on SUPRA-3).**
    - **60–66 Gy (2.0 Gy/fraction); daily Monday–Friday in 6–6.5 weeks**
  - **Low to intermediate risk: Sites of suspected subclinical spread**
    - **44–50 Gy (2.0 Gy/fraction) to 54–63 Gy (1.6–1.8 Gy/fraction)[d]**

IMRT (preferred) is recommended. Use of proton therapy is an area of active investigation.
Proton therapy may be considered when normal tissue constraints cannot be met by photon-based therapy, or when photon-based therapy causes compromise of standard radiation dosing to tumor or postoperative volumes.

[a] See Principles of Radiation Techniques (RAD-A) and Discussion.
[d] Suggest 44–50 Gy in sequentially planned IMRT or 54–63 Gy with IMRT dose painting technique (dependent on dose per fraction).
[e] Principles of Systemic Therapy for Non-Nasopharyngeal Cancers (SYST-A).

[1] Bernier J, Domenge C, Ozsahin M, et al. Postoperative irradiation with or without concomitant chemotherapy for locally advanced head and neck cancer. N Engl J Med 2004;350:1945-1952.
[2] Cooper JS, Pajak TF, Forastiere AA, et al. Postoperative concurrent radiotherapy and chemotherapy for high-risk squamous-cell carcinoma of the head and neck. N Engl J Med 2004;350:1937-1944.
[3] Bernier J, Cooper JS, Pajak TF, et al. Defining risk levels in locally advanced head and neck cancers: A comparative analysis of concurrent postoperative radiation plus chemotherapy trials of the EORTC (#22931) and RTOG (#9501). Head Neck 2005;27:843-850.
[4] Cooper JS, Zhang Q, Pajak TF, et al. Long-term follow-up of the RTOG 9501/intergroup phase III trial: postoperative concurrent radiation therapy and chemotherapy in high-risk squamous cell carcinoma of the head and neck. Int J Radiat Oncol Biol Phys 2012;84:1198-1205.

Note: All recommendations are category 2A unless otherwise indicated.

Version 1.2026, 12/08/2025 © 2025 National Comprehensive Cancer Network® (NCCN®), All rights reserved. NCCN Guidelines® and this illustration may not be reproduced in any form without the express written permission of NCCN.

PLEASE NOTE that use of this NCCN Content is governed by the End-User License Agreement, and you MAY NOT distribute this Content or use it with any artificial intelligence model or tool.
Printed by Galya Basol Kochav on 1/4/2026 9:40:35 AM. Copyright © 2026 National Comprehensive Cancer Network, Inc. All Rights Reserved.

WORKUP

- H&P[a,b] including a complete head and neck exam; nasal endoscopy as clinically indicated
- CT with contrast or MRI with and without contrast of skull base and neck[c]
- HPV testing (may inform etiology)
- As clinically indicated:
  - Chest CT (with or without contrast)[c]
  - Consider FDG-PET/CT[c]
  - Dental evaluation[d]
  - Nutrition, speech, and swallowing evaluation/therapy[e]
  - Smoking cessation counseling[a]
  - Fertility/reproductive counseling[f]
  - Screening for hepatitis B
- Multidisciplinary consultation as clinically indicated

→ Biopsy[g]

PATHOLOGY

- Squamous cell carcinoma
- Adenocarcinoma
- Minor salivary gland tumor[h]
- Esthesioneuroblastoma
- Undifferentiated carcinoma (sinonasal undifferentiated carcinoma [SNUC], small cell, or sinonasal neuroendocrine carcinoma [SNEC])[i]

→ Newly diagnosed T1–T4,M0 disease → Primary Treatment (ETHM-2)

→ Diagnosed after incomplete resection (eg, polypectomy) → Primary Treatment (ETHM-3)

→ Metastatic (M1) disease at initial presentation → Treatment of Very Advanced Head and Neck Cancer (ADV-2)

Mucosal melanoma (MM-1)

Sarcoma (See NCCN Guidelines for Soft Tissue Sarcoma)

Lymphoma (See NCCN Guidelines for B-Cell Lymphomas and NCCN Guidelines for T-Cell Lymphomas)

[a] H&P should include documentation and quantification (pack years smoked) of tobacco use history, as well as alcohol use and counseling. All patients who currently smoke should be advised to quit smoking, and those who formerly smoked should be advised to remain abstinent from smoking. For additional cessation support, refer to the Smoking Cessation and Treatment Resources in the NCCN Guidelines for Smoking Cessation.
[b] Screen for distress. Refer to the NCCN Distress Thermometer and Problem List, which includes social determinants of health. See NCCN Guidelines for Distress Management (DIS-A).
[c] Principles of Imaging (IMG-A).
[d] Principles of Oral/Dental Evaluation and Management (DENT-A).
[e] Principles of Nutrition: Management and Supportive Care (NUTR-A).
[f] See fertility and reproductive endocrine considerations in the NCCN Guidelines for Adolescent and Young Adult (AYA) Oncology.
[g] Image-guided (US or CT) needle biopsy of cystic neck nodes may offer better diagnostic yield than FNA by palpation alone for initial diagnosis in this setting. For unresectable or metastatic disease where there is a plan for systemic therapy, a core biopsy would allow for biomarker testing.
[h] See the salivary gland algorithm for management after resection. See NCCN Guidelines for Salivary Gland Tumors (SALI-1).
[i] Ethmoid sinus tumors are rare and histopathologically diverse. Correct pathologic diagnosis is paramount to treatment decisions. Consider referral to a major medical center that specializes in these tumors for confirmation of diagnosis.

Note: All recommendations are category 2A unless otherwise indicated.

Version 1.2026, 12/08/2025 © 2025 National Comprehensive Cancer Network® (NCCN®), All rights reserved. NCCN Guidelines® and this illustration may not be reproduced in any form without the express written permission of NCCN.

PLEASE NOTE that use of this NCCN Content is governed by the End-User License Agreement, and you MAY NOT distribute this Content or use it with any artificial intelligence model or tool.
Printed by Galya Basol Kochav on 1/4/2026 9:40:35 AM. Copyright © 2026 National Comprehensive Cancer Network, Inc. All Rights Reserved.

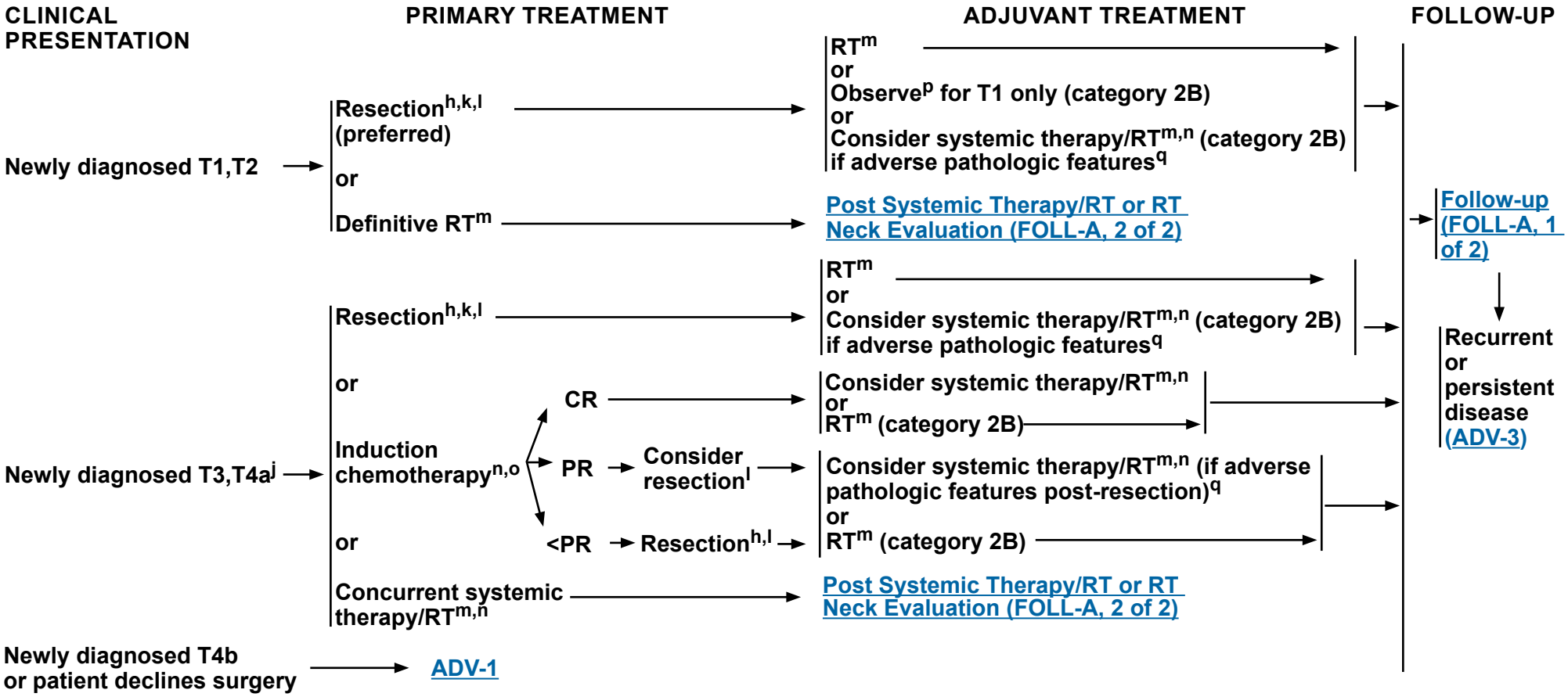

[h] See the salivary gland algorithm for management after resection. See NCCN Guidelines for Salivary Gland Tumors (SALI-1).
[j] For SNUC with neuroendocrine features, small cell, high-grade olfactory esthesioneuroblastoma, or SNEC histologies, systemic therapy should be a part of the overall treatment. Consider a clinical trial and referral to a major medical center that specializes in these diseases. See SYST-A.
[k] N+ neck disease is uncommon in ethmoid cancers, but, if present, requires neck dissection and appropriate risk-based adjuvant therapy.
[l] Principles of Surgery (SURG-A).
[m] Principles of Radiation Therapy (ETHM-A). For minor salivary gland tumors, see SALI-A.
[n] Principles of Systemic Therapy for Non-Nasopharyngeal Cancers (SYST-A).
[o] Nonsurgical RT-based treatment is an option in selected patients with disease that has a major response to induction therapy short of a CR.
[p] Pathologic features: negative margins, favorable histology (including low grade), not located along the cribriform plate or medial wall of the orbit, no perineural invasion, and lymphovascular space invasion.
[q] Adverse pathologic features: positive margins, close margins (tumors adjacent to the cribriform plate and/or medial wall of the orbit), unfavorable histology (ie, adenoid cystic, high-grade tumors), intracranial and/or intraorbital extension, cribriform plate location, medial wall of orbit location, perineural invasion, and lymphovascular space invasion (Discussion).

Note: All recommendations are category 2A unless otherwise indicated.

Version 1.2026, 12/08/2025 © 2025 National Comprehensive Cancer Network® (NCCN®), All rights reserved. NCCN Guidelines® and this illustration may not be reproduced in any form without the express written permission of NCCN.

PLEASE NOTE that use of this NCCN Content is governed by the End-User License Agreement, and you MAY NOT distribute this Content or use it with any artificial intelligence model or tool.
Printed by Galya Basol Kochav on 1/4/2026 9:40:35 AM. Copyright © 2026 National Comprehensive Cancer Network, Inc. All Rights Reserved.

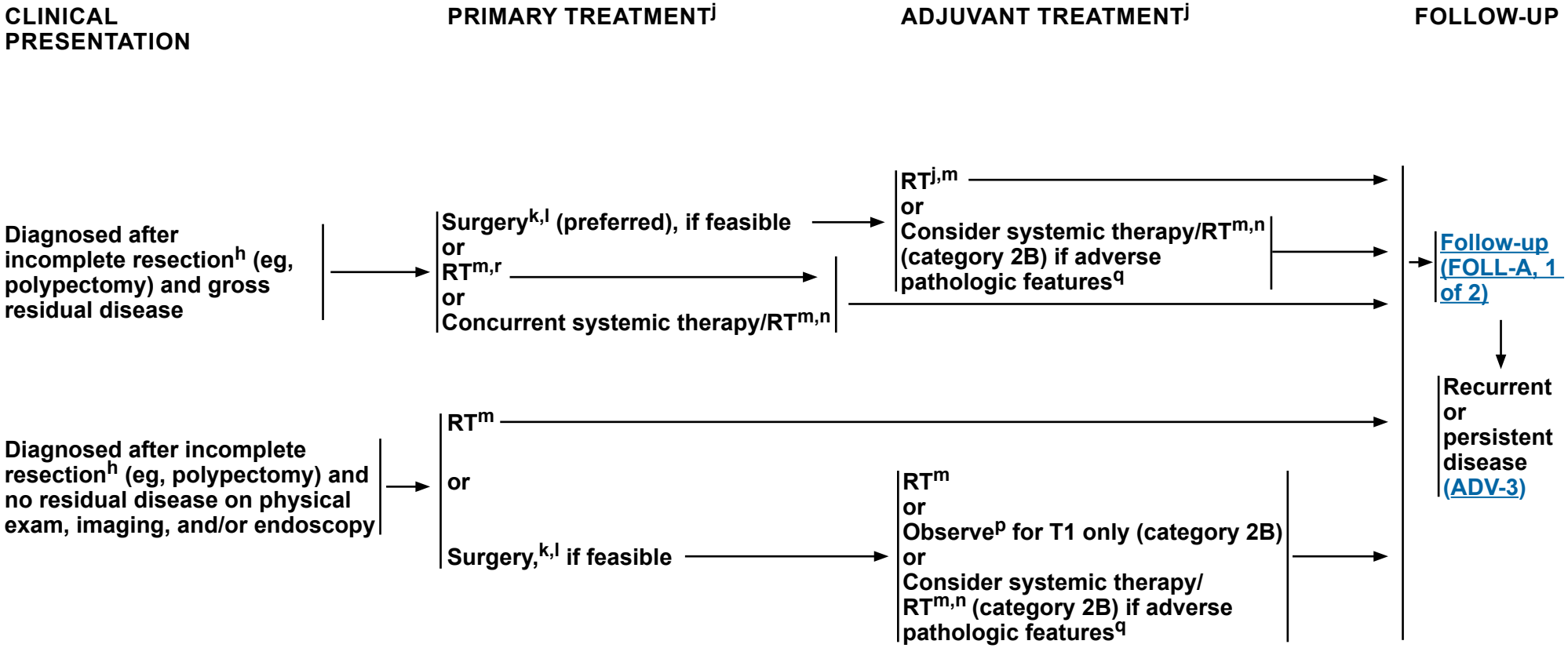

[h] See the salivary gland algorithm for management after resection. See NCCN Guidelines for Salivary Gland Tumors (SALI-1).
[j] For SNUC with neuroendocrine features, small cell, high-grade olfactory esthesioneuroblastoma, or SNEC histologies, systemic therapy should be a part of the overall treatment. Consider a clinical trial and referral to a major medical center that specializes in these diseases. See SYST-A.
[k] N+ neck disease is uncommon in ethmoid cancers, but, if present, requires neck dissection and appropriate risk-based adjuvant therapy.
[l] Principles of Surgery (SURG-A).
[m] Principles of Radiation Therapy (ETHM-A). For minor salivary gland tumors, see SALI-A.
[n] Principles of Systemic Therapy for Non-Nasopharyngeal Cancers (SYST-A).
[p] Pathologic features: negative margins, favorable histology (including low grade), not located along the cribriform plate or medial wall of the orbit, no perineural invasion, and lymphovascular space invasion.
[q] Adverse pathologic features: positive margins, close margins (tumors adjacent to the cribriform plate and/or medial wall of the orbit), unfavorable histology (ie, adenoid cystic, high-grade tumors), intracranial and/or intraorbital extension, cribriform plate location, medial wall of orbit location, perineural invasion, and lymphovascular space invasion (Discussion).
[r] Primary RT is an option for minimal residual squamous cell carcinoma.

Note: All recommendations are category 2A unless otherwise indicated.

Version 1.2026, 12/08/2025 © 2025 National Comprehensive Cancer Network® (NCCN®), All rights reserved. NCCN Guidelines® and this illustration may not be reproduced in any form without the express written permission of NCCN.

PLEASE NOTE that use of this NCCN Content is governed by the End-User License Agreement, and you MAY NOT distribute this Content or use it with any artificial intelligence model or tool.
Printed by Galya Basol Kochav on 1/4/2026 9:40:35 AM. Copyright © 2026 National Comprehensive Cancer Network, Inc. All Rights Reserved.

PRINCIPLES OF RADIATION THERAPY[a]

DEFINITIVE:

RT Alone

- **PTV**
  - **High risk: Primary tumor and involved lymph nodes (this includes possible local subclinical infiltration at the primary site and at the high-risk level lymph node[s])**
    - **Fractionation:**
      - **66 Gy (2.2 Gy/fraction) to 70–70.2 Gy (1.8–2.0 Gy/fraction); daily Monday–Friday in 6–8 weeks[b,c]**
      - **Concomitant boost accelerated RT:**
        - **72 Gy/6 weeks (2 Gy once daily and then 1.8 Gy/fraction, large field; 1.5 Gy boost as second daily fraction during last 12 treatment days)**
        - **66–70 Gy (2.0 Gy/fraction; 6 fractions/wk accelerated)**
      - **Hyperfractionation: 81.6 Gy/7 weeks (1.2 Gy/fraction, twice daily)**
  - **Low to intermediate risk: Sites of suspected subclinical spread**
    - **44–50 Gy (2.0 Gy/fraction) to 54–63 Gy (1.6–1.8 Gy/fraction)[d,e]**

CONCURRENT SYSTEMIC THERAPY/RT[f]:

- **PTV**
  - **High risk: Typically 70–70.2 Gy (1.8–2.0 Gy/fraction); daily Monday–Friday in 7–8 weeks[b]**
  - **Low to intermediate risk: 44–50 Gy (2.0 Gy/fraction) to 54–63 Gy (1.6–1.8 Gy/fraction)[d,e]**

POSTOPERATIVE:

RT or Concurrent Systemic Therapy/RT[f]

- **Preferred interval between resection and initiation of postoperative RT is ≤6 weeks**
- **PTV**
  - **High risk: Adverse pathologic features such as positive margins[g]**
    - **60–66 Gy (1.8–2.0 Gy/fraction); daily Monday–Friday in 6–6.5 weeks[b]**
  - **Low to intermediate risk: Sites of suspected subclinical spread**
    - **44–50 Gy (2.0 Gy/fraction) to 54–63 Gy (1.6–1.8 Gy/fraction)[d,e]**

Either IMRT or proton therapy is recommended for maxillary sinus or paranasal/ethmoid sinus tumors to minimize dose to critical structures.

[a] See Principles of Radiation Techniques (RAD-A) and Discussion.
[b] In the paranasal sinus area, care should be taken to avoid critical neural structures; therefore, 1.8 Gy/fraction can be considered.
[c] For doses >70 Gy, some clinicians think that the fractionation should be slightly modified (eg, <2.0 Gy/fraction for at least some of the treatment) to minimize toxicity. An additional 2–3 doses can be added depending on clinical circumstances.
[d] Suggest 44–50 Gy in sequentially planned IMRT or 54–63 Gy with IMRT dose painting technique (dependent on dose per fraction).
[e] Treatment to sites of suspected subclinical spread is not consistently performed at all institutions (Le QT, Fu KK, Kaplan MJ, et al. Lymph node metastasis in maxillary sinus carcinoma. Int J Radiat Oncol Biol Phys 2000;46:541-549).
[f] Principles of Systemic Therapy for Non-Nasopharyngeal Cancers (SYST-A).
[g] Adverse pathologic features: positive margins, close margins (tumors adjacent to the cribriform plate and/or medial wall of the orbit), unfavorable histology (ie, adenoid cystic, high-grade tumors), intracranial and/or intraorbital extension, cribriform plate location, medial wall of orbit location, perineural invasion, and lymphovascular space invasion (Discussion).

Note: All recommendations are category 2A unless otherwise indicated.

Version 1.2026, 12/08/2025 © 2025 National Comprehensive Cancer Network® (NCCN®), All rights reserved. NCCN Guidelines® and this illustration may not be reproduced in any form without the express written permission of NCCN.

PLEASE NOTE that use of this NCCN Content is governed by the End-User License Agreement, and you MAY NOT distribute this Content or use it with any artificial intelligence model or tool.
Printed by Galya Basol Kochav on 1/4/2026 9:40:35 AM. Copyright © 2026 National Comprehensive Cancer Network, Inc. All Rights Reserved.

WORKUP

- H&P[a,b] including a complete head and neck exam; nasal endoscopy as clinically indicated
- Complete head and neck CT with contrast and/or MRI with and without contrast[c]
- As clinically indicated:
  - Chest CT (with or without contrast)[c]
  - Consider FDG-PET/CT[c]
  - Dental/prosthodontic evaluation[d]
  - Nutrition, speech, and swallowing evaluation/therapy[e]
  - Smoking cessation counseling[a]
  - Fertility/reproductive counseling[f]
  - Screening for hepatitis B
- Multidisciplinary consultation as clinically indicated

→ Biopsy[g]

PATHOLOGY

- Squamous cell carcinoma
- Adenocarcinoma
- Minor salivary gland tumor[h]
- Esthesioneuroblastoma
- Undifferentiated carcinoma (SNUC, small cell, or SNEC)[i]

→ T1–2,N0 All histologies → Primary Treatment (MAXI-2)

→ T3–4a,N0; T1–4a,N+ All histologies → Primary Treatment (MAXI-3)

→ T4b,N0–3 → Treatment of Very Advanced Head and Neck Cancer (ADV-1)

→ Metastatic disease at initial presentation → Treatment of Very Advanced Head and Neck Cancer (ADV-2)

→ Mucosal melanoma (MM-1)

→ Sarcoma (See NCCN Guidelines for Soft Tissue Sarcoma)

→ Lymphoma (See NCCN Guidelines for B-Cell Lymphomas and NCCN Guidelines for T-Cell Lymphomas)

[a] H&P should include documentation and quantification (pack years smoked) of tobacco use history, as well as alcohol use and counseling. All patients who currently smoke should be advised to quit smoking, and those who formerly smoked should be advised to remain abstinent from smoking. For additional cessation support, refer to the Smoking Cessation and Treatment Resources in the NCCN Guidelines for Smoking Cessation.
[b] Screen for distress. Refer to the NCCN Distress Thermometer and Problem List, which includes social determinants of health. See NCCN Guidelines for Distress Management (DIS-A).
[c] Principles of Imaging (IMG-A).
[d] Principles of Oral/Dental Evaluation and Management (DENT-A).
[e] Principles of Nutrition: Management and Supportive Care (NUTR-A).
[f] See fertility and reproductive endocrine considerations in the NCCN Guidelines for Adolescent and Young Adult (AYA) Oncology
[g] Biopsy:
- Preferred route is transnasal.
- Needle biopsy may be acceptable.
- Avoid canine fossa puncture or Caldwell-Luc approach.

[h] See the salivary gland algorithm for management after resection. See Salivary Gland Tumors (SALI-1).
[i] Maxillary sinus tumors are rare and histopathologically diverse. Correct pathologic diagnosis is paramount to treatment decisions. Consider referral to a major medical center that specializes in these tumors for confirmation of diagnosis.

Note: All recommendations are category 2A unless otherwise indicated.

Version 1.2026, 12/08/2025 © 2025 National Comprehensive Cancer Network® (NCCN®), All rights reserved. NCCN Guidelines® and this illustration may not be reproduced in any form without the express written permission of NCCN.

PLEASE NOTE that use of this NCCN Content is governed by the End-User License Agreement, and you MAY NOT distribute this Content or use it with any artificial intelligence model or tool.
Printed by Galya Basol Kochav on 1/4/2026 9:40:35 AM. Copyright © 2026 National Comprehensive Cancer Network, Inc. All Rights Reserved.

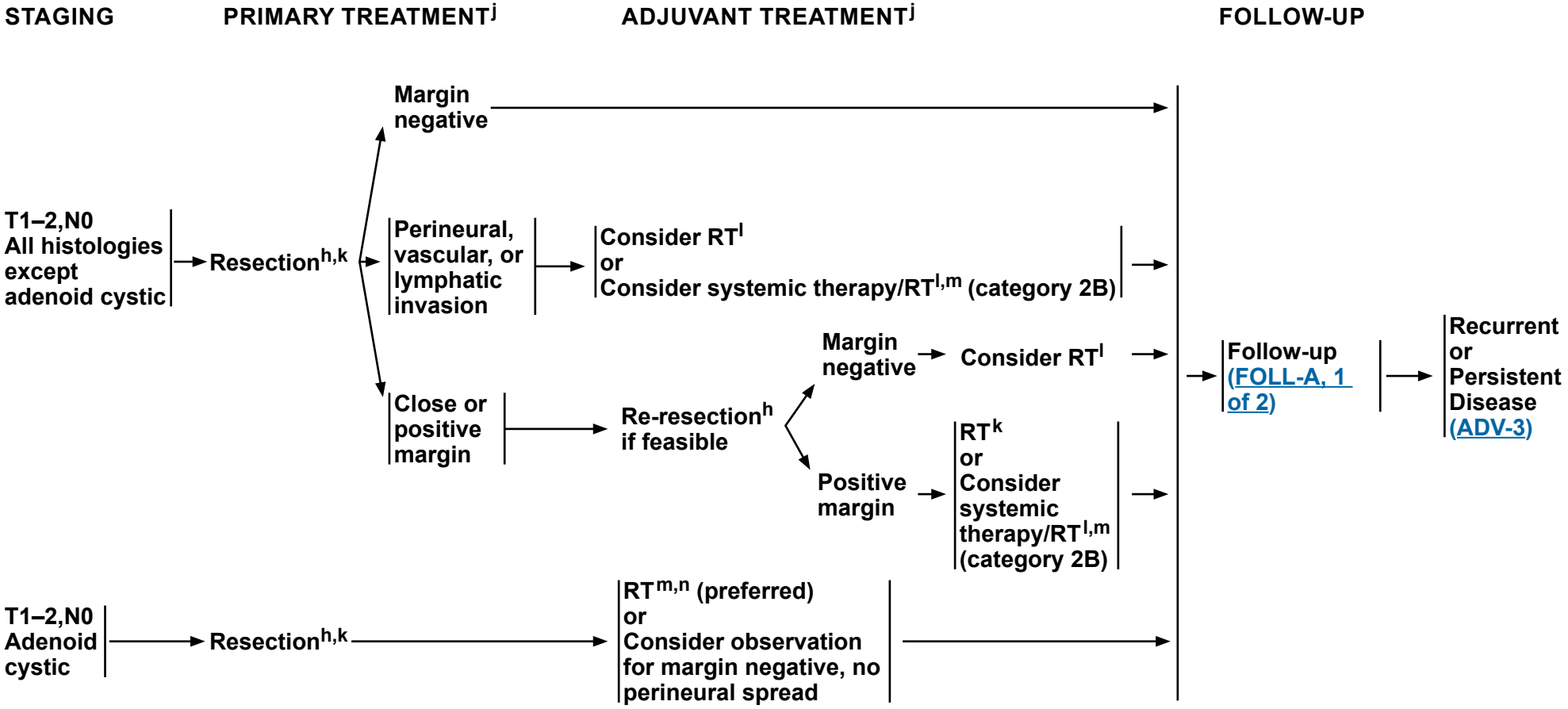

[h] See the salivary gland algorithm for management after resection. See Salivary Gland Tumors (SALI-1).

[j] For SNUC with neuroendocrine features, small cell, high-grade olfactory esthesioneuroblastoma, or SNEC histologies, systemic therapy should be a part of the overall treatment. Consider a clinical trial and referral to a major medical center that specializes in these diseases. See SYST-A.

[k] Principles of Surgery (SURG-A).

[l] Principles of Radiation Therapy (MAXI-A).

[m] Principles of Systemic Therapy for Non-Nasopharyngeal Cancers (SYST-A).

[n] For adenoid cystic tumors and minor salivary gland tumors, see SALI-A.

Note: All recommendations are category 2A unless otherwise indicated.

Version 1.2026, 12/08/2025 © 2025 National Comprehensive Cancer Network® (NCCN®), All rights reserved. NCCN Guidelines® and this illustration may not be reproduced in any form without the express written permission of NCCN.

PLEASE NOTE that use of this NCCN Content is governed by the End-User License Agreement, and you MAY NOT distribute this Content or use it with any artificial intelligence model or tool.
Printed by Galya Basol Kochav on 1/4/2026 9:40:35 AM. Copyright © 2026 National Comprehensive Cancer Network, Inc. All Rights Reserved.

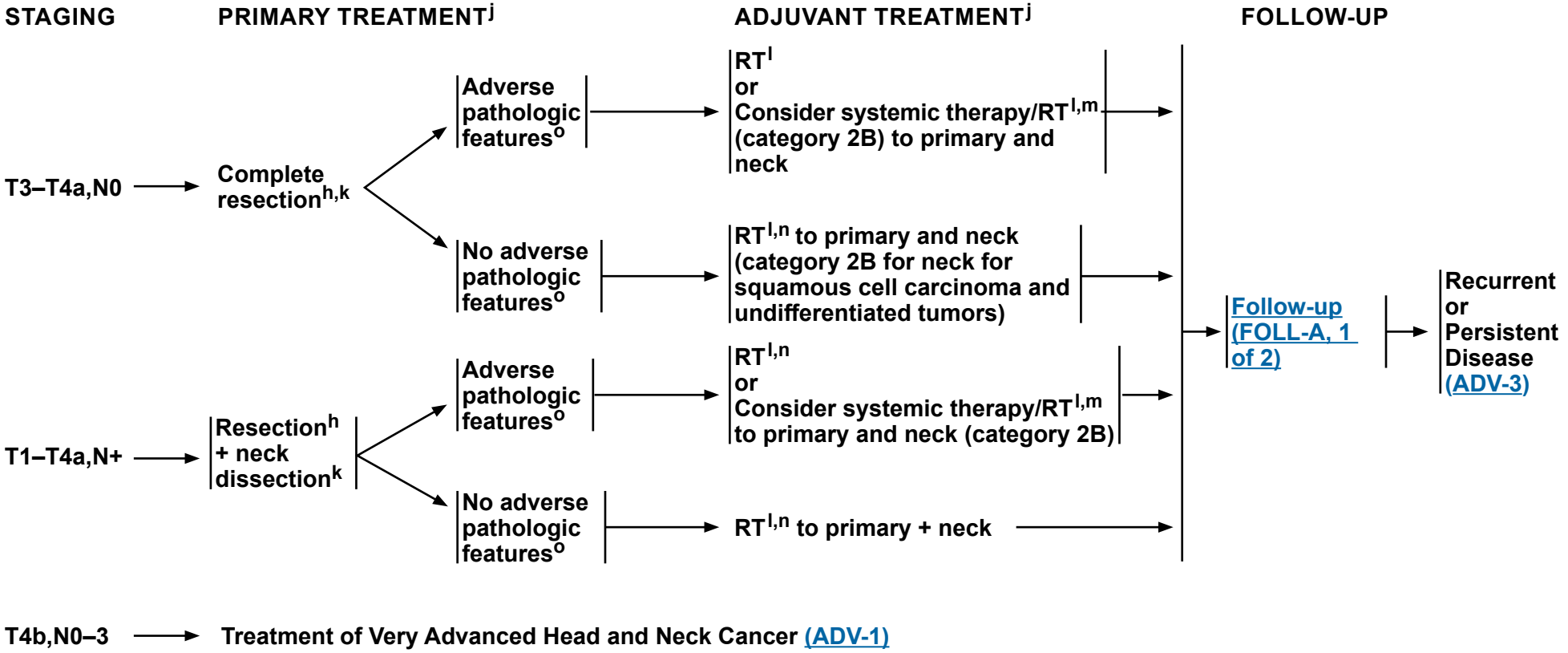

[h] See the salivary gland algorithm for management after resection. See Salivary Gland Tumors (SALI-1).
[j] For SNUC with neuroendocrine features, small cell, high-grade olfactory esthesioneuroblastoma, or SNEC histologies, systemic therapy should be a part of the overall treatment. Consider a clinical trial and referral to a major medical center that specializes in these diseases. See SYST-A.
[k] Principles of Surgery (SURG-A).
[l] Principles of Radiation Therapy (MAXI-A).
[m] Principles of Systemic Therapy for Non-Nasopharyngeal Cancers (SYST-A).
[n] For adenoid cystic tumors and minor salivary gland tumors, see SALI-A.
[o] Adverse pathologic features: positive margins, close margins, or extranodal extension (Discussion).

Note: All recommendations are category 2A unless otherwise indicated.

Version 1.2026, 12/08/2025 © 2025 National Comprehensive Cancer Network® (NCCN®), All rights reserved. NCCN Guidelines® and this illustration may not be reproduced in any form without the express written permission of NCCN.

PLEASE NOTE that use of this NCCN Content is governed by the End-User License Agreement, and you MAY NOT distribute this Content or use it with any artificial intelligence model or tool.
Printed by Galya Basol Kochav on 1/4/2026 9:40:35 AM. Copyright © 2026 National Comprehensive Cancer Network, Inc. All Rights Reserved.

PRINCIPLES OF RADIATION THERAPY[a]

DEFINITIVE:

RT Alone

- **PTV**
  - **High risk: Primary tumor and involved lymph nodes (this includes possible local subclinical infiltration at the primary site and at the high-risk level lymph node[s])**
    - ◊ **Fractionation:**
      - – **66 Gy (2.2 Gy/fraction) to 70–70.2 Gy (1.8–2.0 Gy/fraction) daily Monday–Friday in 6–8 weeks[b,c]**
      - – **Concomitant boost accelerated RT:**
        - ▪ **72 Gy/6 weeks (2 Gy once daily and then 1.8 Gy/fraction, large field; 1.5 Gy boost as second daily fraction during last 12 treatment days)**
        - ▪ **66–70 Gy (2.0 Gy/fraction; 6 fractions/wk accelerated)**
      - – **Hyperfractionation: 81.6 Gy/7 weeks (1.2 Gy/fraction, twice daily)**
  - **Low to intermediate risk: Sites of suspected subclinical spread**
    - ◊ **44–50 Gy (2.0 Gy/fraction) to 54–63 Gy (1.6–1.8 Gy/fraction)[d,e]**

CONCURRENT SYSTEMIC THERAPY/RT[f]:

- **PTV**
  - **High risk: Typically 70–70.2 Gy (1.8–2.0 Gy/fraction); daily Monday–Friday in 7 weeks[b]**
  - **Low to intermediate risk: 44–50 Gy (2.0 Gy/fraction) to 54–63 Gy (1.6–1.8 Gy/fraction)[d,e]**

POSTOPERATIVE:

RT or Concurrent Systemic Therapy/RT[f]

- **Preferred interval between resection and initiation of postoperative RT is ≤6 weeks**
- **PTV**
  - **High risk: Adverse pathologic features such as positive margins (see footnote o on MAXI-3)**
    - ◊ **60–66 Gy (1.8–2.0 Gy/fraction); daily Monday–Friday in 6–6.5 weeks[b]**
  - **Low to intermediate risk: Sites of suspected subclinical spread**
    - ◊ **44–50 Gy (2.0 Gy/fraction) to 54–63 Gy (1.6–1.8 Gy/fraction)[d,e]**

Either IMRT or proton therapy is recommended for maxillary sinus or paranasal/ethmoid sinus tumors to minimize dose to critical structures.

[a] See Principles of Radiation Techniques (RAD-A) and Discussion.
[b] In the paranasal sinus area, care should be taken to avoid critical neural structures; therefore, 1.8 Gy/fraction can be considered.
[c] For doses >70 Gy, some clinicians think that the fractionation should be slightly modified (eg, <2.0 Gy/fraction for at least some of the treatment) to minimize toxicity. An additional 2–3 doses can be added depending on clinical circumstances
[d] Suggest 44–50 Gy in sequentially planned IMRT or 54–63 Gy with IMRT dose painting technique (dependent on dose per fraction).
[e] Treatment to sites of suspected subclinical spread is not consistently performed at all institutions (Le QT, Fu KK, Kaplan MJ, et al. Lymph node metastasis in maxillary sinus carcinoma. Int J Radiat Oncol Biol Phys 2000;46:541-549; Jeremic B, Nguyen-Tan PF, Bamberg M. Elective neck irradiation in locally advanced squamous cell carcinoma of the maxillary sinus: a review. J Cancer Res Clin Oncol 2002;128:235-238).
[f] Principles of Systemic Therapy for Non-Nasopharyngeal Cancers (SYST-A).

Note: All recommendations are category 2A unless otherwise indicated.

Version 1.2026, 12/08/2025 © 2025 National Comprehensive Cancer Network® (NCCN®), All rights reserved. NCCN Guidelines® and this illustration may not be reproduced in any form without the express written permission of NCCN.

PLEASE NOTE that use of this NCCN Content is governed by the End-User License Agreement, and you MAY NOT distribute this Content or use it with any artificial intelligence model or tool.
Printed by Galya Basol Kochav on 1/4/2026 9:40:35 AM. Copyright © 2026 National Comprehensive Cancer Network, Inc. All Rights Reserved.

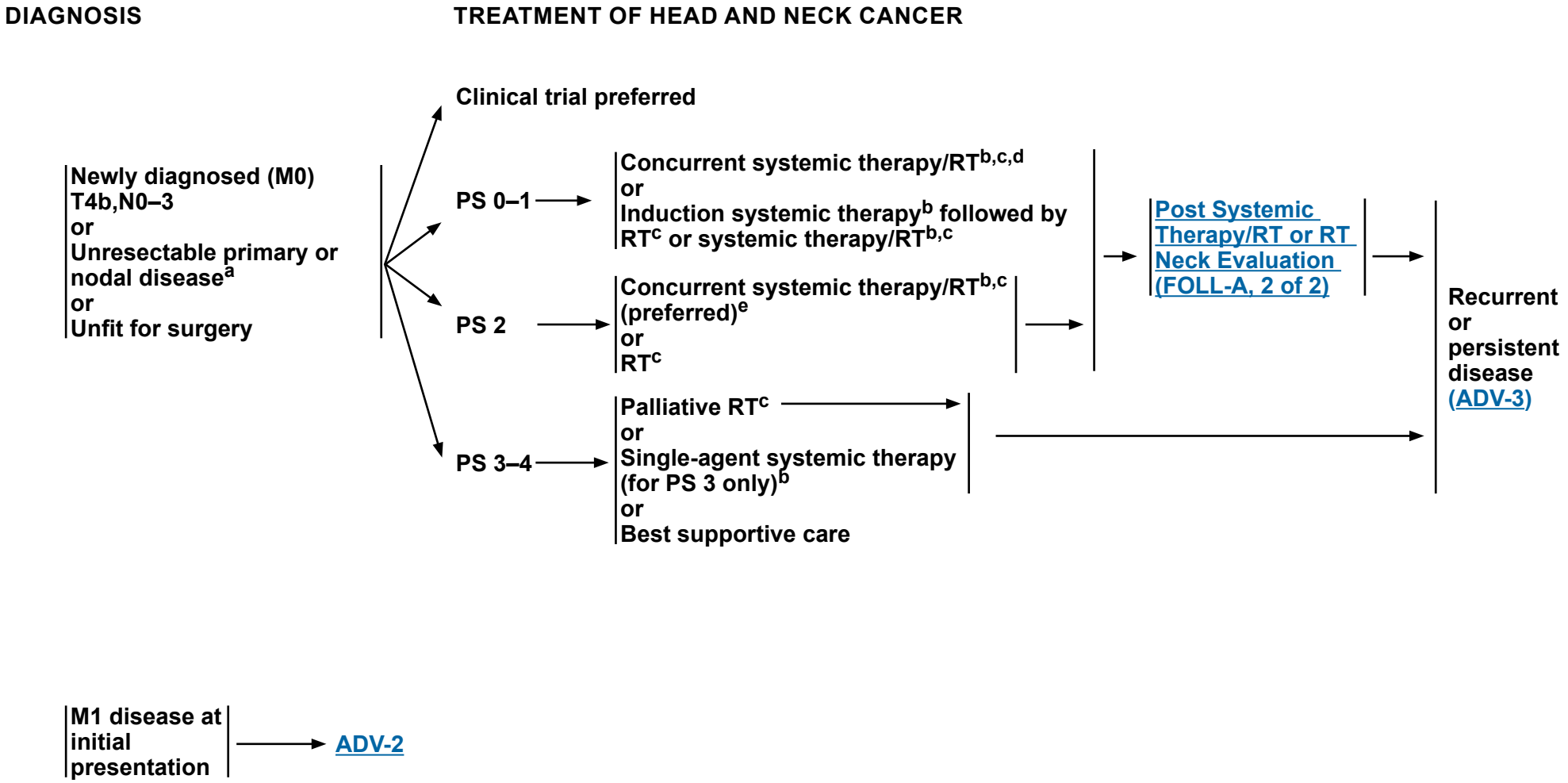

[a] If no prior RT.
[b] Principles of Systemic Therapy for Non-Nasopharyngeal Cancers (SYST-A).
[c] Principles of Radiation Therapy (ADV-A).
[d] When using concurrent systemic therapy/RT, the preferred agent is cisplatin (category 1). See Principles of Systemic Therapy for Non-Nasopharyngeal Cancers (SYST-A).
[e] Patil VM, Noronha V, Menon N, et al. Results of phase III randomized trial for use of docetaxel as a radiosensitizer in patients with head and neck cancer, unsuitable for cisplatin-based chemoradiation. J Clin Oncol 2023;41:2350-2361.

Note: All recommendations are category 2A unless otherwise indicated.

PLEASE NOTE that use of this NCCN Content is governed by the End-User License Agreement, and you MAY NOT distribute this Content or use it with any artificial intelligence model or tool.
Printed by Galya Basol Kochav on 1/4/2026 9:40:35 AM. Copyright © 2026 National Comprehensive Cancer Network, Inc. All Rights Reserved.

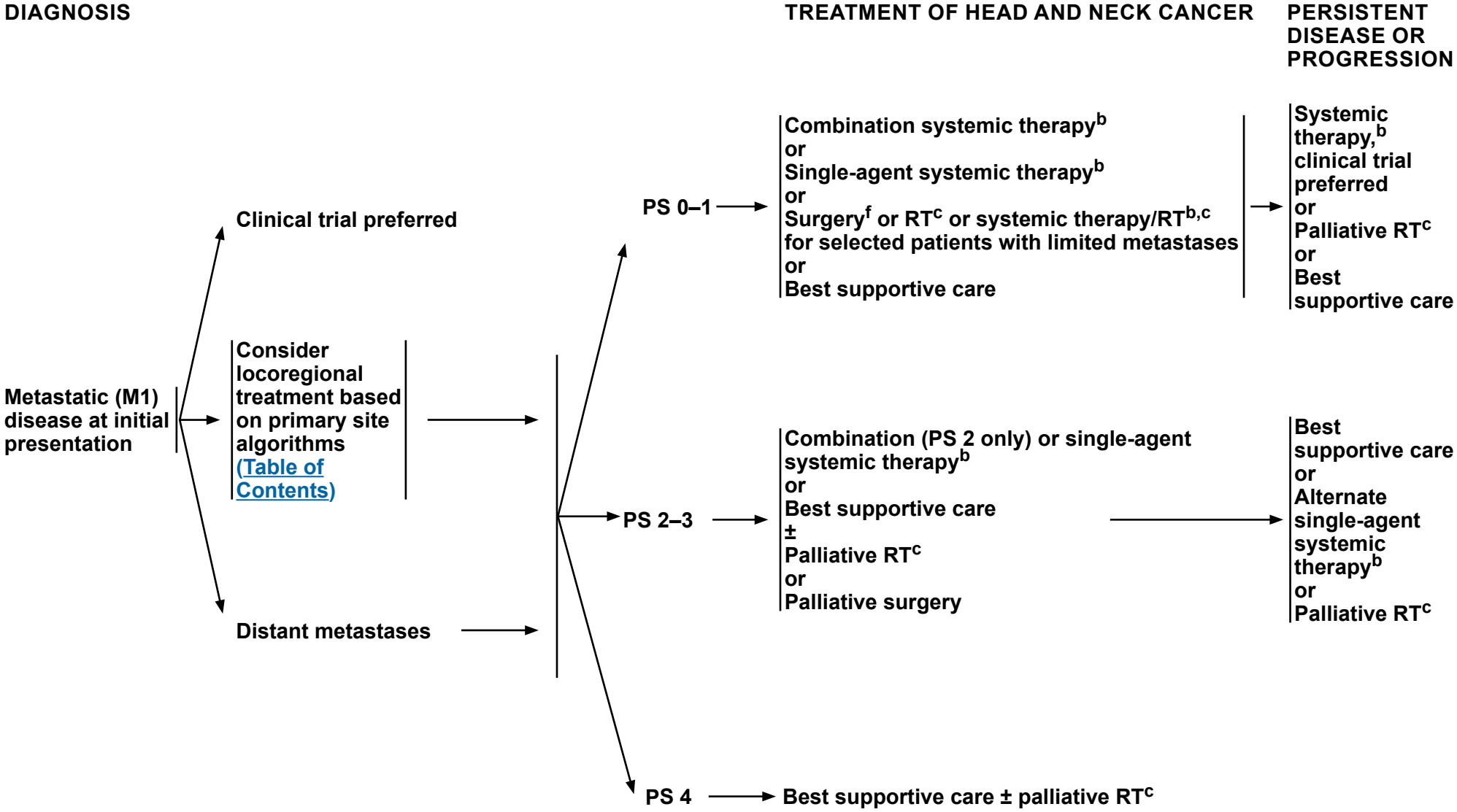

[b] Principles of Systemic Therapy for Non-Nasopharyngeal Cancers (SYST-A).
[c] Principles of Radiation Therapy (ADV-A).
[f] Principles of Surgery (SURG-A).

Note: All recommendations are category 2A unless otherwise indicated.

Version 1.2026, 12/08/2025 © 2025 National Comprehensive Cancer Network® (NCCN®), All rights reserved. NCCN Guidelines® and this illustration may not be reproduced in any form without the express written permission of NCCN.

PLEASE NOTE that use of this NCCN Content is governed by the End-User License Agreement, and you MAY NOT distribute this Content or use it with any artificial intelligence model or tool.
Printed by Galya Basol Kochav on 1/4/2026 9:40:35 AM. Copyright © 2026 National Comprehensive Cancer Network, Inc. All Rights Reserved.

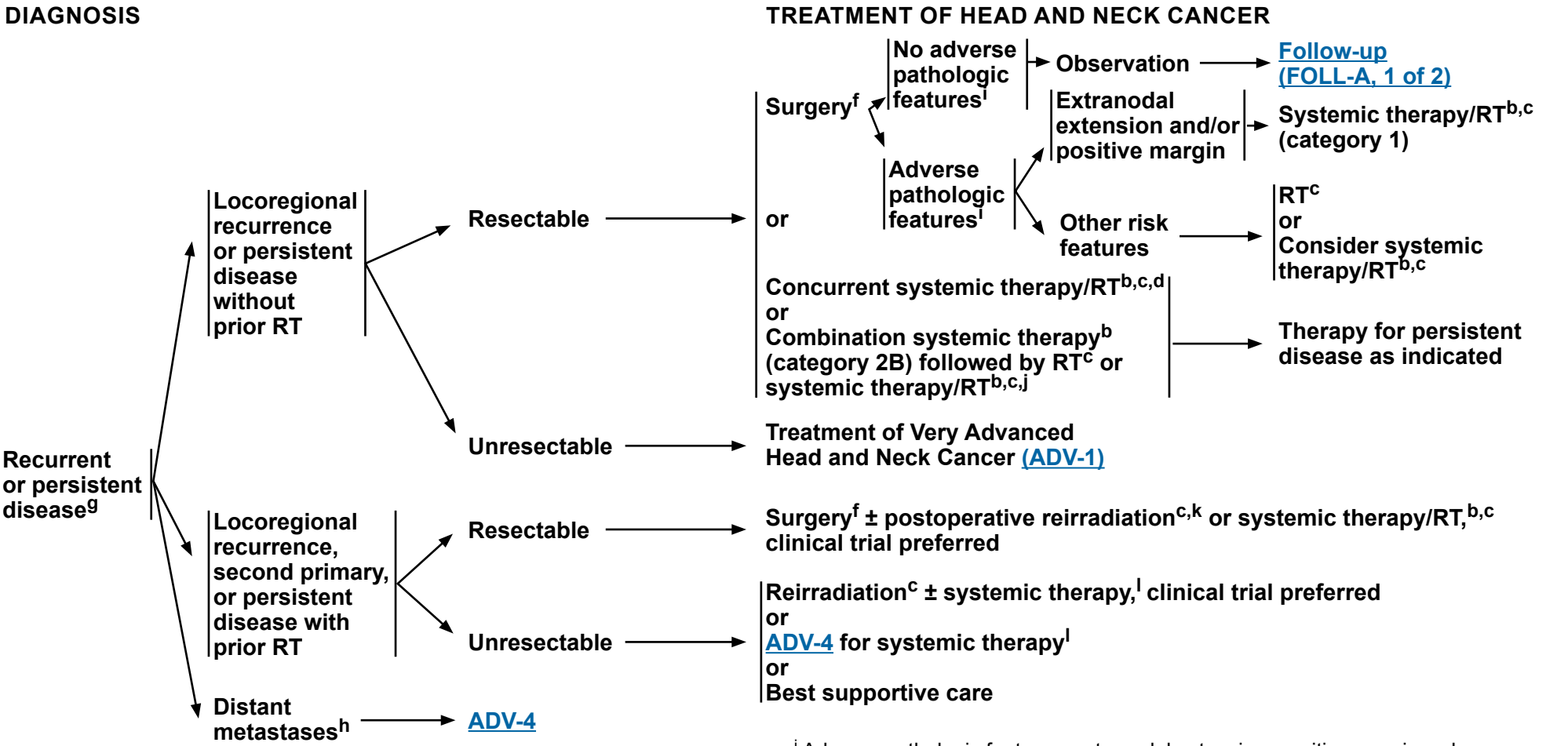

[b] Principles of Systemic Therapy for Non-Nasopharyngeal Cancers (SYST-A).
[c] Principles of Radiation Therapy (ADV-A).
[d] When using concurrent systemic therapy/RT, the preferred agent is cisplatin (category 1). See Principles of Systemic Therapy for Non-Nasopharyngeal Cancers (SYST-A).
[f] Principles of Surgery (SURG-A).
[g] Consider MGPT for biomarker identification.
[h] Consider palliative RT as clinically indicated (eg, bone metastases) (RAD-A).

[i] Adverse pathologic features: extranodal extension, positive margins, close margins, pT3 or pT4 primary, pN2 or pN3 nodal disease, perineural invasion, vascular invasion, and lymphatic invasion (Discussion).
[j] Combination systemic therapy followed by RT or systemic therapy/RT may be considered for cytoreduction or symptom control followed by local therapy as indicated.
[k] Reirradiation should be limited to a highly select subset of patients (Janot F, et al. J Clin Oncol 2008;26:5518-5523).
[l] See Principles of Systemic Therapy for Non-Nasopharyngeal Cancers (SYST-A) or Systemic Therapy for Nasopharyngeal Cancers (NASO-B).

Note: All recommendations are category 2A unless otherwise indicated.

PLEASE NOTE that use of this NCCN Content is governed by the End-User License Agreement, and you MAY NOT distribute this Content or use it with any artificial intelligence model or tool.
Printed by Galya Basol Kochav on 1/4/2026 9:40:35 AM. Copyright © 2026 National Comprehensive Cancer Network, Inc. All Rights Reserved.

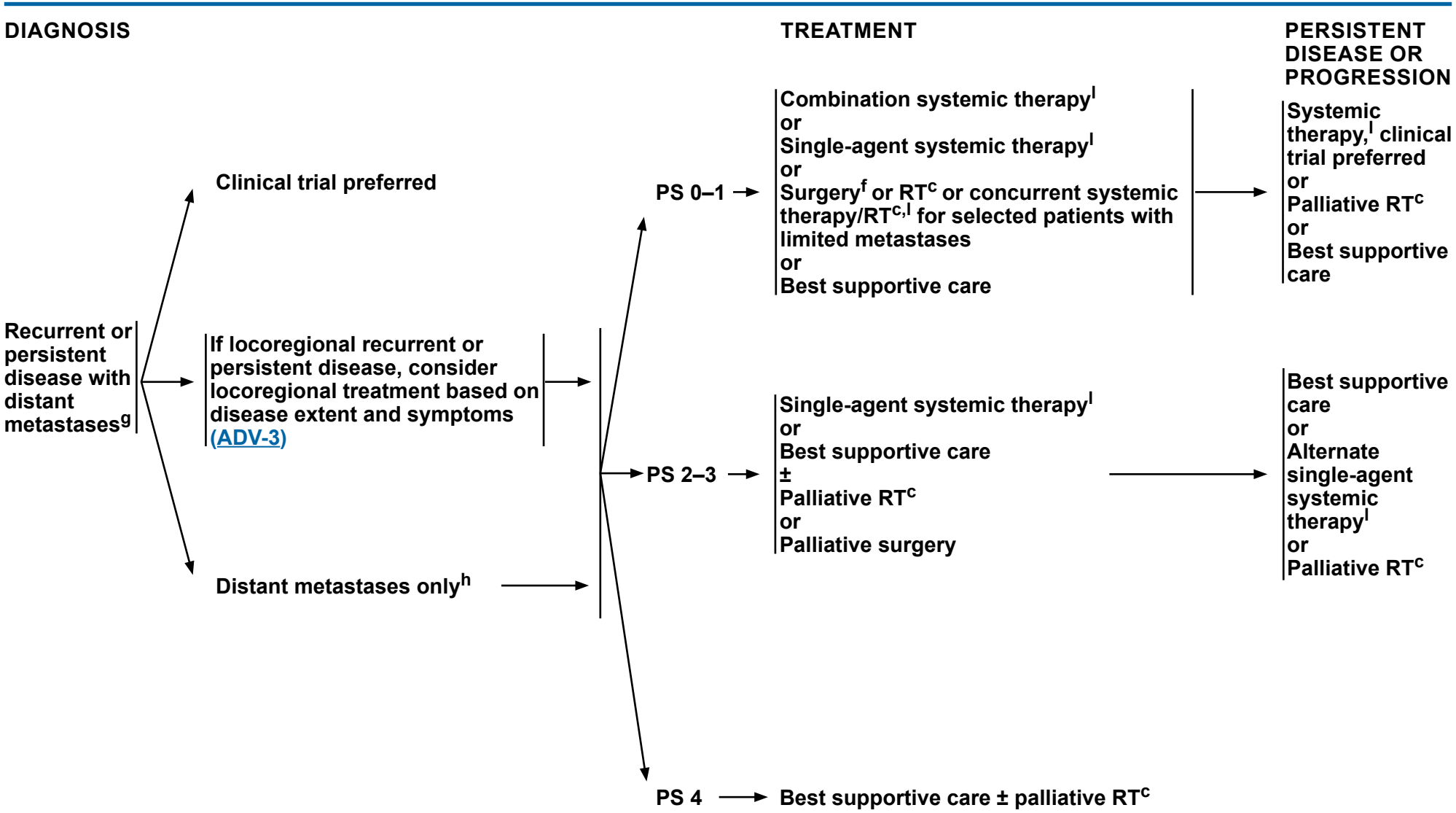

[c] Principles of Radiation Therapy (ADV-A).
[f] Principles of Surgery (SURG-A).
[g] Consider MGPT for biomarker identification.
[h] Consider palliative RT as clinically indicated (eg, bone metastases) (RAD-A).
[l] See Principles of Systemic Therapy for Non-Nasopharyngeal Cancers (SYST-A) or Systemic Therapy for Nasopharyngeal Cancers (NASO-B).

Note: All recommendations are category 2A unless otherwise indicated.

Version 1.2026, 12/08/2025 © 2025 National Comprehensive Cancer Network® (NCCN®), All rights reserved. NCCN Guidelines® and this illustration may not be reproduced in any form without the express written permission of NCCN.

PLEASE NOTE that use of this NCCN Content is governed by the End-User License Agreement, and you MAY NOT distribute this Content or use it with any artificial intelligence model or tool.
Printed by Galya Basol Kochav on 1/4/2026 9:40:35 AM. Copyright © 2026 National Comprehensive Cancer Network, Inc. All Rights Reserved.

PRINCIPLES OF RADIATION THERAPY[a,b]

CONCURRENT SYSTEMIC THERAPY/RT[c] (PREFERRED FOR PATIENTS ELIGIBLE FOR CHEMOTHERAPY):

- **PTV**
  - **High risk: Typically 70 Gy (2.0 Gy/fraction)**
  - **Low to intermediate risk: Sites of suspected subclinical spread**
    - **44–50 Gy (2.0 Gy/fraction) to 54–63 Gy (1.6–1.8 Gy/fraction)[d]**

SYSTEMIC THERAPY/RT[c]:

Based on published data, concurrent systemic therapy/RT most commonly uses conventional fractionation at 2.0 Gy per fraction to a typical dose of 70 Gy in 7 weeks with single-agent cisplatin given every 3 weeks at 100 mg/m^2; 2–3 cycles of chemotherapy are used depending on the radiation fractionation scheme (RTOG 0129) (Ang KK, Harris J, Wheeler R, et al. Human papillomavirus and survival of patients with oropharyngeal cancer. N Engl J Med 2010;363:24-35). When carboplatin and fluorouracil are used, then the recommended regimen is standard fractionation plus 3 cycles of chemotherapy (Bourhis J, Sire C, Graff P, et al. Concomitant chemoradiotherapy versus acceleration of radiotherapy with or without concomitant chemotherapy in locally advanced head and neck carcinoma [GORTEC 99-02]: an open-label phase 3 randomised trial. Lancet Oncol 2012;13:145-53). Other fraction sizes (eg, 1.8 Gy, conventional), multiagent chemotherapy, other dosing schedules of cisplatin, or altered fractionation with chemotherapy are efficacious, and there is no consensus on the optimal approach.[1] Data indicate that accelerated fractionation does not offer improved efficacy over conventional fractionation.[2,3] In general, the use of concurrent systemic therapy/RT carries a high toxicity burden; multiagent chemotherapy will likely further increase the toxicity burden. For any systemic therapy/RT approach, close attention should be paid to published reports for the specific chemotherapy agent, dose, and schedule of administration. Systemic therapy/RT should be performed by an experienced team and should include substantial supportive care.

[a] See Principles of Radiation Techniques (RAD-A) and Discussion.

[b] In general, the reirradiated population of patients with head and neck cancer described in current literature represents a diverse but highly selected group of patients treated in centers where there is a high level of expertise and systems in place for managing acute and long-term toxicities. When the goal of treatment is curative and surgery is not an option, reirradiation strategies can be considered for patients who: develop locoregional recurrent or persistent disease or second primaries at ≥6 months after the initial radiotherapy; can receive additional doses of radiotherapy of at least 60 Gy; and can tolerate concurrent chemotherapy. Organs at risk (OARs) for toxicity should be carefully analyzed through review of dose-volume histograms, and consideration for acceptable doses should be made on the basis of time interval since original radiotherapy, anticipated volumes to be included, and patient's life expectancy. For reirradiation dosing, see Principles of Radiation Techniques (RAD-A). Proton therapy can be considered when normal tissue constraints cannot be met by photon-based therapy, or when photon-based therapy causes compromise of standard radiation dosing to tumor or postoperative volumes (Takiar V, Garden AS, Ma D, et al. Reirradiation of head and neck cancers with intensity modulated radiation therapy: Outcomes and analyses. Int J Radiat Oncol Biol Phys 2016;95:1117-1131.)

[c] Principles of Systemic Therapy for Non-Nasopharyngeal Cancers (SYST-A).

[d] Suggest 44–50 Gy and sequentially planned IMRT or 54–63 Gy with IMRT dose painting technique (dependent on dose per fraction).

[1] RTOG 0522: a randomized phase III trial of concurrent accelerated radiation and cisplatin versus concurrent accelerated radiation, cisplatin, and cetuximab (followed by surgery for selected patients) for stage III and IV head and neck carcinomas. Clin Adv Hematol Oncol 2007;5:79-81.

[2] Ang K, Zhang Q, Wheeler RH, et al. A phase III trial (RTOG 0129) of two radiation-cisplatin regimens for head and neck carcinomas (HNC): Impact of radiation and cisplatin intensity on outcome [abstract]. J Clin Oncol 2010;28(Suppl):Abstract 5507.

[3] Bourhis J, Sire C, Graff P, et al. Concomitant chemoradiotherapy versus acceleration of radiotherapy with or without concomitant chemotherapy in locally advanced head and neck carcinoma (GORTEC 99-02): an open-label phase 3 randomised trial. Lancet Oncol 2012;13:145-153.

Note: All recommendations are category 2A unless otherwise indicated.

Version 1.2026, 12/08/2025 © 2025 National Comprehensive Cancer Network® (NCCN®), All rights reserved. NCCN Guidelines® and this illustration may not be reproduced in any form without the express written permission of NCCN.

PLEASE NOTE that use of this NCCN Content is governed by the End-User License Agreement, and you MAY NOT distribute this Content or use it with any artificial intelligence model or tool.
Printed by Galya Basol Kochav on 1/4/2026 9:40:35 AM. Copyright © 2026 National Comprehensive Cancer Network, Inc. All Rights Reserved.

PRINCIPLES OF RADIATION THERAPY[a,b]

DEFINITIVE:

RT Alone

- **PTV**
  - **High risk: Primary tumor and involved lymph nodes (this includes possible local subclinical infiltration at the primary site and at the high-risk level lymph node[s])**
    - **Fractionation:**
      - **70–72 Gy (2.0 Gy/fraction) daily Monday–Friday in 7–7.5 weeks[e]**
      - **Concomitant boost accelerated RT:**
        - **72 Gy/6 weeks (1.8 Gy/fraction, large field; 1.5 Gy boost as second daily fraction during last 12 treatment days)**
        - **66–70 Gy (2.0 Gy/fraction; 6 fractions/wk accelerated)**
      - **Hyperfractionation: 81.6 Gy/7 weeks (1.2 Gy/fraction, twice daily)**
      - **Modified fractionation: total dose >70 Gy and treatment course <7 weeks**
  - **Low to intermediate risk: Sites of suspected subclinical spread**
    - **44–50 Gy (2.0 Gy/fraction) to 54–63 Gy (1.6–1.8 Gy/fraction)[d]**

IMRT (preferred) is recommended.

POSTOPERATIVE:

RT or Concurrent Systemic Therapy/RT[c,4-6]

- **Preferred interval between resection and initiation of postoperative RT is ≤6 weeks.**
- **PTV**
  - **High risk: Adverse pathologic features such as positive margins (see footnote g on ADV-3)**
    - **60–66 Gy (2.0 Gy/fraction); daily Monday–Friday in 6–6.5 weeks**
  - **Low to intermediate risk: Sites of suspected subclinical spread**
    - **44–50 Gy (2.0 Gy/fraction) to 54–63 Gy (1.6–1.8 Gy/fraction)[d]**

[a] See Principles of Radiation Techniques (RAD-A) and Discussion.

[b] In general, the reirradiated population of patients with head and neck cancer described in current literature represents a diverse but highly selected group of patients treated in centers where there is a high level of expertise and systems in place for managing acute and long-term toxicities. When the goal of treatment is curative and surgery is not an option, reirradiation strategies can be considered for patients who: develop locoregional recurrent or persistent disease or second primaries at ≥6 months after the initial radiotherapy; can receive additional doses of radiotherapy of at least 60 Gy; and can tolerate concurrent chemotherapy. OARs for toxicity should be carefully analyzed through review of dose-volume histograms, and consideration for acceptable doses should be made on the basis of time interval since original radiotherapy, anticipated volumes to be included, and patient's life expectancy. For reirradiation dosing, see Principles of Radiation Techniques (RAD-A). Proton therapy can be considered when normal tissue constraints cannot be met by photon-based therapy, or when photon-based therapy causes compromise of standard radiation dosing to tumor or postoperative volumes (Takiar V, Garden AS, Ma D, et al. Reirradiation of head and neck cancers with intensity modulated radiation therapy: Outcomes and analyses. Int J Radiat Oncol Biol Phys 2016;95:1117-1131).

[c] Principles of Systemic Therapy for Non-Nasopharyngeal Cancers (SYST-A).

[d] Suggest 44–50 Gy in sequentially planned IMRT or 54–63 Gy with IMRT dose painting technique (dependent on dose per fraction).

[e] For doses >70 Gy, some clinicians think that the fractionation should be slightly modified (eg, <2.0 Gy/fraction for at least some of the treatment) to minimize toxicity. An additional 2–3 doses can be added depending on clinical circumstances.

[4] Bernier J, Domenge C, Ozsahin M, et al. Postoperative irradiation with or without concomitant chemotherapy for locally advanced head and neck cancer. N Engl J Med 2004;350:1945-1952.

[5] Cooper JS, Pajak TF, Forastiere AA, et al. Postoperative concurrent radiotherapy and chemotherapy for high-risk squamous-cell carcinoma of the head and neck. N Engl J Med 2004;350:1937-1944.

[6] Bernier J, Cooper JS, Pajak TF, et al. Defining risk levels in locally advanced head and neck cancers: A comparative analysis of concurrent postoperative radiation plus chemotherapy trials of the EORTC (#22931) and RTOG (#9501). Head Neck 2005;27:843-850.

Note: All recommendations are category 2A unless otherwise indicated.

Version 1.2026, 12/08/2025 © 2025 National Comprehensive Cancer Network® (NCCN®), All rights reserved. NCCN Guidelines® and this illustration may not be reproduced in any form without the express written permission of NCCN.

PLEASE NOTE that use of this NCCN Content is governed by the End-User License Agreement, and you MAY NOT distribute this Content or use it with any artificial intelligence model or tool.
Printed by Galya Basol Kochav on 1/4/2026 9:40:35 AM. Copyright © 2026 National Comprehensive Cancer Network, Inc. All Rights Reserved.

NCCN Guidelines Version 1.2026
Occult Primary

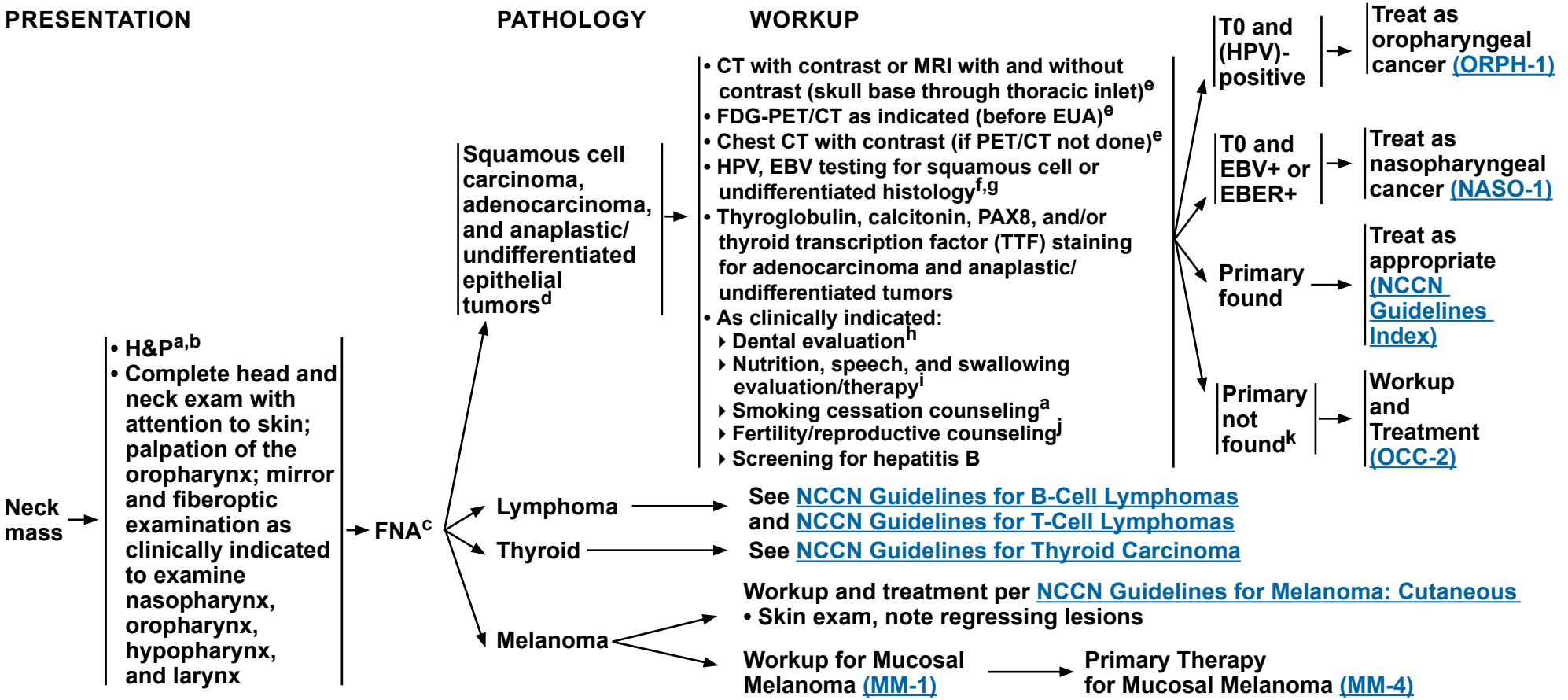

[a] H&P should include documentation and quantification (pack years smoked) of tobacco use history, as well as alcohol use and counseling. All patients who currently smoke should be advised to quit smoking, and those who formerly smoked should be advised to remain abstinent from smoking. For additional cessation support, refer to the Smoking Cessation and Treatment Resources in the NCCN Guidelines for Smoking Cessation.

[b] Screen for distress. Refer to the NCCN Distress Thermometer and Problem List, which includes social determinants of health. See NCCN Guidelines for Distress Management (DIS-A).

[c] Repeat FNA, core, or open biopsy may be necessary for uncertain or non-diagnostic histologies. Patient should be prepared for neck dissection at time of open biopsy, if indicated.

[d] Determined with appropriate immunohistochemical stains.

[e] Principles of Imaging (IMG-A).

[f] Whether HPV or EBV positive status may help to define the radiation fields is being investigated (see Principles of Radiation Therapy [OCC-A] and Discussion).

[g] p16+ unknown primary disease should only be considered HPV-positive with HPV-specific testing.

[h] Principles of Oral/Dental Evaluation and Management (DENT-A).

[i] Principles of Nutrition: Management and Supportive Care (NUTR-A).

[j] See fertility and reproductive endocrine considerations in the NCCN Guidelines for Adolescent and Young Adult (AYA) Oncology.

[k] Strongly consider referral to a high-volume, multidisciplinary cancer center.

Note: All recommendations are category 2A unless otherwise indicated.

Version 1.2026, 12/08/2025 © 2025 National Comprehensive Cancer Network® (NCCN®), All rights reserved. NCCN Guidelines® and this illustration may not be reproduced in any form without the express written permission of NCCN.

PLEASE NOTE that use of this NCCN Content is governed by the End-User License Agreement, and you MAY NOT distribute this Content or use it with any artificial intelligence model or tool.
Printed by Galya Basol Kochav on 1/4/2026 9:40:35 AM. Copyright © 2026 National Comprehensive Cancer Network, Inc. All Rights Reserved.

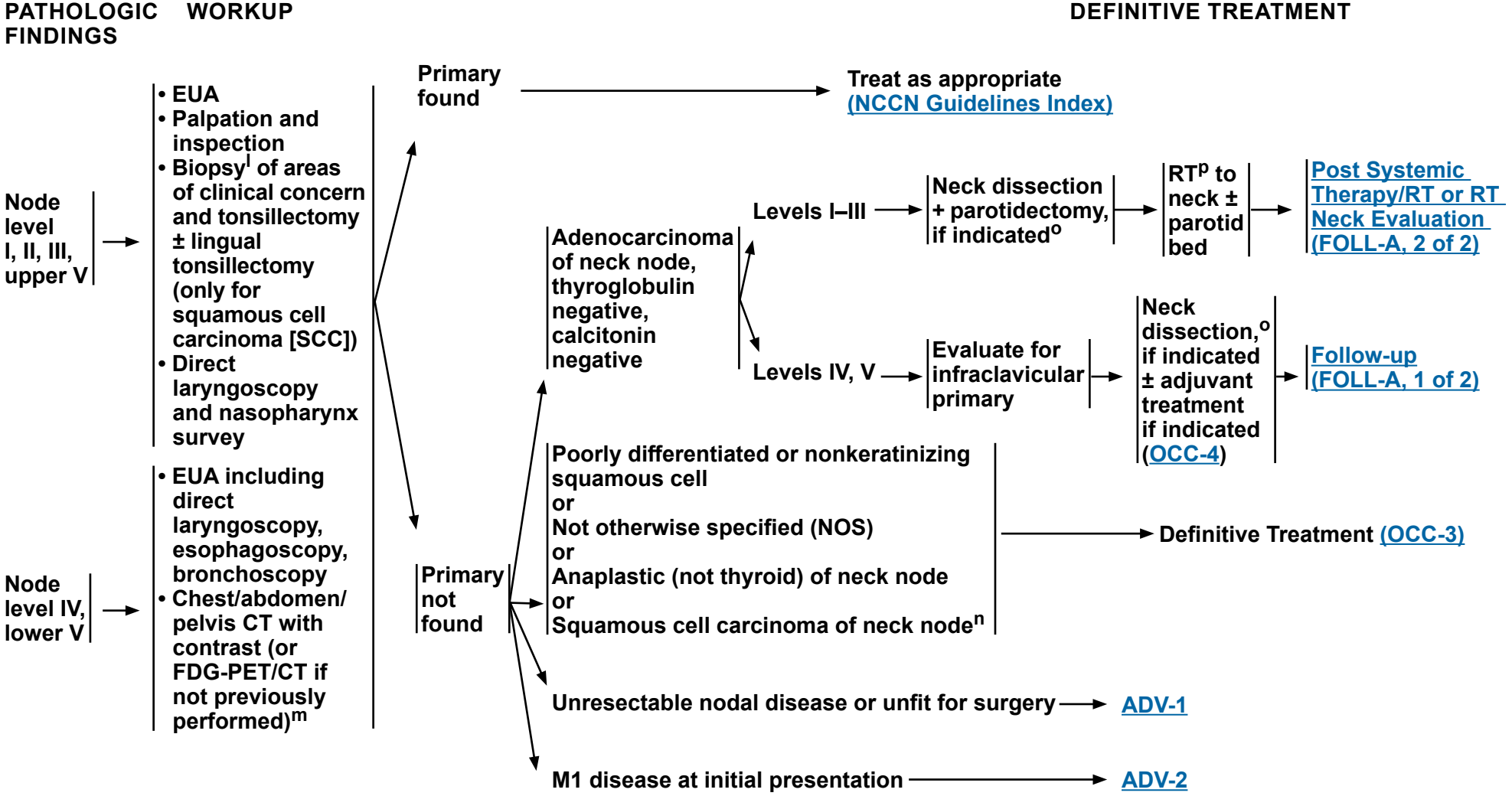

[l] Image-guided (US or CT) needle biopsy of cystic neck nodes may offer better diagnostic yield than FNA by palpation alone for initial diagnosis in this setting. For unresectable or metastatic disease where there is a plan for systemic therapy, a core biopsy would allow for ancillary biomarker testing.
[m] Principles of Imaging (IMG-A).
[n] HPV and EBV testing are suggested if not yet done. If HPV positive, see ORPH-1. If EBV positive, see NASO-1.
[o] Principles of Surgery (SURG-A).
[p] Principles of Radiation Therapy (OCC-A).

Note: All recommendations are category 2A unless otherwise indicated.

Version 1.2026, 12/08/2025 © 2025 National Comprehensive Cancer Network® (NCCN®), All rights reserved. NCCN Guidelines® and this illustration may not be reproduced in any form without the express written permission of NCCN.

PLEASE NOTE that use of this NCCN Content is governed by the End-User License Agreement, and you MAY NOT distribute this Content or use it with any artificial intelligence model or tool.
Printed by Galya Basol Kochav on 1/4/2026 9:40:35 AM. Copyright © 2026 National Comprehensive Cancer Network, Inc. All Rights Reserved.

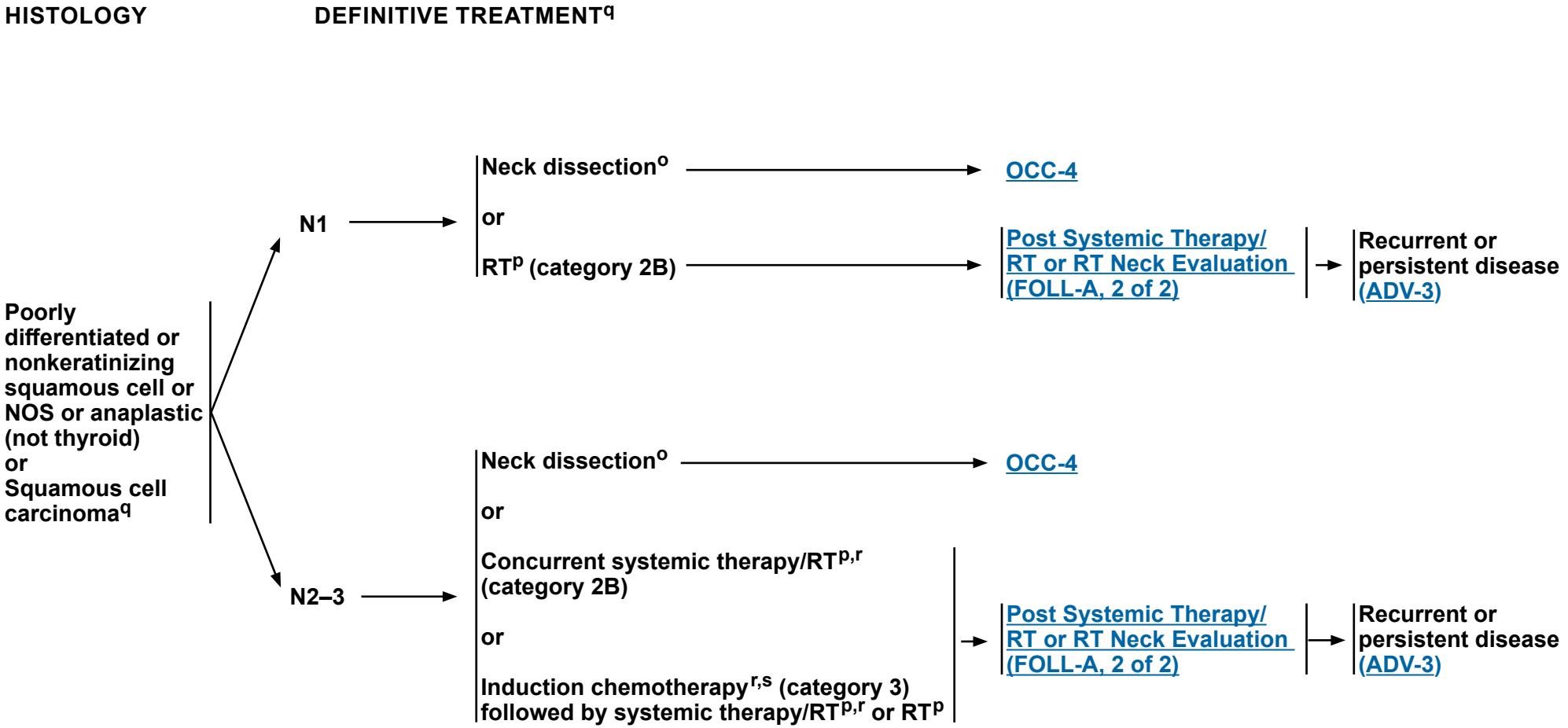

[o] Principles of Surgery (SURG-A).
[p] Principles of Radiation Therapy (OCC-A).

[q] Treatment for nasopharyngeal (NASO-2) and p16-positive oropharyngeal cancers (ORPHPV-3 and ORPHPV-4) to guide management of EBV-positive and HPV-positive occult primary tumors.
[r] Principles of Systemic Therapy for Non-Nasopharyngeal Cancers (SYST-A).
[s] See Discussion on induction chemotherapy.

Note: All recommendations are category 2A unless otherwise indicated.

Version 1.2026, 12/08/2025 © 2025 National Comprehensive Cancer Network® (NCCN®), All rights reserved. NCCN Guidelines® and this illustration may not be reproduced in any form without the express written permission of NCCN.

PLEASE NOTE that use of this NCCN Content is governed by the End-User License Agreement, and you MAY NOT distribute this Content or use it with any artificial intelligence model or tool.
Printed by Galya Basol Kochav on 1/4/2026 9:40:35 AM. Copyright © 2026 National Comprehensive Cancer Network, Inc. All Rights Reserved.

TREATMENT

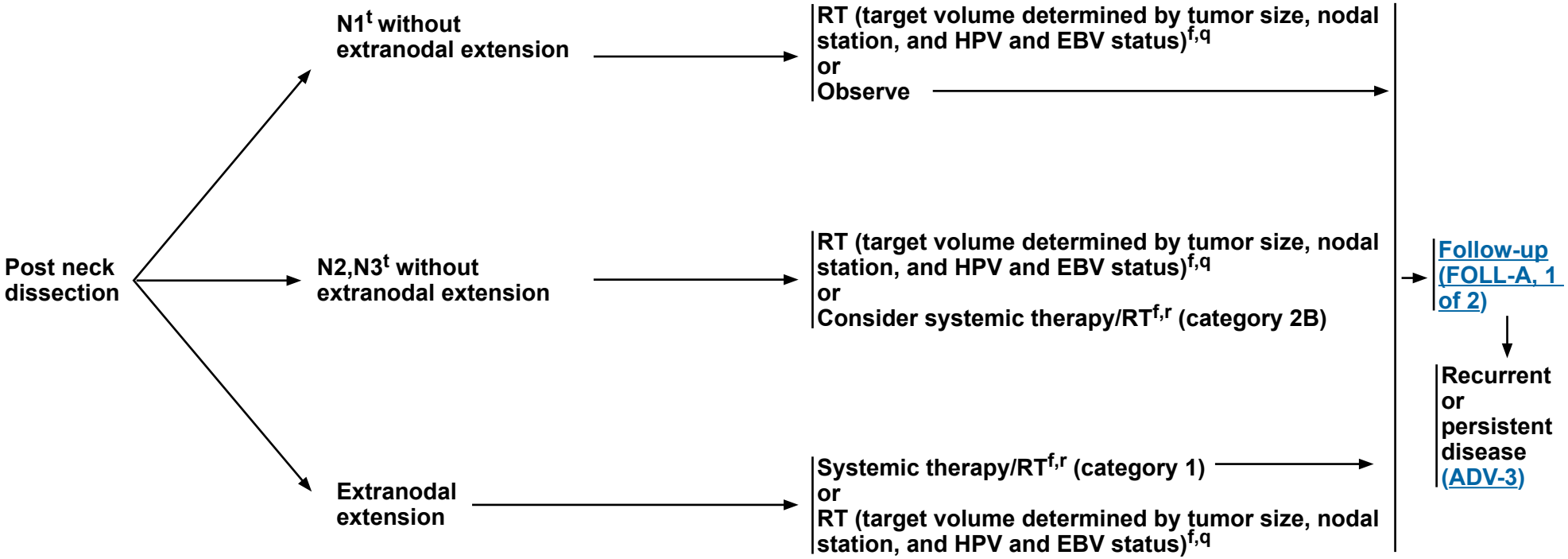

[f] Whether HPV or EBV positive status may help to define the radiation fields is being investigated (see Principles of Radiation Therapy [OCC-A] and Discussion).

[q] Treatment for nasopharyngeal (NASO-2) and p16-positive oropharyngeal cancers (ORPHPV-3 and ORPHPV-4) to guide management of EBV-positive and HPV-positive occult primary tumors.

[r] Principles of Systemic Therapy for Non-Nasopharyngeal Cancers (SYST-A).

[t] Refer to ST-16 for staging criteria.

Note: All recommendations are category 2A unless otherwise indicated.

Version 1.2026, 12/08/2025 © 2025 National Comprehensive Cancer Network® (NCCN®), All rights reserved. NCCN Guidelines® and this illustration may not be reproduced in any form without the express written permission of NCCN.

PLEASE NOTE that use of this NCCN Content is governed by the End-User License Agreement, and you MAY NOT distribute this Content or use it with any artificial intelligence model or tool.
Printed by Galya Basol Kochav on 1/4/2026 9:40:35 AM. Copyright © 2026 National Comprehensive Cancer Network, Inc. All Rights Reserved.

PRINCIPLES OF RADIATION THERAPY[a,b]

DEFINITIVE:

RT Alone

- **PTV**
  - **High risk: Involved lymph nodes (this includes possible local subclinical infiltration at the high-risk level lymph node[s])**
    - **Fractionation:**
      - **66 Gy (2.2 Gy/fraction) to 70 Gy (2.0 Gy/fraction); daily Monday–Friday in 6–7 weeks[c]**
      - **Mucosal dosing: 50–66 Gy (2.0 Gy/fraction) to putative mucosal sites, depending on field size. Consider higher dose to 60–66 Gy to particularly suspicious areas**
  - **Low to intermediate risk: Sites of suspected subclinical spread**
    - **44–50 Gy (2.0 Gy/fraction) to 54–63 Gy (1.6–1.8 Gy/fraction)[d]**

CONCURRENT SYSTEMIC THERAPY/RT[e,f]:

- **PTV**
  - **High risk: Typically 70 Gy (2.0 Gy/fraction)**
  - **Mucosal dosing[g]: 50–60 Gy (2.0 Gy/fraction) to putative mucosal primary sites, depending on field size and use of chemotherapy. Consider higher dose to 60–66 Gy to particularly suspicious areas**
  - **Low to intermediate risk: 44–50 Gy (2.0 Gy/fraction) to 54–63 Gy (1.6–1.8 Gy/fraction)[c]**

IMRT (preferred) is recommended when targeting the pharyngeal axis to minimize the dose to critical structures. Use of proton therapy is an area of active investigation. Proton therapy may be considered when normal tissue constraints cannot be met by photon-based therapy, or when photon-based therapy causes compromise of standard radiation dosing to tumor or postoperative volumes.

[a] For squamous cell carcinoma, adenocarcinoma, and poorly differentiated carcinoma.
[b] See Principles of Radiation Techniques (RAD-A) and Discussion.
[c] For doses >70 Gy, some clinicians think that the fractionation should be slightly modified (eg, <2.0 Gy/fraction for at least some of the treatment) to minimize toxicity. An additional 2–3 doses can be added depending on clinical circumstances.
[d] Suggest 44–50 Gy in sequentially planned IMRT or 54–63 Gy with IMRT dose painting technique (dependent on dose per fraction).
[e] Principles of Systemic Therapy for Non-Nasopharyngeal Cancers (SYST-A).
[f] Based on published data, concurrent systemic therapy/RT most commonly uses conventional fractionation at 2.0 Gy per fraction to a typical dose of 70 Gy in 7 weeks with single-agent cisplatin given every 3 weeks at 100 mg/m2; 2–3 cycles of chemotherapy are used depending on the radiation fractionation scheme (RTOG 0129) (Ang KK, Harris J, Wheeler R, et al. Human papillomavirus and survival of patients with oropharyngeal cancer. N Engl J Med 2010;363:24-35). When carboplatin and fluorouracil are used, the recommended regimen is standard fractionation plus 3 cycles of chemotherapy (Bourhis J, Sire C, Graff P, et al. Concomitant chemoradiotherapy versus acceleration of radiotherapy with or without concomitant chemotherapy in locally advanced head and neck carcinoma [GORTEC 99-02]: an open-label phase 3 randomised trial. Lancet Oncol 2012;13:145-153). Other fraction sizes (eg, 1.8 Gy, conventional), multiagent chemotherapy, other dosing schedules of cisplatin, or altered fractionation with chemotherapy are efficacious, and there is no consensus on the optimal approach. In general, the use of concurrent systemic therapy/RT carries a high toxicity burden; multiagent chemotherapy will likely further increase the toxicity burden. For any systemic therapy/RT approach, close attention should be paid to published reports for the specific chemotherapy agent, dose, and schedule of administration. Systemic therapy/RT should be performed by an experienced team and should include substantial supportive care.
[g] If HPV positive, target oropharynx. If EBV positive, target nasopharynx. Avoid total mucosal irradiation.

Note: All recommendations are category 2A unless otherwise indicated.

Version 1.2026, 12/08/2025 © 2025 National Comprehensive Cancer Network® (NCCN®), All rights reserved. NCCN Guidelines® and this illustration may not be reproduced in any form without the express written permission of NCCN.

PLEASE NOTE that use of this NCCN Content is governed by the End-User License Agreement, and you MAY NOT distribute this Content or use it with any artificial intelligence model or tool.
Printed by Galya Basol Kochav on 1/4/2026 9:40:35 AM. Copyright © 2026 National Comprehensive Cancer Network, Inc. All Rights Reserved.

PRINCIPLES OF RADIATION THERAPY[a,b]

POSTOPERATIVE:

RT or Concurrent Systemic Therapy/RT[e,1-4]

- **Preferred interval between resection and initiation of postoperative RT is ≤6 weeks**
- **PTV**
  - **High risk: Adverse pathologic features such as extranodal extension (OCC-4)**
    - **Mucosal dose[g]: 50–66 Gy (2.0 Gy/fraction) to putative mucosal sites, depending on field size has historically been used.[5] Consider higher dose to 60–66 Gy to particularly suspicious areas**
  - **Low to intermediate risk: Sites of suspected subclinical spread**
    - **44–50 Gy (2.0 Gy/fraction) to 54–63 Gy (1.6–1.8 Gy/fraction)[d]**

IMRT (preferred) is recommended when targeting the pharyngeal axis to minimize the dose to critical structures. Use of proton therapy is an area of active investigation. Proton therapy may be considered when normal tissue constraints cannot be met by photon-based therapy, or when photon-based therapy causes compromise of standard radiation dosing to tumor or postoperative volumes.

[a] For squamous cell carcinoma, adenocarcinoma, and poorly differentiated carcinoma.
[b] See Principles of Radiation Techniques (RAD-A) and Discussion.
[d] Suggest 44–50 Gy in sequentially planned IMRT or 54–63 Gy with IMRT dose painting technique (dependent on dose per fraction).
[e] Principles of Systemic Therapy for Non-Nasopharyngeal Cancers (SYST-A).
[g] If HPV positive, target oropharynx. If EBV positive, target nasopharynx. Avoid total mucosal irradiation.

[1] Bernier J, Domenge C, Ozsahin M, et al. Postoperative irradiation with or without concomitant chemotherapy for locally advanced head and neck cancer. N Engl J Med 2004;350:1945-1952.
[2] Cooper JS, Pajak TF, Forastiere AA, et al. Postoperative concurrent radiotherapy and chemotherapy for high-risk squamous-cell carcinoma of the head and neck. N Engl J Med 2004;350:1937-1944.
[3] Bernier J, Cooper JS, Pajak TF, et al. Defining risk levels in locally advanced head and neck cancers: A comparative analysis of concurrent postoperative radiation plus chemotherapy trials of the EORTC (#22931) and RTOG (#9501). Head Neck 2005;27:843-850.
[4] Cooper JS, Zhang Q, Pajak TF, et al. Long-term follow-up of the RTOG 9501/intergroup phase III trial: postoperative concurrent radiation therapy and chemotherapy in high-risk squamous cell carcinoma of the head and neck. Int J Radiat Oncol Biol Phys 2012;84:1198-1205.
[5] Maghami E, Ismaila N, Alvarez A, et al. Diagnosis and management of squamous cell carcinoma of unknown primary in the head and neck: ASCO Guideline. J Clin Oncol 2020;38:2570-2596.

Note: All recommendations are category 2A unless otherwise indicated.

Version 1.2026, 12/08/2025 © 2025 National Comprehensive Cancer Network® (NCCN®), All rights reserved. NCCN Guidelines® and this illustration may not be reproduced in any form without the express written permission of NCCN.

PLEASE NOTE that use of this NCCN Content is governed by the End-User License Agreement, and you MAY NOT distribute this Content or use it with any artificial intelligence model or tool.
Printed by Galya Basol Kochav on 1/4/2026 9:40:35 AM. Copyright © 2026 National Comprehensive Cancer Network, Inc. All Rights Reserved.

CLINICAL PRESENTATION

Salivary gland mass (unresected or incompletely resected)
- **Parotid**
- **Submandibular**
- **Minor salivary gland[a]**

→

WORKUP

- **H&P[b,c] including a complete head and neck exam; mirror and fiberoptic examination as clinically indicated**
- **FNA biopsy[d]**
- **As clinically indicated:**
  - **CT/MRI with and without contrast of skull base to clavicle[e]**
  - **Chest CT (with or without contrast)[e]**
  - **Preanesthesia studies**
  - **Dental evaluation[f]**
  - **Nutrition,[g] speech, and swallowing evaluation**
  - **Smoking cessation counseling[b]**
  - **Fertility/reproductive counseling[h]**
  - **Screening for hepatitis B**
- **Multidisciplinary consultation as clinically indicated**

→ **Clinically benign[i] or Carcinoma** → **SALI-2**

→ **Lymphoma** → **See NCCN Guidelines for B-Cell Lymphomas and NCCN Guidelines for T-Cell Lymphomas**

[a] Site and stage determine therapeutic approaches.
[b] H&P should include documentation and quantification (pack years smoked) of tobacco use history, as well as alcohol use and counseling. All patients who currently smoke should be advised to quit smoking, and those who formerly smoked should be advised to remain abstinent from smoking. For additional cessation support, refer to the Smoking Cessation and Treatment Resources in the NCCN Guidelines for Smoking Cessation.
[c] Screen for distress. Refer to the NCCN Distress Thermometer and Problem List, which includes social determinants of health. See NCCN Guidelines for Distress Management (DIS-A).
[d] Image-guided (US or CT) needle biopsy of cystic neck nodes may offer better diagnostic yield than FNA by palpation alone for initial diagnosis in this setting. For unresectable or metastatic disease where there is a plan for systemic therapy, a core biopsy would allow for biomarker testing.
[e] Principles of Imaging (IMG-A).
[f] Principles of Oral/Dental Evaluation and Management (DENT-A).
[g] Principles of Nutrition: Management and Supportive Care (NUTR-A).
[h] See fertility and reproductive endocrine considerations in the NCCN Guidelines for Adolescent and Young Adult (AYA) Oncology.
[i] Characteristics of a benign tumor include mobile superficial lobe, slow growth, painless, V and/or VII intact, and no neck nodes.

Note: All recommendations are category 2A unless otherwise indicated.

Version 1.2026, 12/08/2025 © 2025 National Comprehensive Cancer Network® (NCCN®), All rights reserved. NCCN Guidelines® and this illustration may not be reproduced in any form without the express written permission of NCCN.

PLEASE NOTE that use of this NCCN Content is governed by the End-User License Agreement, and you MAY NOT distribute this Content or use it with any artificial intelligence model or tool.
Printed by Galya Basol Kochav on 1/4/2026 9:40:35 AM. Copyright © 2026 National Comprehensive Cancer Network, Inc. All Rights Reserved.

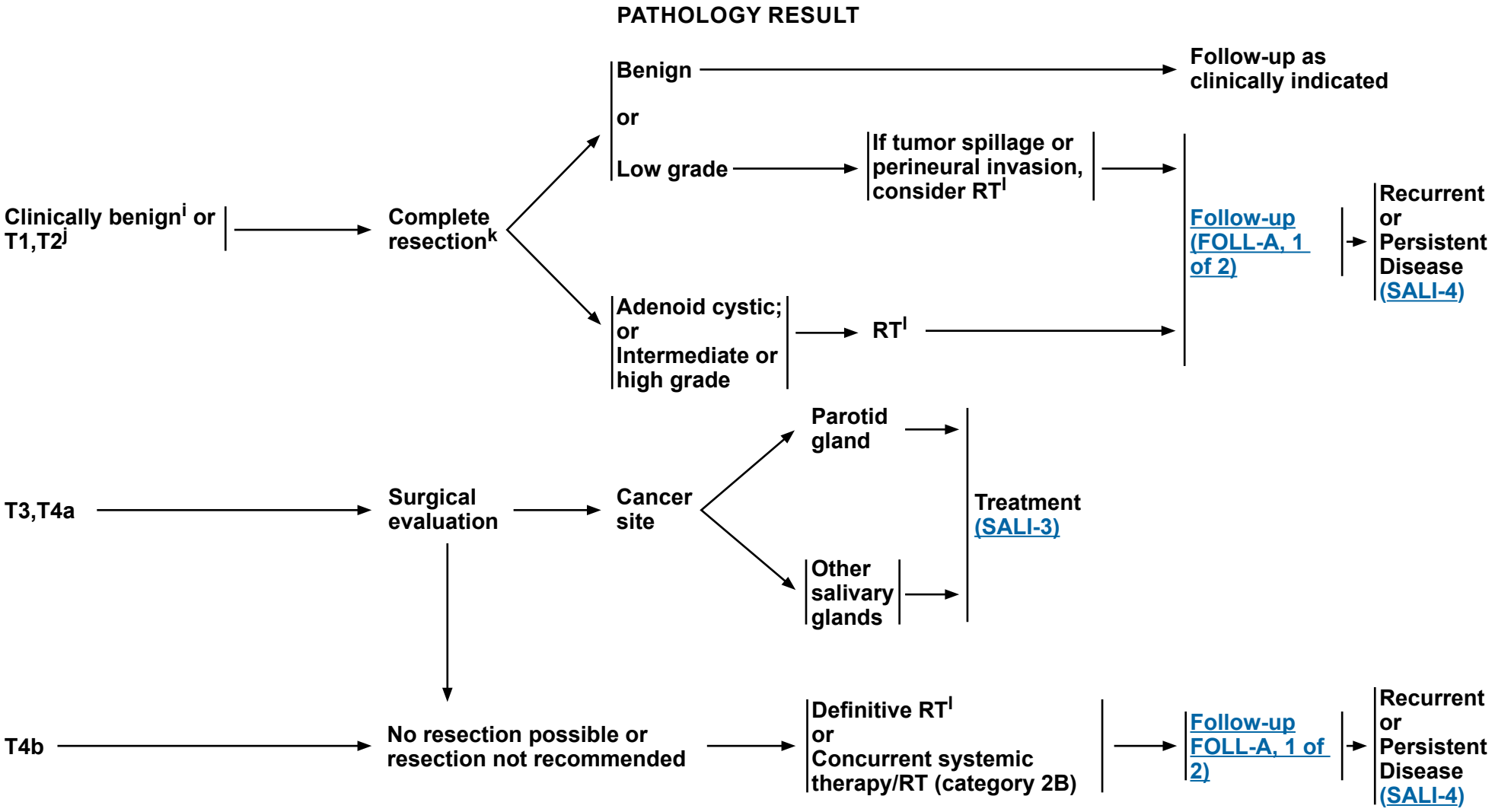

[i] Characteristics of a benign tumor include mobile superficial lobe, slow growth, painless, V and/or VII intact, and no neck nodes.
[j] If incidental N+ disease is present go to SALI-3.
[k] Resection of a clinically benign tumor includes: no enucleation of lateral lobe and intraoperative communication with pathologist if indicated.
[l] Principles of Radiation Therapy (SALI-A).

Note: All recommendations are category 2A unless otherwise indicated.

Version 1.2026, 12/08/2025 © 2025 National Comprehensive Cancer Network® (NCCN®), All rights reserved. NCCN Guidelines® and this illustration may not be reproduced in any form without the express written permission of NCCN.

PLEASE NOTE that use of this NCCN Content is governed by the End-User License Agreement, and you MAY NOT distribute this Content or use it with any artificial intelligence model or tool.
Printed by Galya Basol Kochav on 1/4/2026 9:40:35 AM. Copyright © 2026 National Comprehensive Cancer Network, Inc. All Rights Reserved.

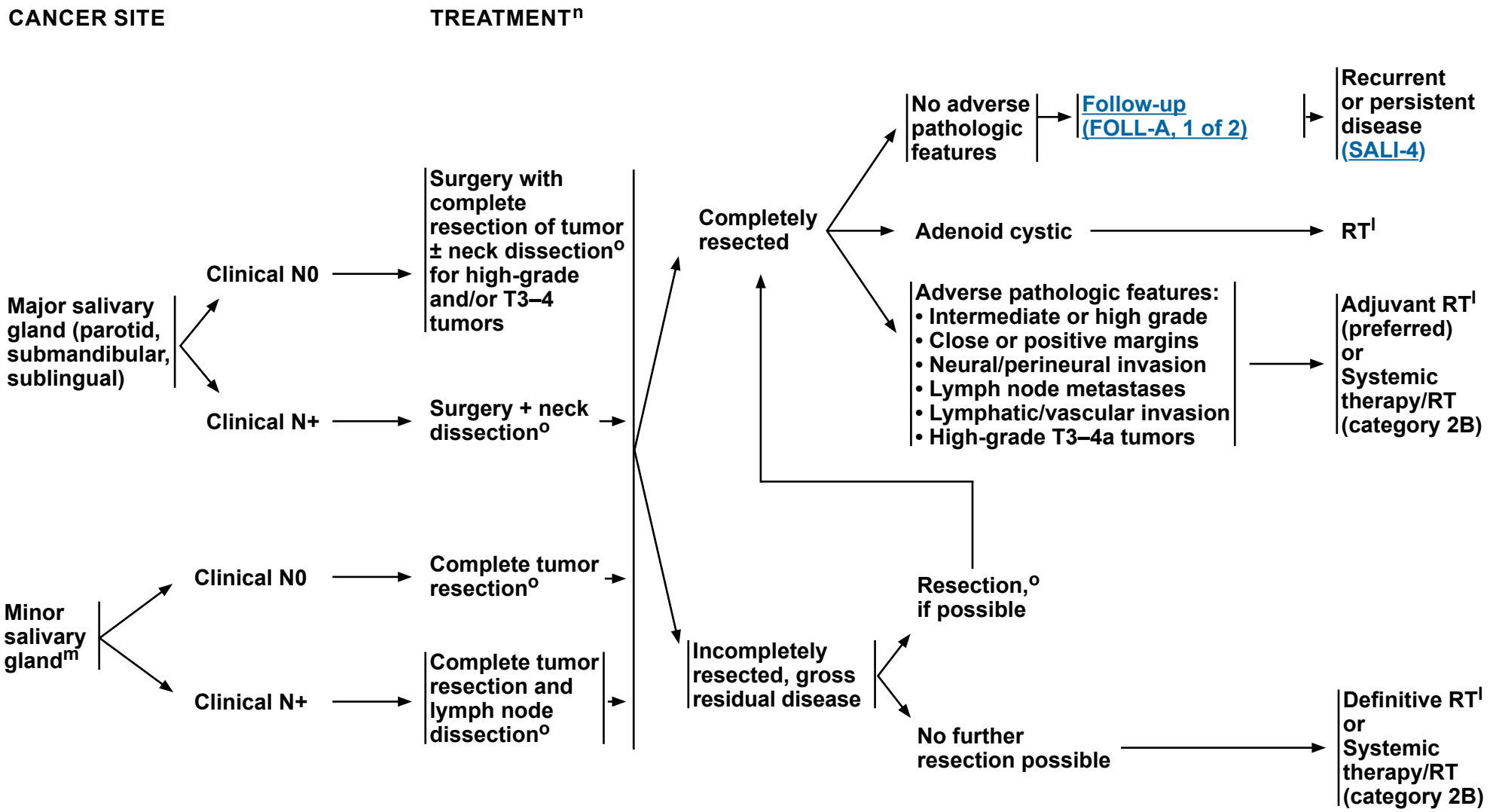

[l] Principles of Radiation Therapy (SALI-A).
[m] For submandibular and sublingual gland tumors, complete gland and tumor resection is recommended.

[n] The facial nerve should be preserved if possible; strongly consider referral to a specialized center with reconstructive expertise.
[o] Principles of Surgery (SURG-A).

Note: All recommendations are category 2A unless otherwise indicated.

Version 1.2026, 12/08/2025 © 2025 National Comprehensive Cancer Network® (NCCN®), All rights reserved. NCCN Guidelines® and this illustration may not be reproduced in any form without the express written permission of NCCN.

PLEASE NOTE that use of this NCCN Content is governed by the End-User License Agreement, and you MAY NOT distribute this Content or use it with any artificial intelligence model or tool.
Printed by Galya Basol Kochav on 1/4/2026 9:40:35 AM. Copyright © 2026 National Comprehensive Cancer Network, Inc. All Rights Reserved.

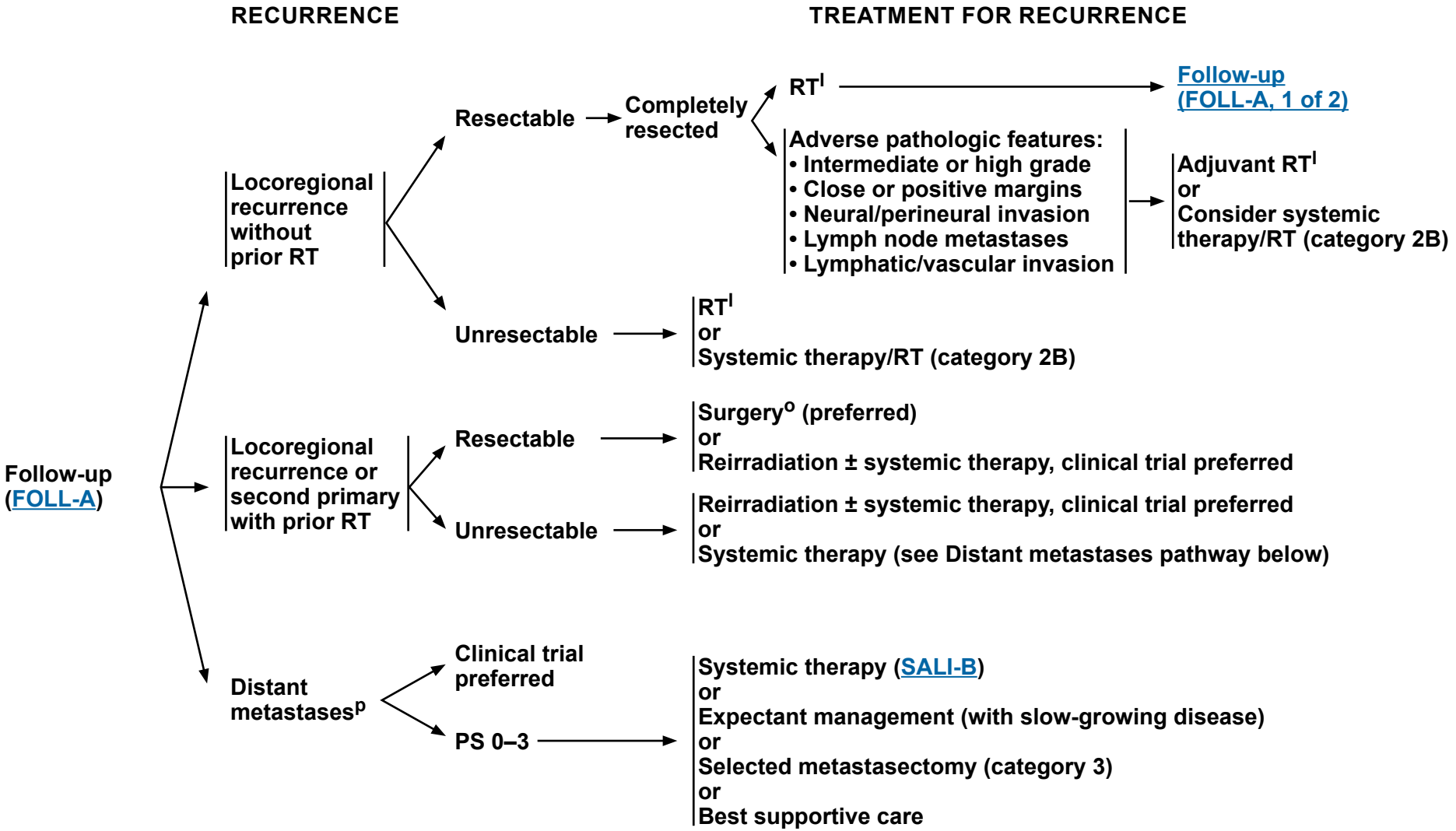

[l] Principles of Radiation Therapy (SALI-A).
[o] Principles of Surgery (SURG-A).

[p] Use MGPT and other appropriate biomarker testing to check status of at least the following: androgen receptor (AR), HER2, *NTRK1/2/3*, FGFR, *BRAF, RET*, microsatellite instability (MSI), mismatch repair deficiency (dMMR), TMB, and programmed death ligand 1 (PD-L1) prior to treatment. (category 2B).

Note: All recommendations are category 2A unless otherwise indicated.

Version 1.2026, 12/08/2025 © 2025 National Comprehensive Cancer Network® (NCCN®), All rights reserved. NCCN Guidelines® and this illustration may not be reproduced in any form without the express written permission of NCCN.

PLEASE NOTE that use of this NCCN Content is governed by the End-User License Agreement, and you MAY NOT distribute this Content or use it with any artificial intelligence model or tool.
Printed by Galya Basol Kochav on 1/4/2026 9:40:35 AM. Copyright © 2026 National Comprehensive Cancer Network, Inc. All Rights Reserved.

PRINCIPLES OF RADIATION THERAPY[a,b,c]

DEFINITIVE:

RT Alone or Concurrent Systemic Therapy/RT

- **Photon or photon/electron therapy or highly conformal RT techniques**
- **PTV:**
  - **High risk: Primary tumor and involved lymph nodes (this includes possible local subclinical infiltration at the primary and at the high-risk level lymph node[s])**
    - **Fractionation: 66 Gy (2.0 Gy/fraction) to 70–70.2 Gy (1.8–2.0 Gy/fraction); daily Monday–Friday in 6–8 weeks[d]**
  - **Low to intermediate risk: Sites of suspected subclinical spread**
    - **44–50 Gy (2.0 Gy/fraction) to 54–63 Gy (1.8–2.0 Gy/fraction)[e]**

POSTOPERATIVE RT:

RT Alone or Concurrent Systemic Therapy/RT

- **Preferred interval between resection and initiation of postoperative RT is ≤6 weeks**
- **Photon or photon/electron therapy**
- **PTV**
  - **High risk: Adverse pathologic features such as positive margins (SALI-3)**
    - **60–66 Gy (2.0 Gy/fraction); daily Monday–Friday in 6–7 weeks**
  - **Low to intermediate risk: Sites of suspected subclinical spread**
    - **44–50 Gy (2.0 Gy/fraction) to 54–63 Gy (1.8–2.0 Gy/fraction)[e]**

IMRT (preferred) is recommended. Proton therapy can be considered when normal tissue constraints cannot be met by photon-based therapy, or when photon-based therapy causes compromise of standard radiation dosing to tumor or postoperative volumes.

[a] See Principles of Radiation Techniques (RAD-A) and Discussion.

[b] Neutron therapy was historically considered a promising solution for unresectable salivary gland cancers, but this therapy is currently offered at only one center in the United States. Pfister DG, Spencer S, Brizel DM, et al. NCCN Head and Neck Cancers, Version 1.2015. J Natl Compr Canc Netw 2015;13:847-855.

[c] In general, the reirradiated population of patients with head and neck cancer described in current literature represents a diverse but highly selected group of patients treated in centers where there is a high level of expertise and systems in place for managing acute and long-term toxicities. When the goal of treatment is curative and surgery is not an option, reirradiation strategies can be considered for patients who: develop locoregional failures or second primaries at ≥6 months after the initial radiotherapy; can receive additional doses of radiotherapy of at least 60 Gy; and can tolerate concurrent chemotherapy. OARs for toxicity should be carefully analyzed through review of dose-volume histograms, and consideration for acceptable doses should be made on the basis of time interval since original radiotherapy, anticipated volumes to be included, and patient's life expectancy. For reirradiation dosing, see Principles of Radiation Techniques (RAD-A). Proton therapy can be considered when normal tissue constraints cannot be met by photon-based therapy, or when photon-based therapy causes compromise of standard radiation dosing to tumor or postoperative volumes (Takiar V, Garden AS, Ma D, et al. Reirradiation of head and neck cancers with intensity modulated radiation therapy: Outcomes and analyses. Int J Radiat Oncol Biol Phys 2016;95:1117-1131).

[d] For doses >70 Gy, some clinicians think that the fractionation should be slightly modified (eg, <2.0 Gy/fraction for at least some of the treatment) to minimize toxicity. An additional 2–3 doses can be added depending on clinical circumstances.

[e] Suggest 44–50 Gy in sequentially planned IMRT or 54–63 Gy with IMRT dose painting technique (dependent on dose per fraction).

Note: All recommendations are category 2A unless otherwise indicated.

Version 1.2026, 12/08/2025 © 2025 National Comprehensive Cancer Network® (NCCN®), All rights reserved. NCCN Guidelines® and this illustration may not be reproduced in any form without the express written permission of NCCN.

PLEASE NOTE that use of this NCCN Content is governed by the End-User License Agreement, and you MAY NOT distribute this Content or use it with any artificial intelligence model or tool.
Printed by Galya Basol Kochav on 1/4/2026 9:40:35 AM. Copyright © 2026 National Comprehensive Cancer Network, Inc. All Rights Reserved.

SYSTEMIC THERAPY FOR SALIVARY GLAND TUMORS

Recurrent, Unresectable, or Metastatic Salivary Gland Tumors (with no surgery or RT option)

- **The choice of systemic therapy should be individualized based on patient characteristics and goals of therapy.**
- **An FDA-approved biosimilar is an appropriate substitute for any recommended systemic biologic therapy in the NCCN Guidelines.**
- **Pembrolizumab and berahyaluronidase alfa-pmph subcutaneous injection may be substituted for IV pembrolizumab. Pembrolizumab and berahyaluronidase alfa-pmph has different dosing and administration instructions compared to IV pembrolizumab.**

Preferred
- None

Other Recommended
- Carboplatin/Gemcitabine[1]
- Carboplatin/Paclitaxel[2,3]
- Cisplatin/Vinorelbine[4]
- Paclitaxel (category 2A for non-adenoid cystic carcinoma [ACC]; category 2B for ACC)[5]
- Cisplatin/Cyclophosphamide/Doxorubicin[6] (category 2B)

Useful in Certain Circumstances
- Androgen receptor (AR) therapy for AR+ tumors
  - Abiraterone[7]/Prednisone/luteinizing hormone-releasing hormone (LHRH) agonist (Triptorelin, Leuprolide, or Goserelin)
  - Bicalutamide[8]
  - Leuprolide[9]
  - Goserelin (category 2B)[10,11,12]
- For *NTRK1/2/3* gene fusion-positive tumors
  - Entrectinib[13]
  - Larotrectinib[14,15]
  - Repotrectinib[16]
- HER2-targeted therapy for HER2+ tumors[a]
  - Ado-trastuzumab emtansine (TDM-1)[17]
  - Docetaxel + Trastuzumab[18]
  - Fam-trastuzumab deruxtecan-nxki[19]
  - Pertuzumab + Trastuzumab[20]
  - Trastuzumab[21]
- Other targeted therapies
  - Dabrafenib/Trametinib for *BRAF* V600E-positive tumors[22]
  - Pembrolizumab (for microsatellite instability-high [MSI-H], mismatch repair deficient [dMMR], TMB-H [≥10 mut/Mb] tumors, or PD-L1-positive tumors)[23]
  - Selpercatinib for *RET* gene fusion-positive tumors[24]
  - Erdafitinib for *FGFR* mutations or gene fusion-positive tumors and disease progression with at least one line of prior systemic therapy and no availability of an alternative systemic therapy (category 2B)[25]
- Axitinib (category 2B)[26]
- Axitinib + Avelumab for ACC (category 2B)[27]
- Lenvatinib for ACC (category 2B)[28]
- Sorafenib (category 2B)[29]

[a] Refer to ASCO/CAP guidelines for HER2 testing (Wolff AC, Hammond MEH, Allison KH, et al. Human epidermal growth factor receptor 2 testing in breast cancer: American Society of Clinical Oncology/College of American Pathologists clinical practice guideline focused update. J Clin Oncol 2018;36:2105-2122).

References

Note: All recommendations are category 2A unless otherwise indicated.

Version 1.2026, 12/08/2025 © 2025 National Comprehensive Cancer Network® (NCCN®), All rights reserved. NCCN Guidelines® and this illustration may not be reproduced in any form without the express written permission of NCCN.

PLEASE NOTE that use of this NCCN Content is governed by the End-User License Agreement, and you MAY NOT distribute this Content or use it with any artificial intelligence model or tool.
Printed by Galya Basol Kochav on 1/4/2026 9:40:35 AM. Copyright © 2026 National Comprehensive Cancer Network, Inc. All Rights Reserved.

SYSTEMIC THERAPY FOR SALIVARY GLAND TUMORS

[1] Laurie SA, Siu LL, Winquist E, et al. A phase 2 study of platinum and gemcitabine in patients with advanced salivary gland cancer: a trial of the NCIC Clinical Trials Group. Cancer 2010;116:362-368.
[2] Nakano K, Sato Y, Sasaki T, et al. Combination chemotherapy of carboplatin and paclitaxel for advanced/metastatic salivary gland carcinoma patients: differences in responses by different pathological diagnoses. Acta Otolaryngol 2016;136:948-951.
[3] Airoldi M, Fornari G, Pedani F, et al. Paclitaxel and carboplatin for recurrent salivary gland malignancies. Anticancer Res 2000;20:3781-3783.
[4] Airoldi M, Pedani F, Succo G, et al. Phase II randomized trial comparing vinorelbine versus vinorelbine plus cisplatin in patients with recurrent salivary gland malignancies. Cancer 2001;91:541-547.
[5] Gilbert J, Li Y, Pinto HA, et al. Phase II trial of taxol in salivary gland malignancies (E1394): a trial of the Eastern Cooperative Oncology Group. Head Neck 2006;28:197-204.
[6] Licitra L, Cavina R, Grandi C, et al. Cisplatin, doxorubicin and cyclophosphamide in advanced salivary gland carcinoma. A phase II trial of 22 patients. Ann Oncol 1996;7:640-642.
[7] Locati L, Cavalieri S, Bergamini C, et al. Abiraterone acetate in patients with castration-resistant, androgen receptor-expressing salivary gland cancer: A phase II trial. J Clin Oncol 2021;39:4061-4068.
[8] Boon E, van Boxtel W, Buter J, et al. Androgen deprivation therapy for androgen receptor-positive advanced salivary duct carcinoma: a nationwide case series of 35 patients in the Netherlands. Head Neck 2018;40:605-613.
[9] Fushimi C, Tada Y, Takahashi H, et al. A prospective phase II study of combined androgen blockade in patients with androgen receptor-positive metastatic or locally advanced unresectable salivary gland carcinoma. Ann Oncol 2018;29:979-984.
[10] Honma Y, Monden N, Yamazaki K, et al. Yatagarasu: A single-arm, open-label, phase 2 study of apalutamide (APA) plus goserelin (GOS) for patients (Pts) with far locally advanced or recurrent/metastatic (FLa/RM) and androgen receptor (AR)-expressing salivary gland carcinoma (SGC) [abstract]. J Clin Oncol 2022;40 (Suppl):Abstract 6079.
[11] Patel M, Fujioka N, Pease DF, et al. BTCRC-HN17-111, A phase 2 trial of ADT (Goserelin) in combination with pembrolizumab for patients with advanced salivary gland tumors expressing androgen receptor (Ar) [abstract]. J Clin Oncol 2022;40(Suppl):Abstract e18091.
[12] Boon E, van Boxtel W, Buter J, et al. Androgen deprivation therapy for androgen receptor-positive advanced salivary duct carcinoma: A nationwide case series of 35 patients in The Netherlands. Head Neck 2018;40:605-613.
[13] Doebele RC, Drilon A, Paz-Ares L, et al. Entrectinib in patients with advanced or metastatic NTRK fusion-positive solid tumours: integrated analysis of three phase 1-2 trials. Lancet Oncol 2020;21:271-282.
[14] Hong DS, Bauer TM, Lee JJ, et al. Larotrectinib in adult patients with solid tumours: a multi-centre, open-label, phase I dose-escalation study. Ann Oncol 2019;30:325-331.
[15] Drilon A, Laetsch TW, Kummar S, et al. Efficacy of larotrectinib in TRK fusion-positive cancers in adults and children. N Engl J Med 2018;378:731-739.
[16] Solomon B, Drilon A, Lin JJ, et al. Repotrectinib in patients with NTRK fusion positive advanced solid tumors, including non-small cell lung cancer: update from the phase 1/2 TRIDENT-1 trial. Poster presented at the European Society for Medical Oncology Congress, Madrid, Spain, October 20-24, 2023.
[17] Jhaveri KL, Wang XV, Makker V, et al. Ado-trastuzumab emtansine (T-DM1) in patients with HER2-amplified tumors excluding breast and gastric/gastroesophageal junction (GEJ) adenocarcinomas: results from the NCI-MATCH trial (EAY131) subprotocol Q. Ann Oncol 2019;30:1821-1830.
[18] Takahashi H, Tada Y, Saotome T, et al. Phase II trial of trastuzumab and docetaxel in patients with human epidermal growth factor receptor 2-positive salivary duct carcinoma. J Clin Oncol 2019;37:125-134.
[19] Bando H, Kinoshita I, Modi S, et al. Trastuzumab deruxtecan (T-DXd) in patients with human epidermal growth factor receptor 2 (HER2)-expressing salivary duct carcinoma: Subgroup analysis of two phase 1 studies [abstract]. J Clin Oncol 2021;39(Suppl): Abstract 6079.
[20] Kurzrock R, Bowles DW, Kang H, et al. Targeted therapy for advanced salivary gland carcinoma based on molecular profiling: results from MyPathway, a phase IIa multiple basket study. Ann Oncol 2020;31:412-421.
[21] Thorpe LM, Schrock AB, Erlich RL, et al. Significant and durable clinical benefit from trastuzumab in 2 patients with HER2-amplified salivary gland cancer and a review of the literature. Head Neck 2017;39:E40-E44.
[22] Lin VTG, Nabell LM, Spencer SA, et al. First-line treatment of widely metastatic BRAF-mutated salivary duct carcinoma with combined BRAF and MEK inhibition. J Natl Compr Canc Netw 2018;16:1166-1170.
[23] Marabelle A, Fakih M, Lopez J, et al. Association of tumour mutational burden with outcomes in patients with advanced solid tumours treated with pembrolizumab: prospective biomarker analysis of the multicohort, open-label, phase 2 KEYNOTE-158 study. Lancet Oncol 2020;21:1353-1365.
[24] Subbiah V, Wolf J, Konda B, et al. Tumour-agnostic efficacy and safety of selpercatinib in patients with RET fusion-positive solid tumours other than lung or thyroid tumours (LIBRETTO-001): a phase 1/2, open-label, basket trial. Lancet Oncol 2022;23:1261-1273.
[25] Pant S, Schuler M, Iyer G, et al. Erdafitinib in patients with advanced solid tumours with FGFR alterations (RAGNAR): an international, single-arm, phase 2 study. Lancet Oncol 2023;24:925-935.
[26] Locati LD, Cavalieri S, Bergamini C, et al. Phase II trial with axitinib in recurrent and/or metastatic salivary gland cancers of the upper aerodigestive tract. Head Neck 2019;41:3670-3676.
[27] Ferrarotto R, Sousa LG, Feng L, et al. Phase II clinical trial of axitinib and avelumab in patients with recurrent/metastatic adenoid cystic carcinoma. J Clin Oncol 2023;41:2843-2851.
[28] Tchekmedyian V, Sherman EJ, Dunn L, et al. Phase II study of lenvatinib in patients with progressive, recurrent or metastatic adenoid cystic carcinoma. J Clin Oncol 2019;37:1529-1537.
[29] Thomson DJ, Silva P, Denton K, et al. Phase II trial of sorafenib in advanced salivary adenoid cystic carcinoma of the head and neck. Head Neck 2015;37:182-187.

Note: All recommendations are category 2A unless otherwise indicated.

Version 1.2026, 12/08/2025 © 2025 National Comprehensive Cancer Network® (NCCN®), All rights reserved. NCCN Guidelines® and this illustration may not be reproduced in any form without the express written permission of NCCN.

PLEASE NOTE that use of this NCCN Content is governed by the End-User License Agreement, and you MAY NOT distribute this Content or use it with any artificial intelligence model or tool.
Printed by Galya Basol Kochav on 1/4/2026 9:40:35 AM. Copyright © 2026 National Comprehensive Cancer Network, Inc. All Rights Reserved.

PRESENTATION | **WORKUP** | **TREATMENT**

Biopsy confirms diagnosis of mucosal malignant melanoma[a]

- **H&P[b,c] including complete head and neck exam; mirror and fiberoptic examination as clinically indicated**
- **Verification of pathology using appropriate staining (HMB-45, S100, Melan-A)**
- **CT with contrast and/or MRI with and without contrast to determine anatomic extent of disease, particularly for sinus disease[d]**
- **As clinically indicated:**
  - **Chest CT (with or without contrast)[d]**
  - **Consider FDG-PET/CT or chest/abdomen/pelvis CT with contrast, and brain MRI (with and without contrast) to rule out metastatic disease[d]**
  - **Dental/prosthodontic evaluation[e]**
  - **Nutrition, speech, and swallowing evaluation/therapy[f]**
  - **Smoking cessation counseling[b]**
  - **Fertility/reproductive counseling[g]**
  - **Screening for hepatitis B**

Multidisciplinary consultation as clinically indicated

Sinus or nasal cavity mucosal melanoma → **Primary Treatment (MM-2)**

Oral cavity, oropharynx, larynx, or hypopharynx mucosal melanoma → **Primary Treatment (MM-3)**

[a] Image-guided (US or CT) needle biopsy of cystic neck nodes may offer better diagnostic yield than FNA by palpation alone for initial diagnosis in this setting. For unresectable or metastatic disease where there is a plan for systemic therapy, a core biopsy would allow for biomarker testing.

[b] H&P should include documentation and quantification (pack years smoked) of tobacco use history, as well as alcohol use and counseling. All patients who currently smoke should be advised to quit smoking, and those who formerly smoked should be advised to remain abstinent from smoking. For additional cessation support, refer to the Smoking Cessation and Treatment Resources in the NCCN Guidelines for Smoking Cessation.

[c] Screen for distress. Refer to the NCCN Distress Thermometer and Problem List, which includes social determinants of health. See NCCN Guidelines for Distress Management (DIS-A).

[d] Principles of Imaging (IMG-A).

[e] Principles of Oral/Dental Evaluation and Management (DENT-A).

[f] Principles of Nutrition: Management and Supportive Care (NUTR-A).

[g] See fertility and reproductive endocrine considerations in the NCCN Guidelines for Adolescent and Young Adult (AYA) Oncology.

Note: All recommendations are category 2A unless otherwise indicated.

Version 1.2026, 12/08/2025 © 2025 National Comprehensive Cancer Network® (NCCN®), All rights reserved. NCCN Guidelines® and this illustration may not be reproduced in any form without the express written permission of NCCN.

PLEASE NOTE that use of this NCCN Content is governed by the End-User License Agreement, and you MAY NOT distribute this Content or use it with any artificial intelligence model or tool.
Printed by Galya Basol Kochav on 1/4/2026 9:40:35 AM. Copyright © 2026 National Comprehensive Cancer Network, Inc. All Rights Reserved.

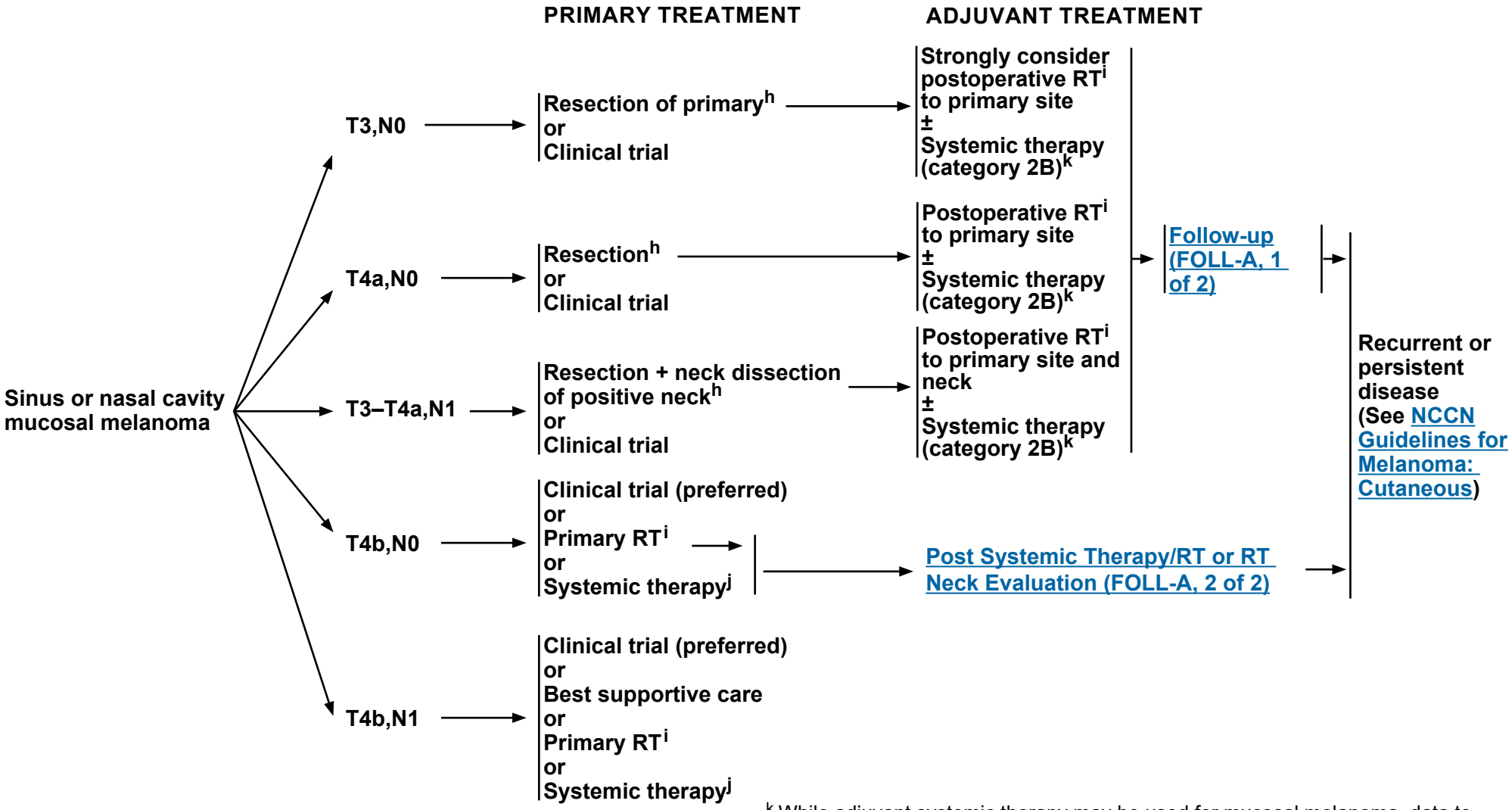

[h] Principles of Surgery (SURG-A).
[i] Principles of Radiation Therapy (MM-A).
[j] See Systemic Therapy for Metastatic or Unresectable Disease (MELSYS-1) in the NCCN Guidelines for Melanoma: Cutaneous.

[k] While adjuvant systemic therapy may be used for mucosal melanoma, data to support its use are far fewer than for cutaneous melanoma. Options may include Nivolumab (category 2B) or cisplatin/temozolomide (category 2B). Nivolumab and hyaluronidase-nvhy subcutaneous injection may be substituted for IV nivolumab. Nivolumab and hyaluronidase-nvhy has different dosing and administration instructions compared to IV nivolumab. See Discussion.

Note: All recommendations are category 2A unless otherwise indicated.

Version 1.2026, 12/08/2025 © 2025 National Comprehensive Cancer Network® (NCCN®), All rights reserved. NCCN Guidelines® and this illustration may not be reproduced in any form without the express written permission of NCCN.

PLEASE NOTE that use of this NCCN Content is governed by the End-User License Agreement, and you MAY NOT distribute this Content or use it with any artificial intelligence model or tool.
Printed by Galya Basol Kochav on 1/4/2026 9:40:35 AM. Copyright © 2026 National Comprehensive Cancer Network, Inc. All Rights Reserved.

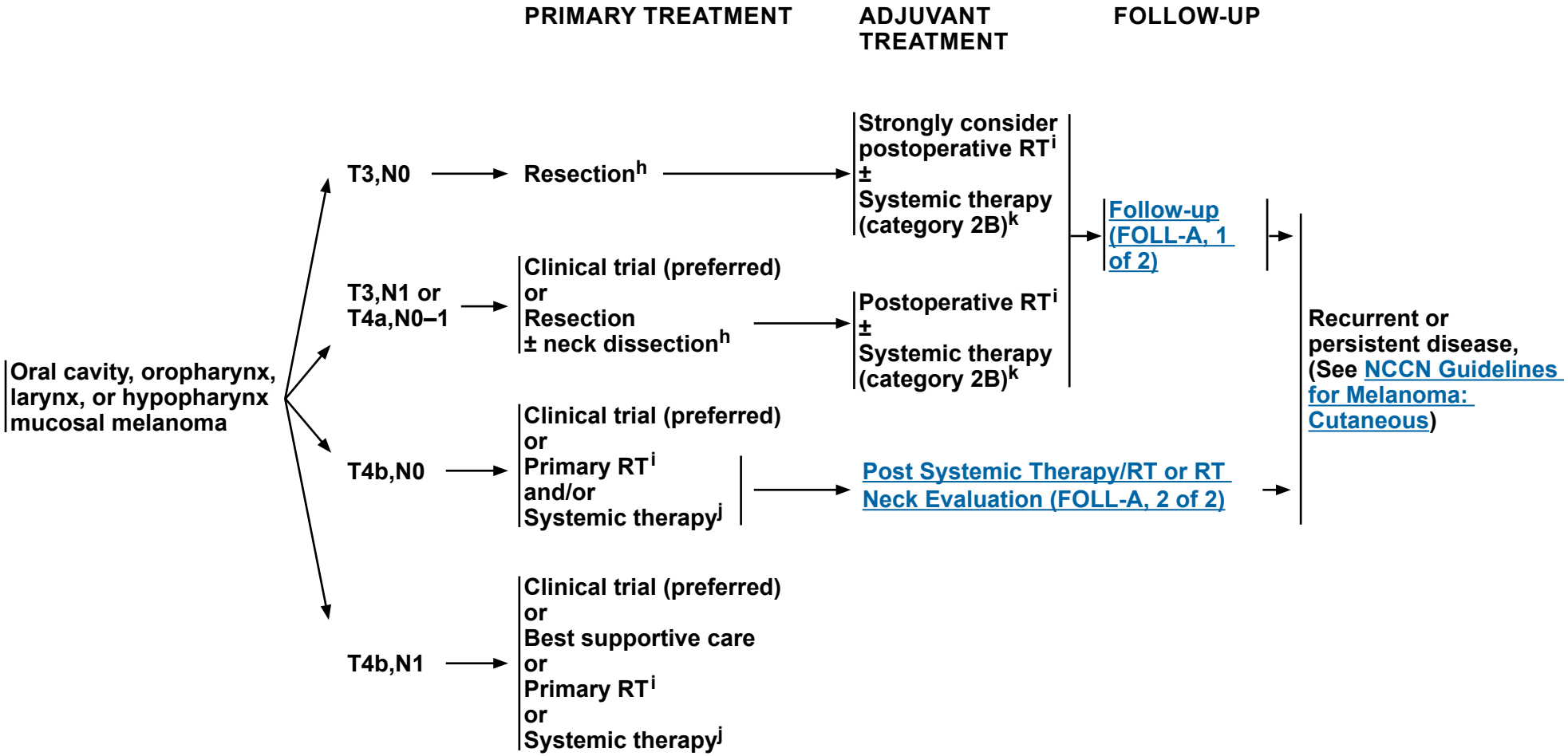

[h] Principles of Surgery (SURG-A).
[i] Principles of Radiation Therapy (MM-A).
[j] See Systemic Therapy for Metastatic or Unresectable Disease (MELSYS-1) in the NCCN Guidelines for Melanoma: Cutaneous.

[k] While adjuvant systemic therapy may be used for mucosal melanoma, data to support its use are far fewer than for cutaneous melanoma. Options may include Nivolumab (category 2B) or cisplatin/temozolomide (category 2B). Nivolumab and hyaluronidase-nvhy subcutaneous injection may be substituted for IV nivolumab. Nivolumab and hyaluronidase-nvhy has different dosing and administration instructions compared to IV nivolumab. See Discussion.

Note: All recommendations are category 2A unless otherwise indicated.

Version 1.2026, 12/08/2025 © 2025 National Comprehensive Cancer Network® (NCCN®), All rights reserved. NCCN Guidelines® and this illustration may not be reproduced in any form without the express written permission of NCCN.

PLEASE NOTE that use of this NCCN Content is governed by the End-User License Agreement, and you MAY NOT distribute this Content or use it with any artificial intelligence model or tool.
Printed by Galya Basol Kochav on 1/4/2026 9:40:35 AM. Copyright © 2026 National Comprehensive Cancer Network, Inc. All Rights Reserved.

PRIMARY THERAPY FOR OCCULT PRIMARY- MELANOMA (also see NCCN Guidelines for Occult Primary)

Nodal basin → **Nodal dissection**[h] → **± RT to nodal basin for high-risk features**[i,l] → **± Adjuvant systemic therapy, per NCCN Guidelines for Melanoma: Cutaneous**

[h] Principles of Surgery (SURG-A).
[i] Principles of Radiation Therapy (MM-A).
[l] High-risk: adverse pathologic features: >2 nodes, single node >3 cm, extranodal extension, recurrence in nodal basin after previous surgery.

Note: All recommendations are category 2A unless otherwise indicated.

Version 1.2026, 12/08/2025 © 2025 National Comprehensive Cancer Network® (NCCN®), All rights reserved. NCCN Guidelines® and this illustration may not be reproduced in any form without the express written permission of NCCN.

PLEASE NOTE that use of this NCCN Content is governed by the End-User License Agreement, and you MAY NOT distribute this Content or use it with any artificial intelligence model or tool.
Printed by Galya Basol Kochav on 1/4/2026 9:40:35 AM. Copyright © 2026 National Comprehensive Cancer Network, Inc. All Rights Reserved.

PRINCIPLES OF RADIATION THERAPY[a,b]

DEFINITIVE:

RT Alone (unresectable locally advanced melanoma):

- **PTV:**
  - **High risk: Primary tumor and involved lymph nodes (this includes possible local subclinical infiltration at the primary site and at the high-risk-level lymph node[s])**
    - **◊ 66 Gy (2.2 Gy/fraction) to 70 Gy (2.0 Gy/fraction) daily Monday–Friday in 6–7 weeks**
  - **Low to intermediate risk: Sites suspected of subclinical spread**
    - **◊ 44–50 Gy (2.0 Gy/fraction) to 54–63 Gy (1.6–1.8 Gy/fraction)[c]**
- **Palliative RT doses and schedules may be considered.**
- **Optional dosing schedules may be considered.**
  - **48–50 Gy (2.4–3.0 Gy/fraction)**
  - **30–36 Gy (6 Gy/fraction)**

POSTOPERATIVE:

RT:

- **Preferred interval between resection and initiation of postoperative RT is <6 weeks.**
- **PTV**
  - **High risk: Adverse pathologic features >2 nodes, single node >3 cm, extranodal extension, recurrence in nodal basin after previous surgery[b]**
    - **◊ 60–66 Gy (2.0 Gy/fraction; daily Monday-Friday) in 6–6.5 weeks**
  - **Low to intermediate risk: Sites of suspected subclinical spread**
    - **◊ 44–50 Gy (2.0 Gy/fraction) to 54–63 Gy (1.6–1.8 Gy/fraction)[c]**
- **Optional dosing schedules may be considered[1,2]:**
  - **48–50 Gy (2.4–3.0 Gy/fraction)**
  - **30–36 Gy (6 Gy/fraction)**

IMRT (preferred) is recommended. Proton therapy can be considered when normal tissue constraints cannot be met by photon-based therapy, or when photon-based therapy causes compromise of standard radiation dosing to tumor or postoperative volumes.

[a] See Principles of Radiation Techniques (RAD-A) and Discussion.

[b] Recent studies suggest that increased toxicity may occur when RT is used in combination with BRAF inhibitors (Anker CJ, Grossmann KF, Atkins MB, et al. Avoiding severe toxicity from combined BRAF inhibitor and radiation treatment: Consensus guidelines from the Eastern Cooperative Oncology Group [ECOG]. Int J Radiat Oncol Biol Phys 2016;95:632-646).

[c] Suggest 44–50 Gy in sequentially planned IMRT or 54–63 Gy with IMRT dose painting technique (dependent on dose per fraction).

[1] Burmeister BH, Henderson MA, Ainslie J, et al. Adjuvant radiotherapy versus observation alone for patients at risk of lymph-node field relapse after therapeutic lymphadenectomy for melanoma: a randomised trial. Lancet Oncol 2012;13:589-597.

[2] Ballo MT, Bonnen MD, Garden AS, et al. Adjuvant irradiation for cervical node metastases from melanoma. Cancer 2003;97:1789-1796; Moreno MA, Roberts DB, Kupferman ME, et al. Mucosal melanoma of the nose and paranasal sinuses, a contemporary experience from the M. D. Anderson Cancer Center. Cancer 2010;116:2215-2223.

Note: All recommendations are category 2A unless otherwise indicated.

Version 1.2026, 12/08/2025 © 2025 National Comprehensive Cancer Network® (NCCN®), All rights reserved. NCCN Guidelines® and this illustration may not be reproduced in any form without the express written permission of NCCN.

PLEASE NOTE that use of this NCCN Content is governed by the End-User License Agreement, and you MAY NOT distribute this Content or use it with any artificial intelligence model or tool.
Printed by Galya Basol Kochav on 1/4/2026 9:40:35 AM. Copyright © 2026 National Comprehensive Cancer Network, Inc. All Rights Reserved.

FOLLOW-UP RECOMMENDATIONS[a]
(based on risk of relapse, second primaries, treatment sequelae, and toxicities)

- **H&P exam (including a complete head and neck exam; and mirror and fiberoptic examination)[b]:**
  - **Year 1, every 1–3 mo**
  - **Year 2, every 2–6 mo**
  - **Years 3–5, every 4–8 mo**
  - **>5 years, every 12 mo**
- **AM cortisol, growth hormone (GH), free T4, prolactin, insulin-like growth factor 1 (IGF-1), luteinizing hormone (LH), follicle-stimulating hormone (FSH), serum adrenocorticotropic hormone (ACTH), thyroid-stimulating hormone (TSH), and total and bioavailable testosterone levels annually to evaluate panhypopituitarism following RT to the skull base[1] (category 2B)**
- **Imaging (Principles of Imaging, IMG-A)**
- **TSH every 6–12 mo if neck irradiation and/or partial thyroidectomy**
- **Dental evaluation[c] for oral cavity and sites exposed to significant intraoral radiation treatment**
- **Consider EBV DNA monitoring for EBER+ nasopharyngeal cancer (category 2B)**
- **Consider venous duplex ultrasound of the neck every 3 years if neck irradiated[2]**
- **Supportive care and rehabilitation:**
  - **Speech/hearing and swallowing evaluation[d] and rehabilitation as clinically indicated**
  - **Nutritional evaluation and rehabilitation as clinically indicated until nutritional status is stabilized[d]**
  - **Ongoing surveillance for depression (See NCCN Guidelines for Distress Management)**
  - **Smoking cessation[e] and alcohol counseling as clinically indicated**
  - **Lymphedema evaluation and rehabilitation, as clinically indicated (see SLYMPH-A in the NCCN Guidelines for Survivorship)**
- **For patients receiving or who have received checkpoint inhibitor therapies, monitor for ongoing adverse reactions (See NCCN Guidelines for Management of Immunotherapy-Related Toxicities)**
- **Survivorship**
  - **Integration of survivorship care and care plan within 1 year, complementary to ongoing involvement from a head and neck oncologist (See NCCN Guidelines for Survivorship)[3]**
  - **Additional health monitoring and immunizations should be performed as indicated under the care of a primary care physician**

[a] Most recurrences are reported by the patient.
[b] For mucosal melanoma and paranasal sinus cancers, a physical exam should include endoscopic inspection for paranasal sinus disease.
[c] Principles of Oral/Dental Evaluation and Management (DENT-A).
[d] Principles of Nutrition: Management and Supportive Care (NUTR-A).
[e] All patients who currently smoke should be advised to quit smoking, and those who formerly smoked should be advised to remain abstinent from smoking. For additional cessation support, refer to the Smoking Cessation and Treatment Resources in the NCCN Guidelines for Smoking Cessation.

[1] VanKoevering KK, Sabetsarvestani K, Sullivan SE, et al. Pituitary dysfunction after radiation for anterior skull base malignancies: Incidence and screening. J Neurol Surg B Skull Base 2020;81:75-81.
[2] Carpenter DJ, Patel P, Niedzwiecki D, et al. Long-term risk of carotid stenosis and cerebrovascular disease after radiation therapy for head and neck cancer. Cancer 2025;131:e35089.
[3] Cohen EE, LaMonte SJ, Erb NL, et al. American Cancer Society Head and Neck Cancer Survivorship Care Guideline. CA Cancer J Clin 2016;66:203-239.

Note: All recommendations are category 2A unless otherwise indicated.

Version 1.2026, 12/08/2025 © 2025 National Comprehensive Cancer Network® (NCCN®), All rights reserved. NCCN Guidelines® and this illustration may not be reproduced in any form without the express written permission of NCCN.

PLEASE NOTE that use of this NCCN Content is governed by the End-User License Agreement, and you MAY NOT distribute this Content or use it with any artificial intelligence model or tool.
Printed by Galya Basol Kochav on 1/4/2026 9:40:35 AM. Copyright © 2026 National Comprehensive Cancer Network, Inc. All Rights Reserved.

FOLLOW-UP RECOMMENDATIONS POST SYSTEMIC THERAPY/RT OR RT NECK EVALUATION[f]

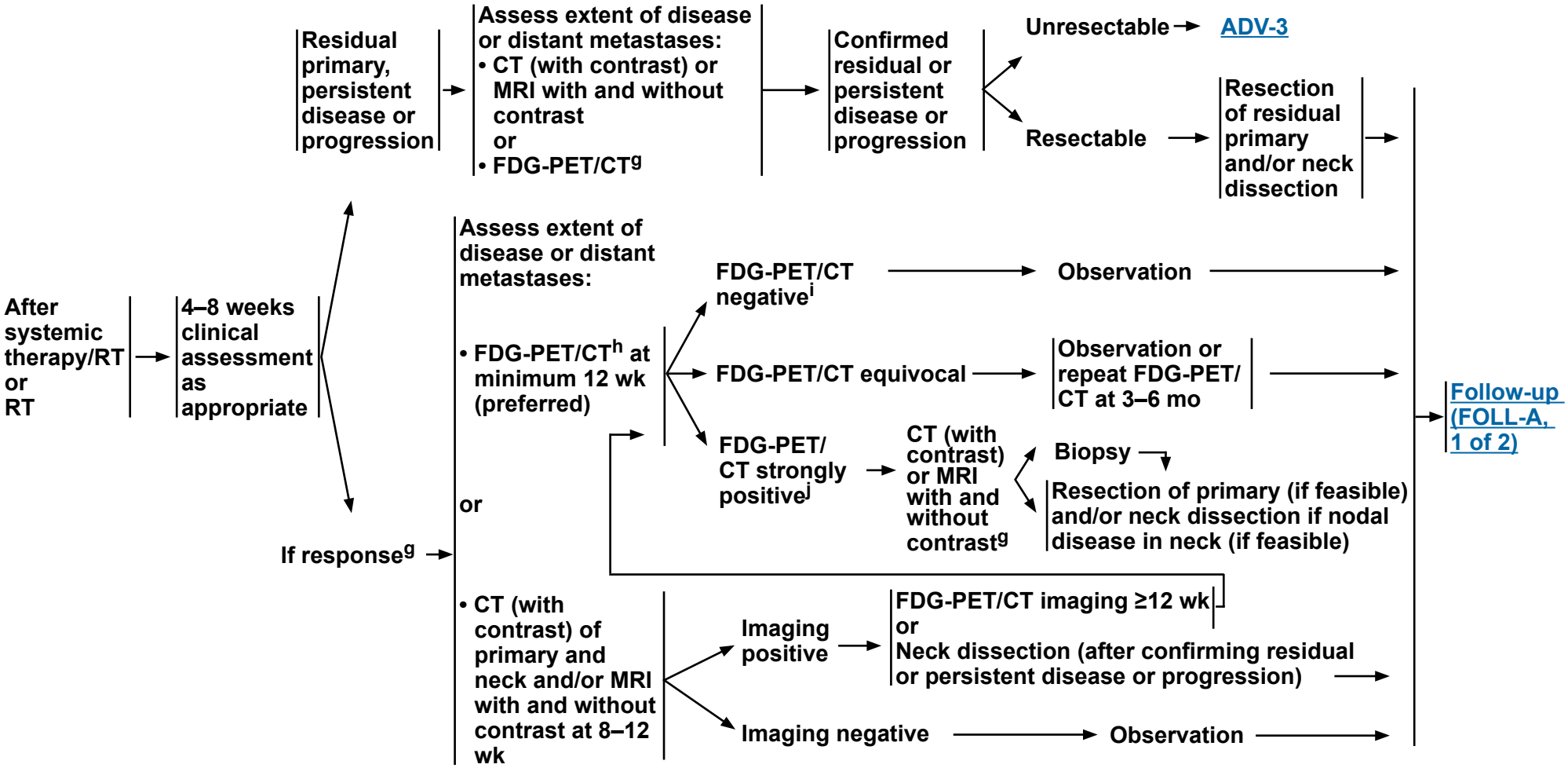

[f] Adapted with permission from Kutler DI, Patel SG, Shah JP. The role of neck dissection following definitive chemoradiation. Oncology 2004;18:993-998.
[g] Principles of Imaging (IMG-A).

[h] If an FDG-PET/CT is performed and negative for suspicion of persistent cancer, further cross-sectional imaging is optional.
[i] PET negative = No or low-grade uptake, felt not suspicious for disease.
[j] PET positive = PET suspicious for disease.

Note: All recommendations are category 2A unless otherwise indicated.

Version 1.2026, 12/08/2025 © 2025 National Comprehensive Cancer Network® (NCCN®), All rights reserved. NCCN Guidelines® and this illustration may not be reproduced in any form without the express written permission of NCCN.

PLEASE NOTE that use of this NCCN Content is governed by the End-User License Agreement, and you MAY NOT distribute this Content or use it with any artificial intelligence model or tool.
Printed by Galya Basol Kochav on 1/4/2026 9:40:35 AM. Copyright © 2026 National Comprehensive Cancer Network, Inc. All Rights Reserved.

PRINCIPLES OF IMAGING

- **Imaging plays an essential role in the clinical care of patients with head and neck cancer. The proper selection and utilization of imaging studies is critical in caring for patients with head and neck cancer.**
- **CT is performed with contrast. CT imaging of the chest can be performed with or without contrast, as clinically indicated. MRI is performed with and without contrast, unless contraindicated.**

Initial Workup

- **Primary Site:**
  - **Imaging assessment of primary site can be performed with CT of the soft tissues of the neck or MRI of the neck.**
  - **CT is complementary to MRI for head and neck cancers:**
    - ◊ **To evaluate cortical bone erosion or periosteal invasion**
    - ◊ **To evaluate bony erosion/destruction**
  - **MRI is preferred over CT for the following conditions:**
    - ◊ **If there is a need to evaluate the extent of bone marrow invasion or in patients with extensive dental amalgam that may obscure the anatomy on CT**
    - ◊ **To assess skull base invasion, cranial nerve involvement, and perineural tumor spread**
      - **– As a dedicated larynx protocol study for equivocal cartilage penetration on CT**
    - ◊ **To evaluate skull base or intracranial or orbital invasion, and to differentiate tumor from obstructed sinuses**
    - ◊ **If there are cranial nerve symptoms or if radiographic perineural tumor spread is a possibility**
  - **To achieve complete evaluation of the primary and any nodal disease, CT or MRI of the neck should image the anatomy from the skull base to the thoracic inlet. For certain conditions, such as involved lymph nodes in the low neck or cancers that frequently involve the upper mediastinum (such as thyroid cancer), the imaging should extend to the carina. When mediastinal nodes must be evaluated (eg, for thyroid carcinoma), recommend obtaining a contrast enhanced CT scan in addition to the neck CT.**
  - **If imaging does not reveal an obvious primary, PET/CT should be ordered before EUA, biopsies, and tonsillectomy to help identify potential primary sites before any intervention occurs. In addition, FNA biopsy of metastatic or equivocal nodes may be pathologically informative. Image-guided (US or CT) needle biopsy of cystic neck nodes may offer better diagnostic yield than FNA by palpation alone for initial diagnosis in this setting.**
  - **Panoramic dental x-ray is recommended for oral cavity cancers requiring mandibulotomy and/or mandibulectomy. When postoperative RT is anticipated (including such sites as the lip, other oral cavity subsites, or the oropharynx), panoramic x-ray is part of a comprehensive pre-radiation dental evaluation to assess the health of the affected dentition and determine if pre-radiation dental procedures or extractions are needed.**

Note: All recommendations are category 2A unless otherwise indicated.

Version 1.2026, 12/08/2025 © 2025 National Comprehensive Cancer Network® (NCCN®), All rights reserved. NCCN Guidelines® and this illustration may not be reproduced in any form without the express written permission of NCCN.

PLEASE NOTE that use of this NCCN Content is governed by the End-User License Agreement, and you MAY NOT distribute this Content or use it with any artificial intelligence model or tool.
Printed by Galya Basol Kochav on 1/4/2026 9:40:35 AM. Copyright © 2026 National Comprehensive Cancer Network, Inc. All Rights Reserved.

PRINCIPLES OF IMAGING

Initial Workup (continued)

- **Nodal Metastases**
  - **Evaluation of lymph node metastases should be conducted with CT or MRI of the neck, using whichever imaging study is suitable for primary site evaluation (IMG-A, 1 of 4).**
  - **For patients with multistation or lower neck nodal involvement or high-grade tumor histology, consider CT of the chest to assess for mediastinal lymph node metastases or FDG-PET/CT, which is associated with higher sensitivity for both nodal and distant metastases.**
  - **For patients who are under consideration for a surgical primary approach, the higher sensitivity of FDG-PET/CT is warranted for tumors approaching the midline, to determine the surgical approach to the contralateral neck. Similarly, patients who are scheduled for a definitive RT approach may benefit from the higher sensitivity of FDG-PET/CT for identifying involved lymph nodes.**

- **Distant Metastases**
  - **For patients with locoregionally advanced cancer (eg, T3–T4 primary or ≥N1 nodal staging), FDG-PET/CT[a] is preferred to evaluate for distant disease and thoracic metastases. However, FDG-PET/CT cannot rule out brain metastasis, and for cancers where this is a concern, such as mucosal melanoma or high-grade neuroendocrine carcinomas or adenocarcinomas, contrast-enhanced brain MRI should be additionally obtained.**
  - **If FDG-PET/CT is not performed, CT of the chest should be performed to assess for presence of pulmonary metastases as well as mediastinal lymph node involvement.**
  - **Low-dose CT of the chest can be sufficient to screen for lung parenchymal metastases but is not adequate for assessment of mediastinal adenopathy. This is an appropriate lung cancer screening intervention for patients with a history of smoking. See NCCN Guidelines for Lung Cancer Screening.**
  - **Following primary definitive treatment (surgery, RT, or systemic therapy/RT) the role of annual CT screening for lung metastasis is controversial. While this approach does detect early metastasis, further study is needed to determine the extent of the positive effect and/or cost-effectiveness of this approach in specific subpopulations and timepoints post-treatment. For patients with a substantial smoking history or who are at high risk for lung metastases, annual chest CT can be considered. Historically, annual chest x-ray has been obtained but this is a much less sensitive test than CT.**
  - **If clinical concern for metastatic disease is confined to a specific anatomical area, the assessment of distant disease can be performed with directed CT or MRI examination. For example, pulmonary metastasis can be followed and assessed by non-contrast chest CT, or spinal metastasis can be followed and assessed by contrast-enhanced spine MRI. The frequency of such imaging tests depends on the planned treatment regimen and type of cancer.**
  - **FDG-PET/CT may complement or replace other imaging modalities when staging recurrent disease before any therapy for relapsed/refractory disease in order to explore distant disease or second primaries that may significantly impact choice of therapy.[1]**

[a] PET/CT is preferred over PET scan alone (ie, without superimposed CT scan). PET/CT provides more accurate anatomical localization of abnormalities.

[1] Pantvaidya GH, Agarwal JP, Deshpande MS, et al. PET-CT in recurrent head neck cancers: a study to evaluate impact on patient management. J Surg Oncol 2009;100:401-403.

Note: All recommendations are category 2A unless otherwise indicated.

Version 1.2026, 12/08/2025 © 2025 National Comprehensive Cancer Network® (NCCN®), All rights reserved. NCCN Guidelines® and this illustration may not be reproduced in any form without the express written permission of NCCN.

PLEASE NOTE that use of this NCCN Content is governed by the End-User License Agreement, and you MAY NOT distribute this Content or use it with any artificial intelligence model or tool.
Printed by Galya Basol Kochav on 1/4/2026 9:40:35 AM. Copyright © 2026 National Comprehensive Cancer Network, Inc. All Rights Reserved.

PRINCIPLES OF IMAGING

Locoregionally Advanced Disease: <6 Months Post-Treatment (Short-Term)

- **Following surgery in patients with locoregionally advanced cancer, short-term post-treatment imaging is recommended for those who show signs of early recurrence or who are at high risk of early recurrence prior to starting adjuvant postoperative therapy.**
- **Obtain CT and/or MRI within 3–4 months after surgical treatment for patients with locoregionally advanced disease or with altered anatomy causing challenging physical exam assessment, in order to establish a new baseline for future comparisons.**
- **In cases of concern for non-response or disease progression, a CT or MRI scan may be obtained much earlier, such as 4–8 weeks post-treatment or even immediately based on the specific clinical situation. US of the neck for targeted sampling of any suspicious tissues may also be helpful, but results can be variably interpreted depending on the specific clinical situation.**
  - **Early CT/MRI scans before 8 weeks are associated with significant false-positive rates and should be avoided in the absence of signs of recurrence or progression.**
- **FDG-PET/CT should be performed within 3 months of definitive radiation, systemic therapy/RT, surgery, or adjuvant RT for assessment of treatment response and to identify any residual tumor.[2-5]**
  - **Early FDG-PET/CT scans before 12 weeks are associated with significant false-positive rates and should be avoided in the absence of signs of recurrence or progression.**
  - **The optimal timing of PET scans after radiation treatment appears to be at 3 months.[2,3] A second negative PET performed at 6 months after this baseline has a high negative prediction value, and radiologic assessment can be suspended for patients with asymptomatic disease.[6]**
  - **In patients receiving definitive RT-based treatment of mucosal squamous cell carcinoma with AJCC 7th edition N2–N3 nodal disease, the FDG-PET/CT surveillance approach led to fewer neck dissections and considerable cost savings compared to a routine approach of planned post-treatment neck dissection. The majority of cases studied were p16-positive oropharyngeal cancers.[4]**
- **In the special case of patients who are treated initially with induction chemotherapy prior to the initiation of definitive therapy, either CT or MRI has typically been obtained after 2–3 cycles of induction. Chest CT and/or FDG-PET/CT (with diagnostic-quality imaging of the regions of the body at risk) may be obtained if there is concern for locoregional or distant metastatic progression.**

[2] Cheung PK, Chin RY, Eslick GD. Detecting residual/recurrent head neck squamous cell carcinomas using PET or PET/CT: Systematic review and meta-analysis. Otolaryngol Head Neck Surg 2016;154:421-432.
[3] Heineman TE, Kuan EC, St John MA. When should surveillance imaging be performed after treatment for head and neck cancer? Laryngoscope 2017;127:533-534.
[4] Mehanna H, Wong WL, McConkey CC, et al. PET-CT surveillance versus neck dissection in advanced head and neck cancer. N Engl J Med 2016;374:1444-1454.
[5] Ng SP, Pollard C, 3rd, Berends J, et al. Usefulness of surveillance imaging in patients with head and neck cancer who are treated with definitive radiotherapy. Cancer 2019;125:1823-1829.
[6] McDermott M, Hughes M, Rath T, et al. Negative predictive value of surveillance PET/CT in head and neck squamous cell cancer. AJNR Am J Neuroradiol. 2013;34:1632-6.

Note: All recommendations are category 2A unless otherwise indicated.

Version 1.2026, 12/08/2025 © 2025 National Comprehensive Cancer Network® (NCCN®), All rights reserved. NCCN Guidelines® and this illustration may not be reproduced in any form without the express written permission of NCCN.

PLEASE NOTE that use of this NCCN Content is governed by the End-User License Agreement, and you MAY NOT distribute this Content or use it with any artificial intelligence model or tool.
Printed by Galya Basol Kochav on 1/4/2026 9:40:35 AM. Copyright © 2026 National Comprehensive Cancer Network, Inc. All Rights Reserved.

PRINCIPLES OF IMAGING

Locoregionally Advanced Disease: ≥6 Months to 5 Years Post-Treatment (Long-Term)

- **The majority of recurrences after treatment of head and neck cancer occur in the first 2 years. Surveillance can be challenging because of altered anatomy and/or fibrosis from surgery, radiation, and/or chemotherapy. There are no consensus guidelines on the frequency and modality of routine post-treatment imaging in the asymptomatic patient. Practice varies widely across institutions.**
- **US, CT, MRI, and PET/CT all have unique advantages and disadvantages when used as surveillance imaging. There is evidence that FDG-PET/CT may be the most sensitive of these modalities. A 12-month PET has been shown to reveal recurrent or second primary cancers in approximately 10% of treated patients; a 24-month FDG-PET/CT imaging revealed these findings in approximately 5% of treated cases.[3] Most cases of asymptomatic FDG-PET/CT lesion localization occur at distant sites.[7] Whether earlier detection leads to improved disease-specific survival is not established.**
- **Standardized multi-institutional imaging-based trials are needed to clearly elucidate the value of routine imaging in the clinically asymptomatic patient. There may be little proven benefit in further imaging if the initial 3-month FDG-PET/CT scan was negative. Ho et al reported no significant difference in 3-year disease-free survival in patients undergoing imaging surveillance versus those only receiving clinical surveillance (41% vs. 46%; *P* = .91) in this setting.[8]**
- **If an FDG-PET/CT at 3 months post-treatment is negative, there are no data to support substantial benefit for further routine imaging in an asymptomatic patient with negative exam. In the absence of multi-institutional prospective data, a tailored approach to surveillance with attention to tumor type, stage, prognostic factors, symptomatology, and physical exam changes or restrictions is appropriate.**
- **US of the neck is a well-established tool for nodal surveillance. US is generally widely available, safe, fast, inexpensive, and an accurate modality for examination of the neck for any suspicious nodal disease.[9]**
- **Additional post-treatment imaging is indicated for worrisome or equivocal signs/symptoms.**
- **Routine annual imaging (repeat use of pretreatment imaging modality) may be indicated to visualize areas inaccessible to routine clinical examination (deep-seated anatomic locations or areas obscured by extensive treatment change).**

[3] Heineman TE, Kuan EC, St John MA. When should surveillance imaging be performed after treatment for head and neck cancer? Laryngoscope 2017;127:533-534.
[7] Dunsky KA, Wehrmann DJ, Osman MM, et al. PET-CT and the detection of the asymptomatic recurrence or second primary lesions in the treated head and neck cancer patient. Laryngoscope 2013;123:2161-2164.
[8] Ho AS, Tsao GJ, Chen FW, et al. Impact of positron emission tomography/computed tomography surveillance at 12 and 24 months for detecting head and neck cancer recurrence. Cancer 2013;19:1349-1356.
[9] Paleri V, Urbano TG, Mehanna H, et al. Management of neck metastases in head and neck cancer: United Kingdom National Multidisciplinary Guidelines. J Laryngol Otol 2016;130:S161-S169.

Note: All recommendations are category 2A unless otherwise indicated.

Version 1.2026, 12/08/2025 © 2025 National Comprehensive Cancer Network® (NCCN®), All rights reserved. NCCN Guidelines® and this illustration may not be reproduced in any form without the express written permission of NCCN.

PLEASE NOTE that use of this NCCN Content is governed by the End-User License Agreement, and you MAY NOT distribute this Content or use it with any artificial intelligence model or tool.
Printed by Galya Basol Kochav on 1/4/2026 9:40:35 AM. Copyright © 2026 National Comprehensive Cancer Network, Inc. All Rights Reserved.

PRINCIPLES OF SURGERY

Evaluation

All patients should be evaluated by a head and neck surgical oncologist prior to treatment to ensure the following:

- **Review the adequacy of biopsy material, review staging and imaging to determine the extent of disease, exclude the presence of a synchronous primary tumor, assess current functional status, and evaluate for potential surgical options, including those applicable if initial nonsurgical treatment is unsuccessful.**
- **Pre-treatment evaluation should include consultations with a medical oncologist, radiation oncologist, dentist or oral maxillofacial surgeon, speech-language pathologist, dietitian, and reconstructive surgeon as appropriate.**
- **Tumor staging for untreated patients is essential based on review of the head and neck diagnostic imaging studies and chest imaging as appropriate.**
- **In addition to the office-based head and neck examination to include fiberoptic nasopharyngolaryngoscopy, EUA to assess the tumor extent and to obtain a biopsy is indicated. In the setting of metastatic carcinoma to the neck an EUA to search for the putative primary site is important for diagnosis and treatment planning.**
- **Participate in the multidisciplinary team discussions regarding patient treatment options with the goal of maximizing survival with preservation of form and function.**
- **Develop a prospective surveillance plan that includes adequate dental, nutritional, and health behavioral evaluation and intervention and any other ancillary evaluations that would provide for comprehensive rehabilitation.**

Integration of Therapy

- **It is critical that multidisciplinary evaluation and treatment be coordinated and integrated prospectively by all disciplines involved in patient care before the initiation of any treatment.**
- **For patients undergoing an operation, the surgical procedure, margins, and reconstructive plan should be developed and designed to resect all gross tumors with adequate tumor-free surgical margins. The surgical procedure should rarely be modified based on any response observed as a result of prior therapy except in instances of tumor progression that mandate a more extensive procedure in order to encompass the tumor at the time of definitive resection.**
- **Once the multidisciplinary team has established a proposed treatment regimen, the responsible physician and a member of the team should discuss the recommendations in detail with the patient to include the risks, benefits, and potential outcomes. The patient should be offered the opportunity to participate in the final decision (shared decision-making).**

Note: All recommendations are category 2A unless otherwise indicated.

Version 1.2026, 12/08/2025 © 2025 National Comprehensive Cancer Network® (NCCN®), All rights reserved. NCCN Guidelines® and this illustration may not be reproduced in any form without the express written permission of NCCN.

PLEASE NOTE that use of this NCCN Content is governed by the End-User License Agreement, and you MAY NOT distribute this Content or use it with any artificial intelligence model or tool.
Printed by Galya Basol Kochav on 1/4/2026 9:40:35 AM. Copyright © 2026 National Comprehensive Cancer Network, Inc. All Rights Reserved.

PRINCIPLES OF SURGERY

Special Considerations: Suspected HPV-Associated Metastatic Squamous Cell Carcinoma to the Neck

- **Often, the patient's first presenting sign of oropharyngeal squamous cell carcinoma (OPSCC) is a neck mass. Commonly, the primary is small and asymptomatic and may not be detectable on inspection, palpation, fiberoptic examination, or imaging of the oropharynx. It is incumbent upon the treating physician or surgeon to diligently search for and pathologically confirm the primary site, which is usually located in the base of tongue or tonsil.**
- **Information obtained from a thorough workup evaluation is vital to enable the multidisciplinary team to develop a comprehensive and focused treatment plan individualized to the patient. Identification of the primary site will either permit definitive transoral surgery to remove the primary disease or permit focused radiation, thus sparing adjacent sites in the oropharynx. As therapy becomes more personalized, biomarker assessment of the primary tumor may be instrumental in determining a patient's eligibility for a clinical trial or adjuvant therapy.**
- **Cross-sectional imaging should be performed to facilitate identification of the primary site, followed by direct examination and confirmatory biopsies.**
- **EUA and confirmatory biopsies for patients with suspected OPSCC should be performed before beginning therapy. EUA may entail unilateral or bilateral biopsies of suspicious areas in the oropharynx. Palatine tonsillectomies may reveal a small primary tumor. Lingual tonsillectomy may be considered if biopsies and palatine tonsils are negative for tumor. Bilateral palatine and lingual tonsillectomies are ill-advised as they may lead to swallowing morbidity.**
- **FNA biopsy of the neck mass, often performed under US guidance, will usually establish the diagnosis of metastatic carcinoma. A definitive cytologic diagnosis of squamous cell carcinoma is highly accurate, and further assessment of immunostaining for p16 can support the diagnosis of HPV-associated OPSCC in the presence of an oropharyngeal primary tumor. See Principles of p16 Testing for HPV-Mediated Oropharyngeal Cancer (ORPH-B). If there is any uncertainty, a core biopsy under image guidance can be performed. Rarely is an open excisional biopsy of the suspected metastatic node necessary for definitive diagnosis. The surgeon should be prepared to perform a neck dissection at the time of open biopsy if frozen section confirms squamous cell carcinoma. In select occult primary cases with p16-positive nodal metastasis, confirmation with HPV ISH/PCR testing is recommended.**

Assessment of Resectability

Tumor involvement of the following sites is associated with poor prognosis or function[a] or with T4b cancer (ie, unresectable based on technical ability to obtain clear margins). None of these sites of involvement is an absolute contraindication to resection in selected patients in whom total cancer removal is possible:

- **Involvement of the pterygoid muscles, particularly when associated with severe trismus or pterygopalatine fossa involvement with cranial neuropathy[a];**
- **Gross extension of the tumor to the skull base (eg, erosion of the pterygoid plates or sphenoid bone, widening of the foramen ovale);**
- **Direct extension to the superior nasopharynx or deep extension into the Eustachian tube and lateral nasopharyngeal walls;**
- **Invasion (encasement) of the common or internal carotid artery;**
- **Direct extension of neck disease to involve the external skin[a];**
- **Direct extension to mediastinal structures, prevertebral fascia, or cervical vertebrae; and[a]**
- **Presence of subdermal metastases.**

[a] In selected cases, surgery might still be considered.

Note: All recommendations are category 2A unless otherwise indicated.

Version 1.2026, 12/08/2025 © 2025 National Comprehensive Cancer Network® (NCCN®), All rights reserved. NCCN Guidelines® and this illustration may not be reproduced in any form without the express written permission of NCCN.

PLEASE NOTE that use of this NCCN Content is governed by the End-User License Agreement, and you MAY NOT distribute this Content or use it with any artificial intelligence model or tool.
Printed by Galya Basol Kochav on 1/4/2026 9:40:35 AM. Copyright © 2026 National Comprehensive Cancer Network, Inc. All Rights Reserved.

PRINCIPLES OF SURGERY

Primary Tumor Resection

The resection of advanced tumors of the oral cavity, oropharynx, hypopharynx, larynx, or paranasal sinus will vary in extent depending on the structures involved. The primary tumor should be considered surgically curable by appropriate resection using accepted criteria for adequate excision, depending on the region involved.

- En bloc resection of the primary tumor should be attempted whenever feasible.
- In-continuity neck dissection is necessary when there is direct extension of the primary tumor into the neck.
- Resection should be planned based on the extent of the primary tumor as ascertained by clinical examination and careful interpretation of appropriate radiographic images.
- For oral cavity cancers, as depth of invasion increases, the risk of regional metastases and the need for adjuvant elective neck dissection also increases.
- Perineural invasion should be suspected when tumors are adjacent to motor or sensory nerves. The goal is total cancer resection. When gross invasion is present and the nerve can be resected without significant morbidity, the nerve should be dissected both proximally and distally and should be resected to obtain clearance of disease (Surgical Management of Cranial Nerves [SURG-A, 5 of 9]). Frozen section determination of the proximal and distal nerve margins may prove helpful to facilitate tumor clearance.
- Partial or segmental resection of the mandible may be necessary to adequately encompass the cancer with adequate tumor-free margins. Adequate resection may require partial, horizontal, or sagittal resection of the mandible for tumors involving or adherent to mandibular periosteum. Segmental or marginal resection should be considered in tumors that grossly involve mandibular periosteum (as determined by tumor fixation to the mandible) or show evidence of direct tumor involvement of the bone at the time of operation or through preoperative imaging (CT or MRI). A Panorex may be useful for assessing mandibular height when a marginal or coronal mandibulectomy is a consideration. In the patient with complete edentulism due to mandibular atrophy that occurs over time, a partial mandibulectomy may not be possible. The extent of mandibular resection will depend on the degree of involvement accessed clinically and in the operating room.
- Medullary space invasion is an indication for segmental resection. Frozen section examination of available marrow may be considered to guide resection.
- For tumors of the larynx, the decision to perform either total laryngectomy or conservation laryngeal surgery (eg, transoral resection, hemilaryngectomy, supracricoid partial laryngectomy, supraglottic laryngectomy) will be decided by the surgeon and the patient but should adhere to the principles of complete tumor extirpation with curative intent and function preservation. Partial laryngeal surgery should be avoided if adjuvant RT is likely following surgery. For T4 or N2–3 laryngeal cancers treated with surgery, consideration should be given to thyroidectomy for tumor clearance and clearance of central compartment pretracheal or paratracheal nodes. Consider the risks and benefits versus improved locoregional control.[1,2]
- Transoral robotic surgery (TORS) or laser-assisted resections of primary cancers of the larynx and pharynx are increasingly used approaches for cancer resection in selected patients with accessible tumors. Oncologic principles are similar to open procedures. Successful application of these techniques requires specialized skills and experience. Postoperative hemorrhage can be a major and rarely life-threatening complication. It is incumbent upon the TORS surgeon to use appropriate surgical strategies to diminish the risk of postoperative hemorrhage.
- In oropharyngeal cancer cases (whether HPV positive or negative) treatment selection should favor usage of fewest modalities necessary in order to minimize treatment-related toxicity and preserve function. Avoid triple modality treatment when possible. Patients with fixed nodes are not appropriate candidates for upfront definitive surgery.

References

Note: All recommendations are category 2A unless otherwise indicated.

Version 1.2026, 12/08/2025 © 2025 National Comprehensive Cancer Network® (NCCN®), All rights reserved. NCCN Guidelines® and this illustration may not be reproduced in any form without the express written permission of NCCN.

PLEASE NOTE that use of this NCCN Content is governed by the End-User License Agreement, and you MAY NOT distribute this Content or use it with any artificial intelligence model or tool.
Printed by Galya Basol Kochav on 1/4/2026 9:40:35 AM. Copyright © 2026 National Comprehensive Cancer Network, Inc. All Rights Reserved.

PRINCIPLES OF SURGERY

Margins

An overarching goal of oncologic surgery is complete tumor resection with histologic verification of tumor-free margins. Margin assessment may be done in real time by frozen section or by assessment of formalin-fixed tissues. Tumor-free margins are an essential surgical strategy for diminishing the risk for local tumor recurrence. Conversely, positive margins increase the risk for local relapse and are an indication for postoperative adjuvant therapy. Clinical pathologic studies have demonstrated the significance of close or positive margins and their relationship with local tumor recurrence.[3] When there is an initial cut-through with an invasive tumor at the surgical margin, obtaining additional adjacent margins from the patient may also be associated with a higher risk for local relapse and should be described in the operative report. Obtaining additional margins from the patient is subject to ambiguity regarding whether the tissue taken from the surgical bed corresponds to the actual site of margin positivity.[4] If positive surgical margins are reported, re-resection and/or adjuvant therapy should be considered in selected patients.

Frozen section margin assessment is always at the discretion of the surgeon and should be considered when it will facilitate complete tumor removal. The achievement of adequate wide margins may require resection of an adjacent structure in the oral cavity or laryngopharynx such as the base of the tongue and/or anterior tongue, mandible, larynx, or portions of the cervical esophagus.

- Adequate resection is defined as clear resection margins with at least enough clearance from the gross tumor to obtain clear frozen section and permanent margins (often 1.0–1.5 cm of visible and palpable normal mucosa). However, for glottic cancers, a 1- to 2-mm margin is considered adequate. In general, frozen section examination of the margins will usually be undertaken intraoperatively, and, importantly, when a line of resection has uncertain clearance because of indistinct tumor margins, or there is suspected residual disease (ie, soft tissue, cartilage, carotid artery, mucosal irregularity). In transoral endoscopic and robotic approaches for oropharynx cancers, margins of 1.5–2.0 mm may be acceptable, but the data are based on retrospective studies and caution is indicated.[5] Such margins would be considered "close" and are inadequate for certain sites such as oral tongue.
- The details of resection margins should be included in the operative dictation. The margins may be assessed on the resected specimen or alternatively from the surgical bed with proper orientation. Adequacy of the margins may vary by site. For a glottic cancer 1- to 2-mm margins are sufficient but inadequate for an invasive carcinoma of the oral tongue.
- At this time there is no universal definition for what constitutes a clear/close margin.
- Distance in mm to achieve clinically acceptable margins is influenced by tumor primary site, histology, and HPV status in oropharyngeal cancer and following neoadjuvant therapy.
- The previous universally followed definition of adequate margin (5 mm in final histopathology) has been disputed.[6,7]
- A positive margin is defined as carcinoma in situ or as invasive carcinoma at the margin of resection. If carcinoma in situ is present and if additional margins can be obtained that is the favored approach. Carcinoma in situ should not be considered an indication for concurrent postoperative systemic therapy/RT.
- The primary tumor should be marked in a fashion adequate for orientation by the surgical pathologist. The primary tumor should be assessed histologically for depth of invasion and for distance from the invasive portion of the tumor to the margin of resection, including the peripheral and deep margins. The pathology report should be template-driven and describe how the margins were assessed. The report should provide information regarding the primary specimen to include the distance from the invasive portion of the tumor to the peripheral and deep margin. If the surgeon obtains additional margins from the patient, the new margins should refer back to the geometric orientation of the resected tumor specimen with a statement by the pathologist that this is the final margin of resection and its histologic status.
- The neck dissection should be oriented or sectioned in order to identify levels of lymph nodes encompassed in the dissection.
- Reconstruction of surgical defects should be performed using conventional techniques at the discretion of the surgeon. Primary closure is recommended when appropriate but should not be pursued at the expense of obtaining wide, tumor-free margins. Reconstructive closure with locoregional flaps, free-tissue transfer, or split-thickness skin or other grafts with or without mandibular reconstruction is performed at the discretion of the surgeon. To improve efficiency and address both oncologic and reconstructive goals, a two-team approach is advisable.

References

Note: All recommendations are category 2A unless otherwise indicated.

Version 1.2026, 12/08/2025 © 2025 National Comprehensive Cancer Network® (NCCN®), All rights reserved. NCCN Guidelines® and this illustration may not be reproduced in any form without the express written permission of NCCN.

PLEASE NOTE that use of this NCCN Content is governed by the End-User License Agreement, and you MAY NOT distribute this Content or use it with any artificial intelligence model or tool.
Printed by Galya Basol Kochav on 1/4/2026 9:40:35 AM. Copyright © 2026 National Comprehensive Cancer Network, Inc. All Rights Reserved.

PRINCIPLES OF SURGERY

Surgical Management of Cranial Nerves VII, X (including the recurrent laryngeal nerve), XI, and XII

Operative management of the facial nerve and other major cranial nerves during primary or regional node resection is influenced by the preoperative clinical function of the nerve.

- **When the nerve is functioning, thorough efforts should be made to preserve the structure and function of the nerve (main trunk and/or branches)—even if otherwise adequate tumor margins are not achieved—recognizing that the surgeon should leave no gross residual disease.**
- **Adjuvant postoperative radiation or systemic therapy/RT is generally prescribed when a microscopic residual or gross residual tumor is suspected.**
- **Direct nerve invasion by a tumor and/or preoperative paralysis of the nerve may warrant segmental resection (and sometimes nerve grafting) at the discretion of the surgeon if tumor-free margins are ensured throughout the remainder of the procedure.**

Note: All recommendations are category 2A unless otherwise indicated.

Version 1.2026, 12/08/2025 © 2025 National Comprehensive Cancer Network® (NCCN®), All rights reserved. NCCN Guidelines® and this illustration may not be reproduced in any form without the express written permission of NCCN.

PLEASE NOTE that use of this NCCN Content is governed by the End-User License Agreement, and you MAY NOT distribute this Content or use it with any artificial intelligence model or tool.
Printed by Galya Basol Kochav on 1/4/2026 9:40:35 AM. Copyright © 2026 National Comprehensive Cancer Network, Inc. All Rights Reserved.

PRINCIPLES OF SURGERY

Neck Management

The surgical management of regional lymphatics is dictated by the extent of the tumor at initial tumor staging. These guidelines apply to the performance of neck dissections as part of treatment of the primary tumor. In general, patients undergoing surgery for resection of the primary tumor will undergo dissection of the ipsilateral side of the neck that is at greatest risk for metastases.

- Tumor sites that frequently have bilateral lymphatic drainage (eg, base of tongue, palate, supraglottic larynx, hypopharynx, nasopharynx, deep pre-epiglottic space involvement) often should have both sides of the neck dissected with the extent of dissection determined as suggested below. For those patients with tumors at or approaching the midline, both sides of the neck are at risk for metastases, and bilateral neck dissections should be performed.

Patients with advanced lesions involving the anterior tongue, floor of the mouth, or alveolus that approximate or cross the midline should undergo contralateral selective/modified neck dissection as necessary to achieve adequate tumor resection.

- Elective neck dissection should be based on risk of occult metastasis in the appropriate nodal basin. For oral cavity squamous cell carcinoma, SLN biopsy or the primary tumor depth of invasion is currently the best predictor of occult metastatic disease and should be used to guide decision-making. For tumors with a depth >3 mm, elective dissection should be strongly considered if RT is not already planned. Recent randomized trial evidence supports the effectiveness of elective neck dissection in patients with oral cavity cancers >3 mm in depth of invasion.[8] For a depth <2 mm, elective dissection is only indicated in highly selective situations. For a depth of 2–4 mm, clinical judgment (as to reliability of follow-up, clinical suspicion, and other factors) must be utilized to determine appropriateness of elective dissection. Elective dissections are generally selective, preserving all major structures, unless operative findings dictate otherwise.
- The type of neck dissection (comprehensive or selective) is defined according to preoperative clinical staging, is determined at the discretion of the surgeon, and is based on the initial preoperative staging as follows:

N0	Selective neck dissection • Oral cavity at least levels I–III • Oropharynx at least levels II–IV • Hypopharynx at least levels II–IV and level VI when appropriate • Larynx at least levels II–IV and level VI when appropriate
N1–N2a–c	Selective or comprehensive neck dissection (Discussion)
N3	Comprehensive neck dissection

- Level VI neck dissections are performed for certain primary sites (such as the larynx and hypopharynx) as required to resect the primary tumor and any clinically evident neck nodes. Elective dissection depends on primary tumor extent and site. For advanced glottic and hypopharyngeal cancers treated with primary surgery, a level VI dissection (including pretracheal lymph nodes, the Delphian lymph node, and unilateral or bilateral paratracheal lymph nodes) and hemithyroidectomy to total thyroidectomy are appropriate. For primary subglottic tumors or glottic cancers with significant subglottic extension, a level VI dissection with unilateral or total thyroidectomy is considered appropriate based on the extent of the primary tumor. For example, a T4a glottic tumor with extension through the cricothyroid membrane and subglottic extension should include thyroidectomy and pretracheal and bilateral paratracheal lymph node dissection. Parathyroid glands should be preserved in situ or auto transplanted as indicated.

References

Note: All recommendations are category 2A unless otherwise indicated.

Version 1.2026, 12/08/2025 © 2025 National Comprehensive Cancer Network® (NCCN®), All rights reserved. NCCN Guidelines® and this illustration may not be reproduced in any form without the express written permission of NCCN.

PLEASE NOTE that use of this NCCN Content is governed by the End-User License Agreement, and you MAY NOT distribute this Content or use it with any artificial intelligence model or tool.
Printed by Galya Basol Kochav on 1/4/2026 9:40:35 AM. Copyright © 2026 National Comprehensive Cancer Network, Inc. All Rights Reserved.

PRINCIPLES OF SURGERY

Sentinel Lymph Node Biopsy

- SLN biopsy is an alternative to elective neck dissection for identifying occult cervical metastasis in patients with early (T1 or T2) oral cavity carcinoma in centers where expertise for this procedure is available. Technical experience and judgment are required for successful execution of lymphatic mapping and SLN. Its advantages include reduced morbidity and an improved cosmetic outcome. Rates of detection of sentinel nodes in excess of 95% have been widely reported.[9-11] Patients with metastatic disease in their sentinel nodes must undergo a completion neck dissection while those without may be observed. Accuracy of sentinel node biopsy for nodal staging of early oral carcinoma has been tested extensively in multiple single-center studies and two multi-institutional trials against the reference standard of immediately performed neck dissection or subsequent extended follow-up with a pooled estimate of sensitivity of 0.93 and negative predictive values ranging from 0.88 to 1.[8,10-14] While direct comparisons with the policy of elective neck dissection are lacking, available evidence points towards comparable survival outcomes.[8]
- Sentinel node biopsy is a technically demanding procedure. Procedural success rates for sentinel node identification as well as accuracy of detecting occult lymphatic metastasis depend on technical expertise and experience. Hence, sufficient caution must be exercised when offering it as an alternative to elective neck dissection. This is particularly true in cases of floor-of-mouth cancer where accuracy of sentinel node biopsy has been found to be lower than for other locations such as the tongue.[8,9] Also, cancers of certain locations such as upper gingiva and hard palate may not lend themselves well technically to this procedure. Likewise, occult cervical metastases are uncommon in early lip cancer, but SLN biopsy has been shown to be feasible and effective in patients with lip cancers deemed to be at high risk of metastases generally based on tumor size or depth.[15]

Palliative Surgery

- Curative treatment of head and neck cancers can lead to unwanted side effects such as scarring and stiffness of soft tissues, soft tissue and bone necrosis, chronic infection and tissue breakdown, pain, dysphagia, and aspiration pneumonia. These ill effects are challenging to manage and treat. Persistent cancer or recurrent disease can further complicate management. Concurrent palliative care for symptom management is necessary to support quality of life during and following treatment. Examples of such include tracheostomy for insufficient airway and respiratory distress, and gastrostomy for nutritional support in patients with dysphagia and aspiration risk. There may be a need for surgical removal of damaged and dysfunctional tissues and necessary defect reconstruction with transfer of healthy vascularized tissues to promote healing. Examples of surgery for symptom palliation include mandibulectomy for osteoradionecrosis of the mandible and reconstruction with osteocutaneous microvascular free-flap and/or functional laryngectomy and pharyngoplasty for a dysfunctional larynx with significant aspiration following radiation-based larynx preservation treatment. It is imperative to assess patients with head and neck cancer through the entire cancer diagnosis and treatment continuum for functional capacity and quality of life. Judicious surgical interventions may play a critical role in symptom palliation and wellness through both survivorship and end of life.

References

Note: All recommendations are category 2A unless otherwise indicated.

Version 1.2026, 12/08/2025 © 2025 National Comprehensive Cancer Network® (NCCN®), All rights reserved. NCCN Guidelines® and this illustration may not be reproduced in any form without the express written permission of NCCN.

PLEASE NOTE that use of this NCCN Content is governed by the End-User License Agreement, and you MAY NOT distribute this Content or use it with any artificial intelligence model or tool.
Printed by Galya Basol Kochav on 1/4/2026 9:40:35 AM. Copyright © 2026 National Comprehensive Cancer Network, Inc. All Rights Reserved.

PRINCIPLES OF SURGERY

Management of Recurrences

Resectable primary cancers should be re-resected with curative intent if feasible, and recurrences in a previously treated neck should undergo surgery as well. Neck disease in an untreated neck should be addressed by formal neck dissection or modification depending on the clinical situation. Non-surgical therapy may also be utilized as clinically appropriate.

Surveillance

All patients should have regular follow-up visits to assess for symptoms and possible tumor recurrence, health behaviors, nutrition, dental health, and speech and swallowing function.

- **Tumor evaluations must be performed by specialists skilled in head and neck clinical examination.**
- **The frequency of evaluation is summarized elsewhere in the NCCN Guidelines for Head and Neck Cancers.**
  - **Follow-up Recommendations (FOLL-A 1 of 2)**
  - **Principles of Imaging (IMG-A)**
- **For post systemic therapy/RT or RT neck evaluations, see Follow-up Recommendations: Post Systemic Therapy/RT or RT Neck Evaluation (FOLL-A 2 of 2).**

Note: All recommendations are category 2A unless otherwise indicated.

Version 1.2026, 12/08/2025 © 2025 National Comprehensive Cancer Network® (NCCN®), All rights reserved. NCCN Guidelines® and this illustration may not be reproduced in any form without the express written permission of NCCN.

PLEASE NOTE that use of this NCCN Content is governed by the End-User License Agreement, and you MAY NOT distribute this Content or use it with any artificial intelligence model or tool.
Printed by Galya Basol Kochav on 1/4/2026 9:40:35 AM. Copyright © 2026 National Comprehensive Cancer Network, Inc. All Rights Reserved.

PRINCIPLES OF SURGERY
REFERENCES

[1] Baghel SS, Singhal P, Verma N, et al. Is thyroid excision mandatory with laryngectomy in carcinoma larynx? BMC Cancer 2020;20:700.
[2] Li SX, Polacco MA, Gosselin BJ, et al. Management of the thyroid gland during laryngectomy. J Laryngol Otol 2017;131:740-744.
[3] Looser KG, Shah JP, Strong EW. The significance of “positive” margins in surgically resected epidermoid carcinomas. Head Neck Surg 1978;1:107-111.
[4] Scholl P, Byers RM, Batsakis JG, et al. Microscopic cut-through of cancer in the surgical treatment of squamous carcinoma of the tongue. Prognostic and therapeutic implications. Am J Surg 1986;152:354-360.
[5] Haughey BH, Sinha P. Prognostic factors and survival unique to surgically treated p16+ oropharyngeal cancer. Laryngoscope 2012;122 Suppl 2:S13-S33.
[6] Fowler J, Campanile Y, Warner A, et al. Surgical margins of the oral cavity: is 5 mm really necessary? J Otolaryngol Head Neck Surg 2022;51:38.
[7] Solomon J, Hinther A, Matthews TW, et al. The impact of close surgical margins on recurrence in oral squamous cell carcinoma. J Otolaryngol Head Neck Surg 2021;50:9.
[8] D’Cruz AK, Vaish R, Kapre N, et al; Head and Neck Disease Management Group. Elective versus therapeutic neck dissection in node-negative oral cancer. N Engl J Med 2015;373:521-529.
[9] Civantos FJ, Zitsch RP, Schuller DE, et al. Sentinel lymph node biopsy accurately stages the regional lymph nodes for T1-T2 oral squamous cell carcinomas: results of a prospective multi-institutional trial. J Clin Oncol 2010;28:1395-1400.
[10] Alkureishi LW, Ross GL, Shoaib T, et al. Sentinel node biopsy in head and neck squamous cell cancer: 5-year follow-up of a European multicenter trial. Ann Surg Oncol 2010;17:2459-2464.
[11] Govers TM, Hannink G, Merkx MA, et al. Sentinel node biopsy for squamous cell carcinoma of the oral cavity and oropharynx: a diagnostic meta-analysis. Oral Oncol 2013;49:726-732.
[12] Pezier T, Nixon IJ, Gurney B, et al. Sentinel lymph node biopsy for T1/T2 oral cavity squamous cell carcinoma—a prospective case series. Ann Surg Oncol 2012;19:3528-3533.
[13] Broglie MA, Haerle SK, Huber GF, et al. Occult metastases detected by sentinel node biopsy in patients with early oral and oropharyngeal squamous cell carcinomas: impact on survival. Head Neck 2013;35:660-666.
[14] Samant S. Sentinel node biopsy as an alternative to elective neck dissection for staging of early oral carcinoma. Head Neck 2014;36:241-246.
[15] Sollamo EM, Ilmonen SK, Virolainen MS, Suominen SH. Sentinel lymph node biopsy in cN0 squamous cell carcinoma of the lip: A retrospective study. Head Neck 2016;38 Suppl 1:E1375-E1380.

Note: All recommendations are category 2A unless otherwise indicated.

Version 1.2026, 12/08/2025 © 2025 National Comprehensive Cancer Network® (NCCN®), All rights reserved. NCCN Guidelines® and this illustration may not be reproduced in any form without the express written permission of NCCN.

PLEASE NOTE that use of this NCCN Content is governed by the End-User License Agreement, and you MAY NOT distribute this Content or use it with any artificial intelligence model or tool.
Printed by Galya Basol Kochav on 1/4/2026 9:40:35 AM. Copyright © 2026 National Comprehensive Cancer Network, Inc. All Rights Reserved.

PRINCIPLES OF RADIATION TECHNIQUES[1-10]

Assessment of Radiotherapy

- **All patients should be evaluated by a radiation oncologist prior to treatment to ensure the following:**
  - **Review staging and imaging to determine the extent of disease, exclude the presence of a synchronous primary tumor, assess functional status, and evaluate for potential RT options.**
  - **Participate in the multidisciplinary team discussions regarding patient treatment options with the goal of maximizing survival with preservation of form and function.**
  - **Develop a prospective surveillance plan that includes adequate dental, swallowing, nutritional, and health behavior evaluation and intervention and any other ancillary evaluations that would provide for comprehensive rehabilitation.**

General Principles

- **Target delineation and optimal dose distribution require experience in head and neck imaging and a thorough understanding of patterns of disease spread. Standards for target definition, dose specification, fractionation (with and without concurrent chemotherapy), and normal tissue constraints are still evolving. Published contouring guidelines referenced are in regard to patients who have not been operated upon.[11,12]**
  - **IMRT (preferred) or other conformal techniques (helical tomotherapy, volumetric modulated arc therapy [VMAT], and proton beam therapy [PBT]) may be used as appropriate depending on the stage, tumor location, physician training/experience, and available physics support.[a]**
  - **Close interplay exists between radiation technology, techniques, fractionation, cumulative radiation dose, surgery, and chemotherapy options resulting in a large number of combinations that may impact toxicity or tumor control.**
  - **FDG-PET/CT or MRI with contrast can be used for fusion in treatment planning.**
- **Advanced RT technologies such as IMRT (preferred), tomotherapy, VMAT, image-guided RT (IGRT), and PBT may offer clinically relevant advantages in specific instances to spare important OARs, such as the brain, brain stem, cochlea, semicircular canals, optic chiasm and cranial nerves, retina, lacrimal glands, cornea, spinal cord, brachial plexus, mucosa, salivary glands, bone (skull base and mandible), pharyngeal constrictors, larynx, and esophagus, and decrease the risk for late, normal tissue damage while still achieving the primary goal of local tumor control.[10]**
  - **The demonstration of clinically significant dose-sparing of these OARs reflects best clinical practice.**
- **Since the advantages of these techniques include tightly conformal doses and steep gradients next to normal tissues, target definition and delineation and treatment delivery verification require careful monitoring to avoid the risk of tumor geographic miss and subsequent decrease in local tumor control.**
  - **Initial diagnostic imaging with contrast-enhanced CT, MRI, FDG-PET/CT, and other imaging modalities facilitate target definition.**
- **Image guidance is required to provide assurance of accurate daily delivery. Anatomical changes including rapidly shrinking tumors, changes in air cavities, or significant weight loss may necessitate repeat diagnostic imaging and replanning (adaptive treatment).**
- **Randomized studies to test these concepts are unlikely to be done since the above specific clinical scenarios represent complex combinations of multiple variables. In light of that, the modalities and techniques that are found best to reduce the doses to the clinically relevant OARs without compromising target coverage should be considered.**

[a] For additional resources regarding the technical details of radiation, see the American College of Radiology Guidelines: https://www.acr.org/Clinical-Resources/Practice-Parameters-and-Technical-Standards.

Note: All recommendations are category 2A unless otherwise indicated.

References

Version 1.2026, 12/08/2025 © 2025 National Comprehensive Cancer Network® (NCCN®), All rights reserved. NCCN Guidelines® and this illustration may not be reproduced in any form without the express written permission of NCCN.

PLEASE NOTE that use of this NCCN Content is governed by the End-User License Agreement, and you MAY NOT distribute this Content or use it with any artificial intelligence model or tool.
Printed by Galya Basol Kochav on 1/4/2026 9:40:35 AM. Copyright © 2026 National Comprehensive Cancer Network, Inc. All Rights Reserved.

PRINCIPLES OF RADIATION TECHNIQUES[a,9]

Techniques/Dosing

- **IMRT**
  - **IMRT is preferred in reducing long-term toxicity in oropharyngeal, nasal cavity, paranasal sinus, salivary gland, and nasopharyngeal cancers by reducing the dose to salivary glands, temporal lobes, auditory structures (including cochlea), and optic structures. IMRT is preferred for thyroid cancers because of its ability to spare the larynx, brachial plexus, and esophagus.**
  - **The application of IMRT to other sites (eg, oral cavity, larynx, hypopharynx) is preferred and may be used at the discretion of treating physicians.**
  - **Helical tomotherapy and VMAT are advanced forms of IMRT.**

- **PBT[13-33]**
  - **Achieving highly conformal dose distributions is especially important for patients: 1) whose primary tumors are periocular in location and/or invade the orbit, skull base, and/or cavernous sinus; 2) whose primary tumors extend intracranially or exhibit extensive perineural invasion; and 3) who are being treated with curative intent and/or who have long life expectancies following treatment. Nonrandomized, single-institution, clinical reports and systematic comparisons demonstrate safety and efficacy of PBT in the above-mentioned specific clinical scenarios.**
  - **Proton therapy can be considered when normal tissue constraints cannot be met by photon-based therapy, or when photon-based therapy causes compromise of standard radiation dosing to tumor or postoperative volumes.**

- **IMRT, PBT, and Fractionation[34-36]**
  - **A number of ways exist to integrate IMRT or PBT, target volume dosing, and fractionation.**
    - **The SIB technique uses differential "dose painting" (66–72 Gy to gross disease; 44–63 Gy to subclinical disease) for each fraction of treatment throughout the entire course of radiation.[4] SIB is commonly used in the conventional (5 fractions/wk) and the "6 fractions/wk accelerated" schedule.[5]**
    - **The sequential (SEQ) technique typically delivers the initial (lower dose) phase (weeks 1–5) followed by the high-dose boost volume phase (weeks 6–7) using 2–3 separate dose plans, and is commonly applied in standard fractionation and hyperfractionation.**
    - **The concomitant boost accelerated schedule may utilize a "modified SEQ" dose plan by delivering the dose to the subclinical targets once a day for 6 weeks, and a separate boost dose plan as a second daily fraction for the last 12 treatment days.[6]**
    - **Another accelerated approach, aside from concomitant boost, is to simply treat 6 fractions per week.[5]**
  - **Altered fractionation may be used for select patients with comorbidities who are not good candidates for 6–7 weeks of adjuvant RT or systemic therapy/RT.**
  - **Altered fractionation has not proven to be beneficial in the context of concurrent chemotherapy. The best available evidence is that the benefit of accelerated fractionation is specific to hyperfractionation, hazard ratio (HR) = 0.83 for overall survival. The benefit of other methods of altered fractionation is not clearly advantageous on meta-analysis.[37]**

[a] For additional resources regarding the technical details of radiation, see the American College of Radiology Guidelines: https://www.acr.org/Clinical-Resources/Practice-Parameters-and-Technical-Standards.

Note: All recommendations are category 2A unless otherwise indicated.

References

Version 1.2026, 12/08/2025 © 2025 National Comprehensive Cancer Network® (NCCN®), All rights reserved. NCCN Guidelines® and this illustration may not be reproduced in any form without the express written permission of NCCN.

PLEASE NOTE that use of this NCCN Content is governed by the End-User License Agreement, and you MAY NOT distribute this Content or use it with any artificial intelligence model or tool.
Printed by Galya Basol Kochav on 1/4/2026 9:40:35 AM. Copyright © 2026 National Comprehensive Cancer Network, Inc. All Rights Reserved.

PRINCIPLES OF RADIATION TECHNIQUES[a]

- **Palliative RT, IMRT, and Stereotactic Body RT (SBRT)**
  - **Palliative radiation should be considered in the advanced cancer setting when curative-intent treatment is not appropriate.**
  - **No general consensus exists for appropriate palliative RT regimens in head and neck cancer. For those who are either medically unsuitable for standard RT or who have widely metastatic disease, palliative RT should be considered for relief or prevention of locoregional symptoms if the RT toxicities are acceptable. RT regimens should be tailored individually; severe RT toxicities should be avoided when treatment is for palliation.**
  - **Some recommended RT regimens include:**
    - ◊ **50 Gy in 20 fractions[38];**
    - ◊ **37.5 Gy in 15 fractions (if well tolerated, consider adding 5 additional fractions to 50 Gy);**
    - ◊ **30 Gy in 10 fractions;**
    - ◊ **30 Gy in 5 fractions[b]: give 2 fractions/wk with ≥3 days between the 2 treatments; and[39]**
    - ◊ **44.4 Gy in 12 fractions, in 3 cycles (for each cycle, give 2 fractions 6 hours apart for 2 days in a row; treatments must exclude the spinal cord after second cycle).[40,41] Reassessment should be done at 1- to 3-week intervals.**
  - **The use of shorter more hypofractionated treatment courses may be indicated, but the dose tolerance of the spinal cord and neural structures must be evaluated carefully in light of fraction size.**
  - **Carefully evaluate the patient's PS, treatment tolerance, tumor response, and/or any systemic progression. Other palliative/supportive care measures include analgesics, nutrition support, targeted therapy, immunotherapy, or chemotherapy, if indicated (See NCCN Guidelines for Supportive Care).**

[a] For additional resources regarding the technical details of radiation, see the American College of Radiology Guidelines: https://www.acr.org/Clinical-Resources/Practice-Parameters-and-Technical-Standards.

[b] For end-stage disease, patients can be given more hypofractionated schedules because of the very limited prognosis.

Note: All recommendations are category 2A unless otherwise indicated.

References

Version 1.2026, 12/08/2025 © 2025 National Comprehensive Cancer Network® (NCCN®), All rights reserved. NCCN Guidelines® and this illustration may not be reproduced in any form without the express written permission of NCCN.

PLEASE NOTE that use of this NCCN Content is governed by the End-User License Agreement, and you MAY NOT distribute this Content or use it with any artificial intelligence model or tool.
Printed by Galya Basol Kochav on 1/4/2026 9:40:35 AM. Copyright © 2026 National Comprehensive Cancer Network, Inc. All Rights Reserved.

PRINCIPLES OF RADIATION TECHNIQUES[a]

- **Reirradiation with SBRT, PBT, or IMRT[42-53]**
  - **If the area in consideration overlaps with the previously radiated volume, the prior radiotherapy should have been >6 months from the appearance of new disease.**
  - **In certain rare circumstances, reirradiation with intraoperative RT (IORT) or brachytherapy may be considered in high-volume centers with expertise in these techniques.**
    - **IORT: 10–15 Gy usually followed by 40–50 Gy using EBRT[54]**
  - **Before curative intent reirradiation, the patient should have a reasonable ECOG PS of 0–1. Patients who are >2 years from prior radiation, who have surgery to remove gross disease prior to reirradiation, and who are free of organ dysfunction (eg, laryngectomy, feeding tube) have better outcomes.[55]**
  - **The incidence of myelopathy is thought to increase after a cumulative biologically effective dose (BED) of 120 Gy,[56] but this risk is increased if large fraction sizes (≥2.5 Gy/fraction) are used.**
  - **Radiation volumes should include known disease only to minimize the volume of tissue receiving very high doses in regions of overlap. Prophylactic treatment of subclinical disease (eg, elective nodal irradiation) is therefore not routinely indicated.**
  - **When using SBRT techniques for reirradiation, careful selection of patients is advised. The best outcomes are seen in patients with smaller tumors and no skin involvement. Caution should be exercised in cases of circumferential carotid artery involvement.**
  - **Reirradiation dosing:**
    - **Conventional fractionation**
      - **Postoperative: 56–60 Gy at 1.8–2 Gy/fraction**
      - **Definitive: 66–70 Gy at 1.8–2 Gy/fraction**
    - **Accelerated fractionation: 60–70 Gy at 1.2–1.5 Gy/fraction twice daily**
    - **Hyperfractionation for locally advanced nasopharyngeal carcinoma: IMRT total dose of 64.8 Gy, in 54 fractions, twice daily, with an irradiation interval of 6–8 hours[57]**
    - **Current SBRT schedules being used or investigated are in the range of 35–44 Gy using 5 fractions.[58]**
    - **Clinical trials should be strongly considered for patients receiving reirradiation.**

[a] For additional resources regarding the technical details of radiation, see the American College of Radiology Guidelines: https://www.acr.org/Clinical-Resources/Practice-Parameters-and-Technical-Standards.

Note: All recommendations are category 2A unless otherwise indicated.

References

Version 1.2026, 12/08/2025 © 2025 National Comprehensive Cancer Network® (NCCN®), All rights reserved. NCCN Guidelines® and this illustration may not be reproduced in any form without the express written permission of NCCN.

PLEASE NOTE that use of this NCCN Content is governed by the End-User License Agreement, and you MAY NOT distribute this Content or use it with any artificial intelligence model or tool.
Printed by Galya Basol Kochav on 1/4/2026 9:40:35 AM. Copyright © 2026 National Comprehensive Cancer Network, Inc. All Rights Reserved.

PRINCIPLES OF RADIATION TECHNIQUES[a,59,60]: NORMAL TISSUE DOSE CONSTRAINTS

- **Gross disease coverage should typically be prioritized over these dose constraints for normal tissues, with the exception of neurologic OARs that are usually inviolable (ie, spinal cord, brainstem, optic structures). Patients should be informed of the risks of surpassing tolerance and the rationale for optimizing disease control.**

Doses: D95 = 95% of the volume
D max = maximum dose to 0.03 cc of the volume

Structure	Dose Constraint
Bone Mandible	Max dose <70 Gy
TMJ	D0.03 cc (Gy) <70 up to 75 Gy allowed
Brachial Plexus	D0.03 cc (Gy) 66–70 Gy
Brainstem_PRV03	D0.03 cc (Gy) 54–58 Gy
Spinal Cord	Max dose 45 Gy Max dose_PRV (Cord + 5 mm) 48 Gy
Parotid	Mean dose <26 Gy
Submandibular Glands	Mean dose <39 Gy or 40 Gy
Oral Cavity excluding PTVs	Mean dose of <32 Gy
Esophagus	Mean dose <30 Gy up to 50 Gy mean dose allowed
Cochlea	Mean dose <35 Gy Max dose <55 Gy
Lips	Mean dose <20 Gy
Glottis	Mean dose <45 Gy
Larynx	Mean dose <35 Gy
Chiasm	<55 Gy D0.03 cc (Gy)
Optic Nerve	Max dose 55 Gy D0.03 cc (Gy)
Eyes	< Max dose 55 Gy D0.03 cc (Gy)

[a] For additional resources regarding the technical details of radiation, see the American College of Radiology Guidelines: https://www.acr.org/Clinical-Resources/Practice-Parameters-and-Technical-Standards.

Note: All recommendations are category 2A unless otherwise indicated.

References

Version 1.2026, 12/08/2025 © 2025 National Comprehensive Cancer Network® (NCCN®), All rights reserved. NCCN Guidelines® and this illustration may not be reproduced in any form without the express written permission of NCCN.

PLEASE NOTE that use of this NCCN Content is governed by the End-User License Agreement, and you MAY NOT distribute this Content or use it with any artificial intelligence model or tool.
Printed by Galya Basol Kochav on 1/4/2026 9:40:35 AM. Copyright © 2026 National Comprehensive Cancer Network, Inc. All Rights Reserved.

PRINCIPLES OF RADIATION TECHNIQUES
REFERENCES

[1] Dogan N, King S, Emami B, et al. Assessment of different IMRT boost delivery methods on target coverage and normal-tissue sparing. Int J Radiat Oncol Biol Phys 2003;57:1480-1491.
[2] Lee NY, de Arruda FF, Puri DR, et al. A comparison of intensity-modulated radiation therapy and concomitant boost radiotherapy in the setting of concurrent chemotherapy for locally advanced oropharyngeal carcinoma. Int J Radiat Oncol Biol Phys 2006;66:966-974.
[3] Lee NY, O'Meara W, Chan K, et al. Concurrent chemotherapy and intensity-modulated radiotherapy for locoregionally advanced laryngeal and hypopharyngeal cancers. Int J Radiat Oncol Biol Phys 2007;69:459-468.
[4] Wu Q, Mohan R, Morris M, et al. Simultaneous integrated boost intensity-modulated radiotherapy for locally advanced head-and-neck squamous cell carcinomas. I: dosimetric results. Int J Radiat Oncol Biol Phys 2003;56:573-585.
[5] Overgaard J, Hansen HS, Specht L, et al. Five compared with six fractions per week of conventional radiotherapy of squamous-cell carcinoma of head and neck: DAHANCA 6 and 7 randomised controlled trial. Lancet 2003;362:933-940.
[6] Schoenfeld GO, Amdur RJ, Morris CG, et al. Patterns of failure and toxicity after intensity-modulated radiotherapy for head and neck cancer. Int J Radiat Oncol Biol Phys 2008;71:377-385.
[7] Wolden SL, Chen WC, Pfister DG, et al. Intensity-modulated radiation therapy (IMRT) for nasopharynx cancer: update of the Memorial Sloan-Kettering experience. Int J Radiat Oncol Biol Phys 2006;64:57-62.
[8] Wu Q, Manning M, Schmidt-Ullrich R, Mohan R. The potential for sparing of parotids and escalation of biologically effective dose with intensity-modulated radiation treatments of head and neck cancers: a treatment design study. Int J Radiat Oncol Biol Phys 2000;46:195-205.
[9] Grégoire V, Ang K, Budach W, et al. Delineation of the neck node levels for head and neck tumors: a 2013 update. DAHANCA, EORTC, HKNPCSG, NCIC CTG, NCRI, RTOG, TROG consensus guidelines. Radiother Oncol 2014;110:172-181.
[10] Beadle BM, Anderson CM. CTV Guidance for Head and Neck Cancers. Int J Radiat Oncol Biol Phys 2018;100:903-905.
[11] Gregoire V, Evans M, Le QT, et al. Delineation of the primary tumour Clinical Target Volumes (CTV-P) in laryngeal, hypopharyngeal, oropharyngeal and oral cavity squamous cell carcinoma: AIRO, CACA, DAHANCA, EORTC, GEORCC, GORTEC, HKNPCSG, HNCIG, IAG-KHT, LPRHHT, NCIC CTG, NCRI, NRG Oncology, PHNS, SBRT, SOMERA, SRO, SSHNO, TROG consensus guidelines. Radiother Oncol 2018;126:3-24.
[12] Lee AW, Ng WT, Pan JJ, et al. International guideline for the delineation of the clinical target volumes (CTV) for nasopharyngeal carcinoma. Radiother Oncol 2018;126:25-36.
[13] Holliday EB, Garden A, Rosenthal D, et al. Proton therapy reduces treatment-related toxicities for patients with nasopharyngeal cancer: A case-match control study of intensity-modulated proton therapy and intensity-modulated photon therapy. Int J Part Ther 2015;2:1-10.
[14] Holliday EB and Frank SJ. Proton therapy for nasopharyngeal carcinoma. Chin Clin Oncol 2016;5:25.
[15] McDonald MW, Liu Y, Moore MG, et al. Acute toxicity in comprehensive head and neck radiation for nasopharynx and paranasal sinus cancers: cohort comparison of 3D conformal proton therapy and intensity modulated radiation therapy. Radiat Oncol 2016;11:32.
[16] Patel SH, Wang Z, Wong WW, et al. Charged particle therapy versus photon therapy for paranasal sinus and nasal cavity malignant disease: a systematic review and meta-analysis. Lancet Oncol 2014;15:1027-1038.
[17] Russo AL, Adams JA, Weyman EA, et al. Long-term outcomes after proton beam therapy for sinonasal squamous cell carcinoma. Int J Radiation Oncol Biol Phys 95:368-376.
[18] Dagan R, Bryant C, Li Z, et al. Outcomes of sinonasal cancer treated with proton therapy. Int J Radiat Oncol Biol Phys 2016;95:377-385.
[19] Bhattasali O, Holliday E, Kies MS, et al. Definitive proton radiation therapy and concurrent cisplatin for unresectable head and neck adenoid cystic carcinoma: A series of 9 cases and a critical review of the literature. Head Neck 2016;38: E1472-1480.
[20] Holliday EB, Bhattasali O, Kies MS, et al. Effective use of intensity-modulated proton therapy for robust delivery of post-operative radiation for head and neck adenoid cystic carcinoma. Int J Part Ther 2016;533-543.
[21] El-Sawy T, Frank SJ, Hanna E, et al. Multidisciplinary management of lacrimal sac/nasolacrimal duct carcinomas. Ophthal Plast Reconstr Surg 2013;29:454-457.
[22] Bui M, Frank SJ, Nasser QJ, et al. Multidisciplinary management of primary adenoid cystic carcinoma of the eyelid with perineural invasion. Ophthal Plast Reconstr Surg 2013;29:e143-146.
[23] Holliday EB, Esmaeli B, Pinkckard J, et al. A multidisciplinary orbit-sparing treatment approach that includes proton therapy for epithelial tumors of the orbit and ocular adnexa. Int J Radiation Oncol Biol Phys 2016;95:344-352.
[24] Romesser P, Cahlon O, Scher E, et al. Proton beam radiation therapy results in significantly reduced toxicity compared with intensity-modulated radiation therapy for head and neck tumors that require ipsilateral radiation. Radiother Oncol 2016;118:286-292.
[25] Romesser PB, Cahlon O, Scher ED, et al. Proton beam reirradiation for recurrent head and neck cancer: multi-institutional report on feasibility and early outcomes. Int J Radiat Oncol Biol Phys 2016;95:386-395.
[26] Phan J, Sio TT, Nguyen TP, et al. Reirradiation of head and neck cancers with proton therapy: outcomes and analyses. Int J Radiat Oncol Biol Phys 2016;96:30-41.
[27] Simone CB II, Ly D, Dan TD, et al. Comparison of intensity-modulated radiotherapy, adaptive radiotherapy, proton radiotherapy, and adaptive proton radiotherapy for treatment of locally advanced head and neck cancer. Radiother Oncol 2011;101:376-382.
[28] van de Water TA, Bijl HP, Schilstra C, et al. The potential benefit of radiotherapy with protons in head and neck cancer with respect to normal tissue sparing: a systematic review of literature. Oncologist 2011;16:366-377.

Continued

Note: All recommendations are category 2A unless otherwise indicated.

Version 1.2026, 12/08/2025 © 2025 National Comprehensive Cancer Network® (NCCN®), All rights reserved. NCCN Guidelines® and this illustration may not be reproduced in any form without the express written permission of NCCN.

PLEASE NOTE that use of this NCCN Content is governed by the End-User License Agreement, and you MAY NOT distribute this Content or use it with any artificial intelligence model or tool.
Printed by Galya Basol Kochav on 1/4/2026 9:40:35 AM. Copyright © 2026 National Comprehensive Cancer Network, Inc. All Rights Reserved.

PRINCIPLES OF RADIATION TECHNIQUES
REFERENCES

[29] van der Laan HP, van de Water TA, van Herpt HE, et al. The potential of intensity-modulated proton radiotherapy to reduce swallowing dysfunction in the treatment of head and neck cancer: A planning comparative study. Acta Oncol 2013;52:561-569.
[30] Widesott L, Pierelli A, Fioino C, et al. Intensity-modulated proton therapy versus helical tomotherapy in nasopharynx cancer: planning comparison and NTCP evaluation. Int J Radiat Oncol Biol Phys 2008;72:589-596.
[31] Kandula S, Zhu X, Garden AS, et al. Spot-scanning beam proton therapy vs intensity-modulated radiation therapy for ipsilateral head and neck malignancies: a treatment planning comparison. Med Dosim 2013;38:390-394.
[32] Jakobi A, Stutzer K, Bandurska-Lugue A, et al. NTCP reduction for advanced head and neck cancer patients using proton therapy for complete or sequential boost treatment versus photon therapy. Acta Oncol 2015;54:1658-1664.
[33] van de Water TA, Lomax AJ, Bijl HP, et al. Potential benefits of scanned intensity-modulated proton therapy versus advanced photon therapy with regard to sparing of the salivary glands in oropharyngeal cancer. Int J Radiat Oncol Biol Phys 2011; 79:1216-1224.
[34] Hartford AC, Palisca MG, Eichler TJ, et al. American Society for Therapeutic Radiology and Oncology (ASTRO) and American College of Radiology (ACR) practice guidelines for intensity-modulated radiation therapy (IMRT). Int J Radiat Oncol Biol Phys 2009;73:9-14.
[35] IMRT Documentation Working Group, Holmes T, Das R, Low D, et al. American Society of Radiation Oncology recommendations for documenting intensity-modulated radiation therapy treatments. Int J Radiat Oncol Biol Phys 2009;74:1311-1318.
[36] International Commission on Radiation Units and Measurements. ICRU Report 83: Prescribing, Recording, and Reporting Intensity-Modulated Photon-Beam Therapy (IMRT). ICRU Report 83: 2010.
[37] Lacas B, Bourhis J, Overgaard J, et al. Role of radiotherapy fractionation in head and neck cancers (MARCH): an updated meta-analysis. Lancet Oncol 2017;18:1221-1237.
[38] Stevens CM, Huang SH, Fung S, et al. Retrospective study of palliative radiotherapy in newly diagnosed head and neck carcinoma. Int J Radiat Oncol Biol Phys 2011;81:958-963.
[39] Porceddu SV, Rosser B, Burmeister BH, et al. Hypofractioned radiotherapy for the palliation of advanced head and neck cancer in patients unsuitable for curative treatment-"Hypo Trial." Radiother Oncol 2007;85:456-462.
[40] Paris KJ, Spanos WJ Jr, Lindberg RD, et al. Phase I-II study of multiple daily fractions for palliation of advanced head and neck malignancies. Int J Radiat Oncol Biol Phys 1993;25:657-660.
[41] Corry J, Peters LJ, Costa ID, et al. The 'QUAD SHOT'--a phase II study of palliative radiotherapy for incurable head and neck cancer. Radiother Oncol 2005;77:137-142.
[42] Strojan P1, Corry J, Eisbruch A, et al. Recurrent and second primary squamous cell carcinoma of the head and neck: when and how to reirradiate. Head Neck 2015;37:134-150.
[43] Mendenhall WM, Mendenhall CM, Malyapa RS, et al. Re-irradiation of head and neck carcinoma. Am J Clin Oncol 2008;31:393-398.
[44] Riaz N, Hong JC, Sherman EJ, et al. A nomogram to predict loco-regional control after re-irradiation for head and neck cancer. Radiother Oncol 2014;111:382-387.
[45] Shikama N, Kumazaki Y, Tsukamoto N, et al. Validation of nomogram-based prediction of survival probability after salvage re-irradiation of head and neck cancer. Jpn J Clin Oncol 2013;43:154-160.
[46] Nieder C, Grosu AL, Andratschke NH, et al. Update of human spinal cord reirradiation tolerance based on additional data from 38 patients. Int J Radiat Oncol Biol Phys 2006;66:1446-1449.
[47] Chen CC, Lee CC, Mah D, et al. Dose sparing of brainstem and spinal cord for re-irradiating recurrent head and neck cancer with intensity-modulated radiotherapy. Med Dosim 2011;36:21-27.
[48] Stoiber EM, Schwarz M, Debus J, et al. Regional cumulative maximum dose to the spinal cord in head-and-neck cancer: considerations for re-irradiation. Radiother Oncol 2013;106:96-100.
[49] Tanvetyanon T, Padhya T, McCaffrey J, et al. Prognostic factors for survival after salvage reirradiation of head and neck cancer. J Clin Oncol 2009;27:1983-1991.
[50] Eekers DBP, Roelofs E, Jelen U, et al. Benefit of particle therapy in re-irradiation of head and neck patients. Results of a multicentric in silico ROCOCO trial. Radiother Oncol 2016;121:387-394.
[51] Lee JY, Suresh K, Nguyen R, et al. Predictors of severe long-term toxicity after re-irradiation for head and neck cancer. Oral Oncol 2016;60:32-40.
[52] Vargo JA, Kubicek GJ, Ferris RL, et al. Adjuvant stereotactic body radiotherapy+/-cetuximab following salvage surgery in previously irradiated head and neck cancer. Laryngoscope 2014;124:1579-1584.
[53] Prawira A, Oosting S, Chen T, et al. Systemic therapies for recurrent/metastatic nasopharyngeal carcinoma (RM NPC). J Clin Oncol 2016;34(Suppl):Abstract 6031.
[54] Chen AM, Bucci MK, Singer MI, et al. Intraoperative radiation therapy for recurrent head-and-neck cancer: The UCSF experience. Int J Radiat Oncol Biol Phys 2007;67:122-129.
[55] Ward MC, Riaz N, Caudell JJ, et al. Refining patient selection for reirradiation of head and neck squamous carcinoma in the IMRT era: A multi-institution cohort study by the MIRI Collaborative. Int J Radiat Oncol 2018;100:586-594.
[56] Nieder C, Grosu AL, Andratschke NH, Molls M. Update of human spinal cord reirradiation tolerance based on additional data from 38 patients. Int J Radiat Oncol Biol Phys 2006; 66:1446-1449.
[57] You R, Liu YP, Xie YL, et al. Hyperfractionation compared with standard fractionation in intensity-modulated radiotherapy for patients with locally advanced recurrent nasopharyngeal carcinoma: a multicentre, randomised, open-label, phase 3 trial. Lancet 2023;401:917-927.
[58] Mohamad I, Karam I, El-Sehemy A, et al. The Evolving Role of Stereotactic Body Radiation Therapy for Head and Neck Cancer: Where Do We Stand? Cancers (Basel) 2023;15:5010.
[59] ICRU Report 50- Prescribing, Recording and Reporting Photon Beam Therapy Medical Physics, Vol 21, Issue 6 pages 721-834.
[60] Brodin NP, Tome WA. Revisiting the dose constraints for head and neck OARs in the current era of IMRT. Oral Oncol 2018;86:8-18.

Note: All recommendations are category 2A unless otherwise indicated.

Version 1.2026, 12/08/2025 © 2025 National Comprehensive Cancer Network® (NCCN®), All rights reserved. NCCN Guidelines® and this illustration may not be reproduced in any form without the express written permission of NCCN.

PLEASE NOTE that use of this NCCN Content is governed by the End-User License Agreement, and you MAY NOT distribute this Content or use it with any artificial intelligence model or tool.
Printed by Galya Basol Kochav on 1/4/2026 9:40:35 AM. Copyright © 2026 National Comprehensive Cancer Network, Inc. All Rights Reserved.

PRINCIPLES OF SYSTEMIC THERAPY FOR NON-NASOPHARYNGEAL CANCERS
(Oral Cavity [including mucosal lip], Oropharynx, Hypopharynx, Glottic Larynx, Supraglottic Larynx, Ethmoid Sinus, Maxillary Sinus, and Occult Primary)[a]

General Principles

- **The choice of systemic therapy should be individualized based on patient characteristics and goals of therapy. Multigene panel testing (MGPT) and other appropriate biomarker testing, including testing for at least PD-L1 expression, microsatellite instability (MSI), MMR, TMB, HER2, and *FGFR* may be considered to guide patient treatment options, including clinical trials.**
- **The preferred chemoradiotherapy approach for fit patients with locally advanced disease remains concurrent cisplatin and radiotherapy.**
- **Cisplatin-based induction chemotherapy can be used, followed by radiation-based locoregional treatment (ie, sequential chemoRT). However, an improvement in overall survival with the incorporation of induction chemotherapy compared to proceeding directly to state-of-the-art concurrent chemoRT (cisplatin preferred, category 1) has not been established in randomized studies.**
- **Cisplatin-based induction chemotherapy followed by high-dose, every-3-week cisplatin chemoradiotherapy is associated with toxicity concerns.[1,2]**
- **After induction chemotherapy, multiple options can be used for the radiation-based portion of therapy, including radiotherapy alone, particularly for patients with CR after induction chemotherapy.**
- **Imaging every 2–3 cycles of treatment in the recurrent/metastatic setting.**
- **Nivolumab and hyaluronidase-nvhy subcutaneous injection may be substituted for IV nivolumab. Nivolumab and hyaluronidase-nvhy has different dosing and administration instructions compared to IV nivolumab. Nivolumab and hyaluronidase-nvhy is not approved for concurrent use with IV ipilimumab.**
- **Pembrolizumab and berahyaluronidase alfa-pmph subcutaneous injection may be substituted for IV pembrolizumab. Pembrolizumab and berahyaluronidase alfa-pmph has different dosing and administration instructions compared to IV pembrolizumab.**

[a] For more information regarding *DPYD* testing, see the NCCN Guidelines for Colon Cancer.

Note: All recommendations are category 2A unless otherwise indicated.

Additional Systemic Therapy Regimens
References

Version 1.2026, 12/08/2025 © 2025 National Comprehensive Cancer Network® (NCCN®), All rights reserved. NCCN Guidelines® and this illustration may not be reproduced in any form without the express written permission of NCCN.

PLEASE NOTE that use of this NCCN Content is governed by the End-User License Agreement, and you MAY NOT distribute this Content or use it with any artificial intelligence model or tool.
Printed by Galya Basol Kochav on 1/4/2026 9:40:35 AM. Copyright © 2026 National Comprehensive Cancer Network, Inc. All Rights Reserved.

PRINCIPLES OF SYSTEMIC THERAPY FOR NON-NASOPHARYNGEAL CANCERS (Oral Cavity [including mucosal lip], Oropharynx, Hypopharynx, Glottic Larynx, Supraglottic Larynx, Ethmoid Sinus, Maxillary Sinus, and Occult Primary)[a]

Primary Systemic Therapy + Concurrent RT

Preferred
- High-dose Cisplatin (category 1)[3,4]
- Carboplatin/infusional Fluorouracil (category 1)[5,6]

Other Recommended
- Weekly Cisplatin (40 mg/m^2)[7,8,9,10,11]
- Carboplatin/Paclitaxel (category 2B)[12,13]

Useful in Certain Circumstances
- Docetaxel (if Cisplatin ineligible)[14]
- Cetuximab (category 2B)[15]
- Cisplatin/infusional Fluorouracil (category 2B)[16]
- Cisplatin/Paclitaxel (category 2B)[17]
- Infusional Fluorouracil/Hydroxyurea (category 2B)[17]

Select ethmoid/maxillary sinus cancers (ie, small cell, SNEC, high-grade olfactory esthesioneuroblastoma, SNUC with neuroendocrine features):
- Carboplatin/Etoposide ± concurrent RT[18]
- Cisplatin/Etoposide ± concurrent RT[18,19]

Induction[b]/Sequential Systemic Therapy and Neoadjuvant immunotherapy

Preferred
- Cisplatin/Docetaxel/Infusional Fluorouracil[20-23] (category 1 if induction is chosen)

Other Recommended
- Cisplatin/infusional Fluorouracil/Paclitaxel[24]
- Stage III–IVA cancer of the oral cavity (with PD-L1 positive [CPS ≥1]):
  - Neoadjuvant Pembrolizumab followed by adjuvant Pembrolizumab/RT (with Cisplatin if extranodal extension and/or positive margin) followed by adjuvant Pembrolizumab[25,26]

Useful in Certain Circumstances
- Stage III-IVA cancer of p16-negative oropharynx, hypopharynx, and larynx (with PD-L1 positive (CPS ≥1)):
  - Neoadjuvant Pembrolizumab followed by adjuvant Pembrolizumab/RT (with Cisplatin if extranodal extension and/or positive margin) followed by adjuvant Pembrolizumab[25,26]
- Carboplatin/Paclitaxel (category 2B)[27,28]
- Carboplatin/Paclitaxel + Cetuximab[29] (induction only) (category 2B)

For Newly Diagnosed T3, T4a Ethmoid Sinus Tumor

Other Recommended
- Cisplatin/Docetaxel/Infusional Fluorouracil

Useful in Certain Circumstances
- Cisplatin/Etoposide

Select ethmoid/maxillary sinus cancers (ie, small cell, SNEC, high-grade olfactory esthesioneuroblastoma, SNUC with neuroendocrine features):
- Cyclophosphamide/Doxorubicin/Vincristine[30] (followed by RT-based treatment)

[a] For more information regarding *DPYD* testing, see the NCCN Guidelines for Colon Cancer.
[b] The Categories of Evidence and Consensus for induction therapy vary depending on site. See disease-specific site in the Head and Neck Table of Contents.

Note: All recommendations are category 2A unless otherwise indicated.

Version 1.2026, 12/08/2025 © 2025 National Comprehensive Cancer Network® (NCCN®), All rights reserved. NCCN Guidelines® and this illustration may not be reproduced in any form without the express written permission of NCCN.

PLEASE NOTE that use of this NCCN Content is governed by the End-User License Agreement, and you MAY NOT distribute this Content or use it with any artificial intelligence model or tool.
Printed by Galya Basol Kochav on 1/4/2026 9:40:35 AM. Copyright © 2026 National Comprehensive Cancer Network, Inc. All Rights Reserved.

PRINCIPLES OF SYSTEMIC THERAPY FOR NON-NASOPHARYNGEAL CANCERS (Oral Cavity [including mucosal lip], Oropharynx, Hypopharynx, Glottic Larynx, Supraglottic Larynx, Ethmoid Sinus, Maxillary Sinus, and Occult Primary)[a]

Systemic Therapy/RT Following Induction Therapy, or Combination Chemotherapy for Recurrent/Persistent Disease[2,31,32]
Preferred • Weekly Carboplatin + Concurrent RT • Weekly Cisplatin (category 2B) + concurrent RT **Useful in Certain Circumstances** • Weekly Cetuximab + concurrent RT

Reirradiation + Concurrent Systemic Therapy
Preferred • Cisplatin + concurrent RT[7,33] **Useful in Certain Circumstances** • Carboplatin + concurrent RT (category 2B)[31,34] • Cetuximab + concurrent RT (category 2B)[15] • Docetaxel + concurrent RT (category 2B)[14]

Postoperative Systemic Therapy/RT
Preferred • Cisplatin (category 1 for high-risk[c] non-oropharyngeal cancers)[33-40] **Other Recommended** • None **Useful in Certain Circumstances** • Docetaxel (if Cisplatin ineligible)[14] • Docetaxel + Cetuximab (category 2B)[41] (if Cisplatin ineligible and extranodal extension and/or positive margins)

[a] For more information regarding *DPYD* testing, see the NCCN Guidelines for Colon Cancer.
[c] Adverse pathologic features: extranodal extension and/or positive margins or close margins.

Note: All recommendations are category 2A unless otherwise indicated.

Version 1.2026, 12/08/2025 © 2025 National Comprehensive Cancer Network® (NCCN®), All rights reserved. NCCN Guidelines® and this illustration may not be reproduced in any form without the express written permission of NCCN.

PLEASE NOTE that use of this NCCN Content is governed by the End-User License Agreement, and you MAY NOT distribute this Content or use it with any artificial intelligence model or tool.
Printed by Galya Basol Kochav on 1/4/2026 9:40:35 AM. Copyright © 2026 National Comprehensive Cancer Network, Inc. All Rights Reserved.

PRINCIPLES OF SYSTEMIC THERAPY FOR NON-NASOPHARYNGEAL CANCERS (Oral Cavity [including mucosal lip], Oropharynx, Hypopharynx, Glottic Larynx, Supraglottic Larynx, Ethmoid Sinus, Maxillary Sinus, and Occult Primary)[a]

Recurrent, Unresectable, or Metastatic Disease (with no surgery or RT option)		
Preferred	**Other Recommended (First- and Subsequent-Line)**	**Useful in Certain Circumstances (First- and Subsequent-Line)**
First-Line[d] • Carboplatin/Infusional Fluorouracil + Pembrolizumab (category 1)[42] • Cisplatin/Infusional Fluorouracil + Pembrolizumab (category 1)[42] • Pembrolizumab (for tumors that express PD-L1 with CPS ≥1)[42] (category 1) **Subsequent-Line (if not previously used)** • Nivolumab[43] (if disease progression on or after platinum therapy) (category 1) • Pembrolizumab[44-46] (if disease progression on or after platinum therapy) (category 1)	**Combination Regimens** • Carboplatin/Infusional Fluorouracil + Cetuximab[47] (category 1) • Cisplatin/Infusional Fluorouracil + Cetuximab[47] (category 1) • Cisplatin + Cetuximab[48] • Cisplatin or Carboplatin/Docetaxel[49] or Paclitaxel[50] • Cisplatin/Infusional Fluorouracil[50,51] • Cisplatin or Carboplatin/Docetaxel + Cetuximab[52] • Cisplatin or Carboplatin/Paclitaxel + Cetuximab[53] • Carboplatin/Docetaxel + Pembrolizumab[42,49] • Carboplatin/Paclitaxel + Pembrolizumab[42,50,54] • Cisplatin/Docetaxel + Pembrolizumab[42,49] • Cisplatin/Paclitaxel + Pembrolizumab[42,50,54] **Single Agents** • Capecitabine[55] • Carboplatin[56] • Cetuximab[57,58] • Cisplatin[48,59] • Docetaxel[60,61] • Infusional Fluorouracil[59] • Methotrexate[51,62] • Paclitaxel[63] • Afatinib[64] (subsequent-line only, if disease progression on or after platinum therapy) (category 2B)	• Squamous cell carcinoma ▸ Cetuximab + Nivolumab[65] ▸ Cetuximab + Pembrolizumab[66] • Paclitaxel + Cetuximab[67] • Pembrolizumab (for MSI-H, dMMR, or TMB-H [≥10 mut/Mb] tumors)[68] • Cisplatin/Pemetrexed (for PS 0–1) (category 2B)[69] • Docetaxel + Cetuximab (category 2B)[52] • Gemcitabine/Paclitaxel (category 2B)[70] • Ipilimumab + Nivolumab (PD-L1 positive [CPS ≥20] and first-line only) (category 2B)[71] • Enfortumab vedotin-ejfv (if disease progression on or after platinum therapy and a PD-1/PD-L1 inhibitor) (category 2B)[72] • Erdafitinib for *FGFR* mutations or gene fusion positive tumors and disease progression with at least one line of prior systemic therapy and no availability of an alternative systemic therapy (category 2B)[73] • Fam-trastuzumab deruxtecan-nxki (for HER2+ (IHC 3+) solid tumors; subsequent line only with no satisfactory alternative treatment options) (category 2B)[74] • For select ethmoid/maxillary sinus cancers (ie, small cell, SNEC, high-grade olfactory esthesioneuroblastoma, SNUC with neuroendocrine features): ▸ Cisplatin/Etoposide or Carboplatin/Etoposide[19] ▸ Cyclophosphamide/Doxorubicin/Vincristine (category 2B)[30]

[a] For more information regarding *DPYD* testing, see the NCCN Guidelines for Colon Cancer.

[d] If not previously used, these regimens may be considered in subsequent-line therapy as other recommended regimens.

Note: All recommendations are category 2A unless otherwise indicated.

References

Version 1.2026, 12/08/2025 © 2025 National Comprehensive Cancer Network® (NCCN®), All rights reserved. NCCN Guidelines® and this illustration may not be reproduced in any form without the express written permission of NCCN.

PLEASE NOTE that use of this NCCN Content is governed by the End-User License Agreement, and you MAY NOT distribute this Content or use it with any artificial intelligence model or tool.
Printed by Galya Basol Kochav on 1/4/2026 9:40:35 AM. Copyright © 2026 National Comprehensive Cancer Network, Inc. All Rights Reserved.

PRINCIPLES OF SYSTEMIC THERAPY
REFERENCES

[1] Adelstein DJ, Moon J, Hanna E, et al. Docetaxel, cisplatin, and fluorouracil induction chemotherapy followed by accelerated fractionation/concomitant boost radiation and concurrent cisplatin in patients with advanced squamous cell head and neck cancer: a Southwest Oncology Group phase II trial (S0216). Head Neck 2010;32:221-228.
[2] Lefebvre JL, Pointreau Y, Rolland F, et al. Induction chemotherapy followed by either chemoradiotherapy or bioradiotherapy for larynx preservation: the TREMPLIN randomized phase II study. J Clin Oncol 2013;31:853-859.
[3] Adelstein DJ, Li Y, Adams GL, et al. An intergroup phase III comparison of standard radiation therapy and two schedules of concurrent chemoradiotherapy in patients with unresectable squamous cell head and neck cancer. J Clin Oncol 2003;21:92-98.
[4] Forastiere AA, Zhang Q, Weber RS, et al. Long-term results of RTOG 91-11: a comparison of three nonsurgical treatment strategies to preserve the larynx in patients with locally advanced larynx cancer. J Clin Oncol 2013;31:845-852.
[5] Bourhis J, Sire C, Graff P, et al. Concomitant chemoradiotherapy versus acceleration of radiotherapy with or without concomitant chemotherapy in locally advanced head and neck carcinoma (GORTEC 99-02): an open-label phase 3 randomised trial. Lancet Oncol 2012;13:145-153.
[6] Denis F, Garaud P, Bardet E, et al. Final results of the 94-01 French Head and Neck Oncology and Radiotherapy Group randomized trial comparing radiotherapy alone with concomitant radiochemotherapy in advanced-stage oropharynx carcinoma. J Clin Oncol 2004;22:69-76.
[7] Beckmann GK, Hoppe F, Pfreundner L, Flentje MP. Hyperfractionated accelerated radiotherapy in combination with weekly cisplatin for locally advanced head and neck cancer. Head Neck 2005;27:36-43.
[8] Medina JA, Rueda A, de Pasos AS, et al. A phase II study of concomitant boost radiation plus concurrent weekly cisplatin for locally advanced unresectable head and neck carcinomas. Radiother Oncol 2006;79:34-38.
[9] Gebre-Medhin M, Brun E, Engstrom P, et al. ARTSCAN III: A randomized phase III study comparing chemoradiotherapy with cisplatin versus cetuximab in patients with locoregionally advanced head and neck squamous cell cancer. J Clin Oncol 2021;39:38-47.
[10] Rischin D, King M, Kenny L, et al. Randomized trial of radiation therapy with weekly cisplatin or cetuximab in low-risk HPV-associated oropharyngeal cancer (TROG 12.01) - A Trans-Tasman Radiation Oncology Group study. Int J Radiat Oncol Biol Phys 2021;111:876-886.
[11] Sharma A, Kumar M, Bhasker S, et al. An open-label, noninferiority phase III RCT of weekly versus three weekly cisplatin and radical radiotherapy in locally advanced head and neck squamous cell carcinoma (ConCERT trial) [Abstract]. J Clin Oncol 2022;40(16 suppl):Abstract 6004.
[12] Ma SJ, Zhu S, Bhateja P, et al. Association of weekly cisplatin vs. carboplatin and paclitaxel with outcomes among patients with head and neck cancer treated with definitive chemoradiation. Int J Radiat Oncol Biol Phys 2024;120:E768.
[13] Suntharalingam M, Haas ML, Conley BA, et al. The use of carboplatin and paclitaxel with daily radiotherapy in patients with locally advanced squamous cell carcinomas of the head and neck. Int J Radiat Oncol Biol Phys 2000;47:49-56.
[14] Patil VM, Noronha V, Menon N, et al. Results of phase III randomized trial for use of docetaxel as a radiosensitizer in patients with head and neck cancer, unsuitable for cisplatin-based chemoradiation. J Clin Oncol 2023;41:2350-2361.
[15] Garden AS, Harris J, Vokes EE, et al. Preliminary results of Radiation Therapy Oncology Group 97-03: a randomized phase II trial of concurrent radiation and chemotherapy for advanced squamous cell carcinomas of the head and neck. J Clin Oncol 2004;22:2856-2864.
[16] Bonner JA, Harari PM, Giralt J, et al. Radiotherapy plus cetuximab for locoregionally advanced head and neck cancer: 5-year survival data from a phase 3 randomised trial, and relation between cetuximab-induced rash and survival. Lancet Oncol 2010;11:21-28.
[17] Taylor SG, Murthy AK, Vannetzel JM, et al. Randomized comparison of neoadjuvant cisplatin and fluorouracil infusion followed by radiation versus concomitant treatment in advanced head and neck cancer. J Clin Oncol 1994;12:385-395.
[18] Patil VM, Joshi A, Noronha V, et al. Neoadjuvant chemotherapy in locally advanced and borderline resectable nonsquamous sinonasal tumors (esthesioneuroblastoma and sinonasal tumor with neuroendocrine differentiation). Int J Surg Oncol 2016;2016:6923730.
[19] Resto VA, Eisele DW, Forastiere A, et al. Esthesioneuroblastoma: the Johns Hopkins experience. Head Neck 2000;22:550-558.
[20] Janoray G, Pointreau Y, Garaud P, et al. Long-term results of a multicenter randomized phase III trial of induction chemotherapy with cisplatin, 5-fluorouracil, +/- docetaxel for larynx preservation. J Natl Cancer Inst 2016;108.
[21] Pointreau Y, Garaud P, Chapet S, et al. Randomized trial of induction chemotherapy with cisplatin and 5-fluorouracil with or without docetaxel for larynx preservation. J Natl Cancer Inst 2009;101:498-506.
[22] Posner MR, Hershock DM, Blajman CR, et al. Cisplatin and fluorouracil alone or with docetaxel in head and neck cancer. N Engl J Med 2007;357:1705-1715.
[23] Vermorken JB, Remenar E, van Herpen C, et al. Cisplatin, fluorouracil, and docetaxel in unresectable head and neck cancer. N Engl J Med 2007;357:1695-1704.
[24] Hitt R, Lopez-Pousa A, Martinez-Trufero J, et al. Phase III study comparing cisplatin plus fluorouracil to paclitaxel, cisplatin, and fluorouracil induction chemotherapy followed by chemoradiotherapy in locally advanced head and neck cancer. J Clin Oncol 2005;23:8636-8645.
[25] Uppaluri R, Campbell KM, Egloff AM, et al. Neoadjuvant and Adjuvant Pembrolizumab in Resectable Locally Advanced, Human Papillomavirus-Unrelated Head and Neck Cancer: A Multicenter, Phase II Trial. Clin Cancer Res 2020;26:5140-5152.

Note: All recommendations are category 2A unless otherwise indicated.

Version 1.2026, 12/08/2025 © 2025 National Comprehensive Cancer Network® (NCCN®), All rights reserved. NCCN Guidelines® and this illustration may not be reproduced in any form without the express written permission of NCCN.

PLEASE NOTE that use of this NCCN Content is governed by the End-User License Agreement, and you MAY NOT distribute this Content or use it with any artificial intelligence model or tool.
Printed by Galya Basol Kochav on 1/4/2026 9:40:35 AM. Copyright © 2026 National Comprehensive Cancer Network, Inc. All Rights Reserved.

PRINCIPLES OF SYSTEMIC THERAPY
REFERENCES

[26] Uppaluri R, Haddad RI, Tao Y, et al; KEYNOTE-689 Investigators. Neoadjuvant and Adjuvant Pembrolizumab in Locally Advanced Head and Neck Cancer. N Engl J Med 2025;393:37-50.
[27] Ready NE, Rathore R, Johnson TT, et al. Weekly paclitaxel and carboplatin induction chemotherapy followed by concurrent chemoradiotherapy in locally advanced squamous cell carcinoma of the head and neck. Am J Clin Oncol 2012;35:6-12.
[28] Vokes EE, Stenson K, Rosen FR, et al. Weekly carboplatin and paclitaxel followed by concomitant paclitaxel, fluorouracil, and hydroxyurea chemoradiotherapy: curative and organ-preserving therapy for advanced head and neck cancer. J Clin Oncol 2003;21:320-326.
[29] Kies MS, Holsinger FC, Lee JJ, et al. Induction chemotherapy and cetuximab for locally advanced squamous cell carcinoma of the head and neck: results from a phase II prospective trial. J Clin Oncol 2010;28:8-14.
[30] Rastogi M, Bhatt M, Chufal K, et al. Esthesioneuroblastoma treated with non-craniofacial resection surgery followed by combined chemotherapy and radiotherapy: An alternative approach in limited resources. Jpn J Clin Oncol 2006;36:613-619.
[31] Chitapanarux I, Lorvidhaya V, Kamnerdsupaphon P, et al. Systemic therapy/RT comparing cisplatin versus carboplatin in locally advanced nasopharyngeal cancer: randomised, non-inferiority, open trial. Eur J Cancer 2007;43:1399-1406.
[32] Haddad R, O'Neill A, Rabinowits G, et al. Induction chemotherapy followed by concurrent chemoradiotherapy (sequential chemoradiotherapy) versus concurrent chemoradiotherapy alone in locally advanced head and neck cancer (PARADIGM): a randomised phase 3 trial. Lancet Oncol 2013;14:257-264.
[33] Noronha V, Joshi A, Patil VM, et al. Once-a-week versus once-every-3-weeks cisplatin systemic therapy/RT for locally advanced head and neck cancer: a phase III randomized noninferiority trial. J Clin Oncol 2018:36:1064-1072.
[34] Dechaphunkul T, Pruegsanusak K, Sangthawan D, Sunpaweravong P. Concurrent chemoradiotherapy with carboplatin followed by carboplatin and 5-fluorouracil in locally advanced nasopharyngeal carcinoma. Head Neck Oncol 2011;3:30.
[35] Bachaud JM, Cohen-Jonathan E, Alzieu C, et al. Combined postoperative radiotherapy and weekly cisplatin infusion for locally advanced head and neck carcinoma: final report of a randomized trial. Int J Radiat Oncol Biol Phys 1996;36:999-1004.
[36] Bernier J, Cooper JS, Pajak TF, et al. Defining risk levels in locally advanced head and neck cancers: a comparative analysis of concurrent postoperative radiation plus chemotherapy trials of the EORTC (#22931) and RTOG (# 9501). Head Neck 2005;27:843-850.
[37] Bernier J, Domenge C, Ozsahin M, et al. Postoperative irradiation with or without concomitant chemotherapy for locally advanced head and neck cancer. N Engl J Med 2004;350:1945-1952.
[38] Cooper JS, Pajak TF, Forastiere AA, et al. Postoperative concurrent radiotherapy and chemotherapy for high-risk squamous-cell carcinoma of the head and neck. N Engl J Med 2004;350:1937-1944.
[39] Cooper JS, Zhang Q, Pajak TF, et al. Long-term follow-up of the RTOG 9501/intergroup phase III trial: postoperative concurrent radiation therapy and chemotherapy in high-risk squamous cell carcinoma of the head and neck. Int J Radiat Oncol Biol Phys 2012;84:1198-1205.
[40] Kiyota N, Tahara M, Mizusawa J, et al. Weekly cisplatin plus radiation for postoperative head and neck cancer (JCOG1008): A multicenter, noninferiority, phase II/III randomized controlled trial. J Clin Oncol 2022;40:1980-1990.
[41] Harari PM, Harris J, Kies MS, et al. Postoperative chemoradiotherapy and cetuximab for high-risk squamous cell carcinoma of the head and neck: Radiation Therapy Oncology Group RTOG-0234. J Clin Oncol 2014;32:2486-2495.
[42] Burtness B, Harrington KJ, Greil R, et al. Pembrolizumab alone or with chemotherapy versus cetuximab with chemotherapy for recurrent or metastatic squamous cell carcinoma of the head and neck (KEYNOTE-048): a randomised, open-label, phase 3 study. Lancet 2019;394:1915-1928.
[43] Ferris RL, Blumenschein G Jr, Fayette J, et al. Nivolumab for recurrent squamous-cell carcinoma of the head and neck. N Engl J Med 2016;375:1856-1867.
[44] Chow LQ, Haddad R, Gupta S, et al. Antitumor activity of pembrolizumab in biomarker-unselected patients with recurrent and/or metastatic head and neck squamous cell carcinoma: results from the phase Ib KEYNOTE-012 expansion cohort. J Clin Oncol 2016;34:3838-3845.
[45] Cohen EEW, Soulieres D, Le Tourneau C, et al. Pembrolizumab versus methotrexate, docetaxel, or cetuximab for recurrent or metastatic head-and-neck squamous cell carcinoma (KEYNOTE-040): a randomised, open-label, phase 3 study. Lancet 2019;393:156-167.
[46] Seiwert TY, Burtness B, Mehra R, et al. Safety and clinical activity of pembrolizumab for treatment of recurrent or metastatic squamous cell carcinoma of the head and neck (KEYNOTE-012): an open-label, multicentre, phase 1b trial. Lancet Oncol 2016;17:956-965.
[47] Vermorken JB, Mesia R, Rivera F, et al. Platinum-based chemotherapy plus cetuximab in head and neck cancer. N Engl J Med 2008;359:1116-1127.
[48] Burtness B, Goldwasser MA, Flood W, et al. Phase III randomized trial of cisplatin plus placebo compared with cisplatin plus cetuximab in metastatic/recurrent head and neck cancer: an Eastern Cooperative Oncology Group study. J Clin Oncol 2005;23:8646-8654.
[49] Samlowski WE, Moon J, Kuebler JP, et al. Evaluation of the combination of docetaxel/carboplatin in patients with metastatic or recurrent squamous cell carcinoma of the head and neck (SCCHN): a Southwest Oncology Group Phase II study. Cancer Invest 2007;25:182-188.

Note: All recommendations are category 2A unless otherwise indicated.

Version 1.2026, 12/08/2025 © 2025 National Comprehensive Cancer Network® (NCCN®), All rights reserved. NCCN Guidelines® and this illustration may not be reproduced in any form without the express written permission of NCCN.

PLEASE NOTE that use of this NCCN Content is governed by the End-User License Agreement, and you MAY NOT distribute this Content or use it with any artificial intelligence model or tool.
Printed by Galya Basol Kochav on 1/4/2026 9:40:35 AM. Copyright © 2026 National Comprehensive Cancer Network, Inc. All Rights Reserved.

PRINCIPLES OF SYSTEMIC THERAPY
REFERENCES

[50] Gibson MK, Li Y, Murphy B, et al. Randomized phase III evaluation of cisplatin plus fluorouracil versus cisplatin plus paclitaxel in advanced head and neck cancer (E1395): an intergroup trial of the Eastern Cooperative Oncology Group. J Clin Oncol 2005;23:3562-3567.
[51] Forastiere AA, Metch B, Schuller DE, et al. Randomized comparison of cisplatin plus fluorouracil and carboplatin plus fluorouracil versus methotrexate in advanced squamous-cell carcinoma of the head and neck: a Southwest Oncology Group study. J Clin Oncol 1992;10:1245-1251.
[52] Guigay J, Fayette J, Dillies A-F, et al. Cetuximab, docetaxel, and cisplatin (TPEx) as first-line treatment in patients with recurrent or metastatic (R/M) squamous cell carcinoma of the head and neck (SCCHN): Final results of phase II trial GORTEC 2008-03 [abstract]. J Clin Oncol 2012;30(Suppl):Abstract 5505.
[53] Herbst RS, Arquette M, Shin DM, et al. Phase II multicenter study of the epidermal growth factor receptor antibody cetuximab and cisplatin for recurrent and refractory squamous cell carcinoma of the head and neck. J Clin Oncol 2005;23:5578-5587.
[54] Dzienis M, Cundom J, Fuentes CS, et al. Pembrolizumab + carboplatin + paclitaxel as first-line therapy in recurrent/metastatic head and neck squamous cell carcinoma: Phase 4 KEYNOTE-B10 study. presented at European Society for Medical Oncology (ESMO) Congress; September 9-13, 2022; Paris, France.
[55] Martinez-Trufero J, Isla D, Adansa JC, et al. Phase II study of capecitabine as palliative treatment for patients with recurrent and metastatic squamous head and neck cancer after previous platinum-based treatment. Br J Cancer 2010;102:1687-1691.
[56] Al-Sarraf M, Metch B, Kish J, et al. Platinum analogs in recurrent and advanced head and neck cancer: a Southwest Oncology Group and Wayne State University Study. Cancer Treat Rep 1987;71:723-726.
[57] Vermorken JB, Trigo J, Hitt R, et al. Open-label, uncontrolled, multicenter phase II study to evaluate the efficacy and toxicity of cetuximab as a single agent in patients with recurrent and/or metastatic squamous cell carcinoma of the head and neck who failed to respond to platinum-based therapy. J Clin Oncol 2007;25:2171-2177.
[58] Fury MG, Sherman E, Lisa D, et al. A randomized phase II study of cetuximab every 2 weeks at either 500 or 750 mg/m2 for patients with recurrent or metastatic head and neck squamous cell cancer. J Natl Compr Canc Netw 2012;10:1391-1398.
[59] Jacobs C, Lyman G, Velez-Garcia E, et al. A phase III randomized study comparing cisplatin and fluorouracil as single agents and in combination for advanced squamous cell carcinoma of the head and neck. J Clin Oncol 1992;10:257-263.
[60] Catimel G, Verweij J, Mattijssen V, et al. Docetaxel (Taxotere): an active drug for the treatment of patients with advanced squamous cell carcinoma of the head and neck. EORTC Early Clinical Trials Group. Ann Oncol 1994;5:533-537.
[61] Guardiola E, Peyrade F, Chaigneau L, et al. Results of a randomised phase II study comparing docetaxel with methotrexate in patients with recurrent head and neck cancer. Eur J Cancer 2004;40:2071-2076.
[62] Stewart JS, Cohen EE, Licitra L, et al. Phase III study of gefitinib compared with intravenous methotrexate for recurrent squamous cell carcinoma of the head and neck [corrected]. J Clin Oncol 2009;27:1864-1871.
[63] Grau JJ, Caballero M, Verger E, et al. Weekly paclitaxel for platin-resistant stage IV head and neck cancer patients. Acta Otolaryngol 2009;129:1294-1299.
[64] Machiels JP, Haddad RI, Fayette J, et al. Afatinib versus methotrexate as second-line treatment in patients with recurrent or metastatic squamous-cell carcinoma of the head and neck progressing on or after platinum-based therapy (LUX-Head & Neck 1): an open-label, randomised phase 3 trial. Lancet Oncol 2015;16:583-594.
[65] Chung CH, Li J, Steuer CE, et al. Phase II multi-institutional clinical trial result of concurrent cetuximab and nivolumab in recurrent and/or metastatic head and neck squamous cell carcinoma. Clin Cancer Res 2022;28:2329-2338.
[66] Sacco AG, Chen R, Worden FP, et al Pembrolizumab plus cetuximab in patients with recurrent or metastatic head and neck squamous cell carcinoma: an open-label, multi-arm, non-randomised, multicentre, phase 2 trial. Lancet Oncol 2021;22:883-892.
[67] Bossi P, Miceli R, Locati LD, et al. A randomized, phase 2 study of cetuximab plus cisplatin with or without paclitaxel for the first-line treatment of patients with recurrent and/or metastatic squamous cell carcinoma of the head and neck Ann Oncol 2017;28:2820-2826.
[68] Marabelle A, Le DT, Ascierto PA, et al. Efficacy of pembrolizumab in patients with noncolorectal high microsatellite instability/mismatch repair-deficient cancer: results from the phase II KEYNOTE-158 study. J Clin Oncol 2020;38:1-10.
[69] Urba S, van Herpen CML, Sahoo TP, et al. Pemetrexed in combination with cisplatin versus cisplatin monotherapy in patients with recurrent or metastatic head and neck cancer: final results of a randomized, double-blind, placebo-controlled, phase 3 study. Cancer 2012;118:4694-4705.
[70] Malhotra B, Moon J, Kucuk O, et al. Phase II trial of biweekly gemcitabine and paclitaxel with recurrent or metastatic squamous cell carcinoma of the head and neck: Southwest Oncology Group study S0329. Head Neck 2014;36:1712-1717.
[71] Haddad RI, Harrington K, Tahara M, et al. Nivolumab plus ipilimumab versus EXTREME regimen as first-line treatment for recurrent/metastatic squamous cell carcinoma of the head and neck: Final results of CheckMate 651. J Clin Oncol 2023;41:2166-2180.
[72] Swiecicki PL, Yilmaz E, Rosenberg AJ, et al. Phase II Trial of Enfortumab Vedotin in Patients With Previously Treated Advanced Head and Neck Cancer. J Clin Oncol 2025;43:578-588.
[73] Pant S, Schuler M, Iyer G, et al. Erdafitinib in patients with advanced solid tumours with FGFR alterations (RAGNAR): an international, single-arm, phase 2 study. Lancet Oncol 2023;24:925-935.
[74] Meric-Bernstam F, Makker V, Oaknin A, et al. Efficacy and safety of trastuzumab deruxtecan in patients with her2-expressing solid tumors: Primary results from the destiny-pantumor02 phase ii trial. J Clin Oncol 2024;42:47-58.

Note: All recommendations are category 2A unless otherwise indicated.

Version 1.2026, 12/08/2025 © 2025 National Comprehensive Cancer Network® (NCCN®), All rights reserved. NCCN Guidelines® and this illustration may not be reproduced in any form without the express written permission of NCCN.

PLEASE NOTE that use of this NCCN Content is governed by the End-User License Agreement, and you MAY NOT distribute this Content or use it with any artificial intelligence model or tool.
Printed by Galya Basol Kochav on 1/4/2026 9:40:35 AM. Copyright © 2026 National Comprehensive Cancer Network, Inc. All Rights Reserved.

PRINCIPLES OF NUTRITION: MANAGEMENT AND SUPPORTIVE CARE[1-3]

Most patients with head and neck cancer lose weight and are nutritionally compromised as a result of their disease, health behaviors, and treatment-related toxicities. Nutritional management is very important in patients with head and neck cancer to improve outcomes and to minimize significant temporary or permanent treatment-related complications (eg, severe weight loss). A registered dietitian and a speech language/swallowing therapist should be part of the multidisciplinary team for treating patients with head and neck cancer throughout the continuum of care.

Assessment and Management

- **Nutrition**
  - **Close monitoring of nutritional status is recommended in patients who have: 1) significant weight loss (5% weight loss over prior 1 month, or 10% weight loss over 6 months); and/or 2) difficulty swallowing because of pain or tumor involvement prior to treatment. All patients should be evaluated for nutritional risks and should receive nutrition counseling by a registered dietitian and/or indicated treatment with various nutrition interventions, such as feeding tubes (eg, nasogastric [NG] tubes, nasojejunal [NJ] tubes, percutaneous endoscopic gastrostomy [PEG] tubes, percutaneous endoscopic jejunostomy [PEJ] tubes) or intravenous nutrition support (but only if enteral support is not feasible).**
  - **Pre- and post-treatment functional evaluation including nutritional status should be undertaken using subjective and objective assessment tools. All patients should receive dietary counseling with the initiation of treatment, especially with RT-based treatments. Regular follow-up with the registered dietitian should continue at least until the patient has achieved a nutritionally stable baseline following treatment. For some patients with chronic nutritional challenges, this follow-up should be ongoing.**
- **Speech and Swallowing**
  - **A formal speech and swallowing evaluation at baseline is recommended for either:**
    1) patients with speech and/or swallowing dysfunction; or
    2) patients whose treatment is likely to affect speech and/or swallowing.
  - **Baseline functional evaluation including oral health, dental health, and nutritional status should be undertaken using both subjective and objective assessment tools. All patients should receive dietary counseling with initiation of treatment, especially with RT-based treatments.**
  - **Interval reassessments during and after treatments into survivorship are important in order to palliate treatment-related side effects such as loss of appetite, mucositis, oral pain, xerostomia, loss of taste/smell, lymphedema, trismus, etc that impact patient's nutritional status and well-being.**
  - **Patients with ongoing abnormal function should be seen regularly by speech-language pathologists. Dysphagia and swallowing function can be measured by clinical swallowing assessments, fiberoptic endoscopic swallowing evaluations, or videofluoroscopic swallowing studies. Patient evaluations should also include assessment for any changes in speech and communication; changes in taste; and assessment for xerostomia, pain, trismus, lymphedema, and fibrosis (see SLYMPH-A in the NCCN Guidelines for Survivorship). Follow-up with the speech-language pathologist should continue at least until the patient has achieved a stable baseline following treatment. For some patients with chronic speech and swallowing challenges, this follow-up may need to be indefinite.**
  - **Maintain and/or improve oropharyngeal movement through range of motion and strengthening exercises.**
    - **◊ Practice gentle stretching**
    - **◊ Consider pentoxifylline and vitamin E in patients at high risk for trismus**
    - **◊ Custom mouth-opening devices for rehabilitation of trismus and active and passive range of jaw motion**
    - **◊ Lymphatic decompression therapy to prevent fibrosis and improve range of motion**
    - **◊ Prophylactic and/or rehabilitative pharyngeal strengthening exercises and expiratory strength training**
  - **Patients with tracheostomy**
    - **◊ Facilitating communication, humidification, swallowing, and working towards de-cannulation with head and neck surgeon, respiratory therapy, and speech language pathology teams as indicated.**

Note: All recommendations are category 2A unless otherwise indicated.

References

Version 1.2026, 12/08/2025 © 2025 National Comprehensive Cancer Network® (NCCN®), All rights reserved. NCCN Guidelines® and this illustration may not be reproduced in any form without the express written permission of NCCN.

PLEASE NOTE that use of this NCCN Content is governed by the End-User License Agreement, and you MAY NOT distribute this Content or use it with any artificial intelligence model or tool.
Printed by Galya Basol Kochav on 1/4/2026 9:40:35 AM. Copyright © 2026 National Comprehensive Cancer Network, Inc. All Rights Reserved.

PRINCIPLES OF NUTRITION: MANAGEMENT AND SUPPORTIVE CARE[1-3]

Assessment and Management Continued

- **Pain**
  - **Assess pain from oral mucositis and consider prescribing pregabalin (category 2B),[4] gabapentin,[5] doxepin,[6,7] or diphenhydramine/lidocaine/antacid mouthwash[6] as clinically indicated.**
  - **Consider referral to dentistry/oral medicine and/or supportive medicine for assistance in functional assessments, symptom palliation, and functional rehabilitation of patients with head and neck cancer.**

Use of Alternative Routes for Nutrition (feeding tubes)

- **The Panel does not recommend prophylactic feeding tube placement in patients with very good PS and without significant pretreatment weight loss, significant airway obstruction, or severe dysphagia.**

- **Prophylactic feeding tube placement should be strongly considered for patients with:**
  - **Severe weight loss prior to treatment, 5% weight loss over prior 1 month, or 10% weight loss over 6 months;**
  - **Ongoing dehydration or dysphagia, anorexia, or pain interfering with the ability to eat/drink adequately;**
  - **Significant comorbidities that may be aggravated by poor tolerance of dehydration, lack of caloric intake, or difficulty swallowing necessary medications;**
  - **Severe aspiration; or mild aspiration in patients who are older or have compromised cardiopulmonary function; or**
  - **Patients for whom long-term swallowing disorders are likely, including those anticipated to receive large fields of high-dose radiation to the mucosa and adjacent connective tissues. However, consideration of other risk factors for swallowing dysfunction must be taken into account as well.**
- **For those who did not warrant prophylactic feeding tube placement pre-treatment, caloric intake, treatment-related side effects, and change in body weight should be monitored weekly during treatment.[8] Consider reactive feeding tube placement if two or more of the following criteria apply:**
  - **Inadequate food intake (60% of estimated energy expenditure) anticipated for >10 days.[9]**
  - **Weight loss of ≥5% in 1 month**
  - **Severe mucositis/mucosal pain, odynophagia, dysphagia (grade 3+), or aspiration**
  - **Age >60 years[10]**
- **To maintain swallowing function during and following treatment (eg, radiation), patients who may have feeding tube placement should be encouraged to intake orally if they can swallow without, or with minimal, aspiration or any other compromises. Alterations in swallowing function can occur long after treatment (especially after radiation-based treatment) and should be monitored for the lifetime of the patient.**

Note: All recommendations are category 2A unless otherwise indicated.

References

Version 1.2026, 12/08/2025 © 2025 National Comprehensive Cancer Network® (NCCN®), All rights reserved. NCCN Guidelines® and this illustration may not be reproduced in any form without the express written permission of NCCN.

PLEASE NOTE that use of this NCCN Content is governed by the End-User License Agreement, and you MAY NOT distribute this Content or use it with any artificial intelligence model or tool.
Printed by Galya Basol Kochav on 1/4/2026 9:40:35 AM. Copyright © 2026 National Comprehensive Cancer Network, Inc. All Rights Reserved.

PRINCIPLES OF NUTRITION: MANAGEMENT AND SUPPORTIVE CARE
REFERENCES

[1] Ehrsson YT, Langius-Eklöf A, Laurell G. Nutritional surveillance and weight loss in head and neck cancer patients. Support Care Cancer 2012;20:757-765.
[2] Locher JL, Bonner JA, Carroll WR, et al. Prophylactic percutaneous endoscopic gastrostomy tube placement in treatment of head and neck cancer: a comprehensive review and call for evidence-based medicine. JPEN J Parenter Enteral Nutr 2011;35:365-374.
[3] Langius JA, van Dijk AM, Doornaert P, et al. More than 10% weight loss in head and neck cancer patients during radiotherapy is independently associated with deterioration in quality of life. Nutr Cancer 2013;65:76-83.
[4] Lefebvre T, Tack L, Lycke M, et al. Effectiveness of adjunctive analgesics in head and neck cancer patients receiving curative (chemo-) radiotherapy: a systematic review. Pain Med 2021;22:152-164.
[5] Bar Ad V, Weinstein G, Dutta PR, et al. Gabapentin for the treatment of pain syndrome related to radiation-induced mucositis in patients with head and neck cancer treated with concurrent chemoradiotherapy. Cancer 2010;116:4206-4213.
[6] Leenstra JL, Miller RC, Qin R, et al. Doxepin rinse versus placebo in the treatment of acute oral mucositis pain in patients receiving head and neck radiotherapy with or without chemotherapy: a phase III, randomized, double-blind trial (NCCTG-N09C6 [Alliance]). J Clin Oncol 2014;32:1571-1577.
[7] Sio TT, Le-Rademacher JG, Leenstra JL, et al. Effect of doxepin mouthwash or diphenhydramine-lidocaine-antacid mouthwash vs placebo on radiotherapy-related oral mucositis pain: the Alliance A221304 randomized clinical trial. JAMA 2019;321:1481-1490.
[8] Bossola M. Nutritional intervention in head and neck cancer patients undergoing chemoradiotherapy: A narrative review. Nutrients 2015;7:265-276.
[9] Talwar B, Donnelly R, Skelly R, et al. Nutritional management in the head and neck cancer: United Kingdom National Multidisciplinary Guidelines. J Laryngol Otol 2016;130;s32-s40.
[10] Sachdev S, Refaat T, Bacchus ID, et al. Age most significant predictor of requiring enteral feeding in head-and-neck cancer patients. Radiat Oncol 2015;10:93.

Note: All recommendations are category 2A unless otherwise indicated.

Version 1.2026, 12/08/2025 © 2025 National Comprehensive Cancer Network® (NCCN®), All rights reserved. NCCN Guidelines® and this illustration may not be reproduced in any form without the express written permission of NCCN.

PLEASE NOTE that use of this NCCN Content is governed by the End-User License Agreement, and you MAY NOT distribute this Content or use it with any artificial intelligence model or tool.
Printed by Galya Basol Kochav on 1/4/2026 9:40:35 AM. Copyright © 2026 National Comprehensive Cancer Network, Inc. All Rights Reserved.

PRINCIPLES OF ORAL/DENTAL EVALUATION AND MANAGEMENT[1,2]

RT to the head and neck causes xerostomia and salivary gland dysfunction, which dramatically increases the risk of dental caries and its sequelae, including dentoalveolar infection and osteoradionecrosis. RT also affects the dental hard tissues, which increases their susceptibility to demineralization[3] within the presence of xerostomia, microbial changes following RT, and changes to a more cariogenic diet. IMRT and salivary gland-sparing techniques are associated with dose-dependent recovery of salivary function over time[4] and with reduced risk for dental caries long term for some patients.[5] Radiation-related caries and other dental hard tissue changes can appear within the first 3 months following RT.[6,7]

Goals of Pre-RT Oral/Dental Evaluation:

1. Patient education, both oral and written, regarding oral and dental complications of RT and need for adherence with preventive protocols

- **Effect on salivary glands**
  - **Dry mouth strategies**
    - ◊ **Increase hydration**
    - ◊ **Minimize ingestion of caffeinated products and alcohol**
    - ◊ **Salivary stimulation**
      - – **Gustatory stimulants (eg, xylitol chewing gum, sorbitol/malic acid lozenges, xylitol lozenges)**
      - – **Cholinergic agonists (eg, pilocarpine, cevimeline)[8,9]**
    - ◊ **Salivary substitutes (eg, gels containing lysozyme, lactoferrin, peroxidase, and supersaturated calcium phosphate solutions)[10]**
    - ◊ **Alcohol-free mouthwash (stabilized 0.1% chlorine dioxide oral rinse preferred)**
  - **Dental caries prevention**
    - ◊ **Diet counseling**
    - ◊ **Meticulous oral hygiene**
      - – **Brushing teeth twice daily**
      - – **Floss or interdental cleaner daily**
      - – **Alcohol-free mouthwash twice daily**
    - ◊ **High-potency topical fluoride – continue long term after therapy**
      - – **Daily 1.1% NaF gel or SNF_2 gel, brush on or in custom dental trays; or**
      - – **Daily 1.1% NaF dentifrice; or**
      - – **Fluoride varnish application, three times per year; or**
      - – **Calcium phosphate artificial saliva rinse/cream/gel**
    - ◊ **Regular frequent dental evaluations to detect dental disease**
    - ◊ **Candidiasis prevention and control**
      - – **Topical therapy (anti-fungal lozenges[a] or suspensions)**
      - – **Systemic antifungal therapy if refractory to topicals (consider infectious disease consult)**
- **Effect on bone in irradiated field**
  - **Need for pre-RT dental evaluation and determine need for dental extractions[5,11,12]**
    - ◊ **If yes, should be completed at least 2 weeks prior to start of RT**
    - ◊ **Long-term prognosis of teeth and patient motivation should be considered**
    - ◊ **Need to contact oncology team if any future extractions or surgery in irradiated field**
- **Effect on masticatory muscles – potential for trismus[6,7]**
  - **See Principles of Nutrition: Speech and Swallowing (NUTR-A)**

[a] For long-term use of anti-fungal lozenges, sugar-free lozenges are recommended for dental caries prevention.

Note: All recommendations are category 2A unless otherwise indicated.

References

Version 1.2026, 12/08/2025 © 2025 National Comprehensive Cancer Network® (NCCN®), All rights reserved. NCCN Guidelines® and this illustration may not be reproduced in any form without the express written permission of NCCN.

PLEASE NOTE that use of this NCCN Content is governed by the End-User License Agreement, and you MAY NOT distribute this Content or use it with any artificial intelligence model or tool.
Printed by Galya Basol Kochav on 1/4/2026 9:40:35 AM. Copyright © 2026 National Comprehensive Cancer Network, Inc. All Rights Reserved.

PRINCIPLES OF ORAL/DENTAL EVALUATION AND MANAGEMENT[1,2]

Goals of Pre-RT Oral/Dental Evaluation—(continued):

2. Examination and assessment of patient with treatment plan[4]

- **Complete oral and head and neck examination, including radiographs of all teeth**
- **Risk assessment for caries and periodontal disease**
  - **Existing periodontal and dental conditions**
  - **Radiographic evidence of periapical pathology**
  - **Oral hygiene**
  - **Past dental history**
  - **Patient motivation and adherence**
- **Treatment plan**
  - **Eliminate potential sources of infection**
  - **Perform extractions at least 2 weeks before start of RT**
  - **Treat active dental caries and periodontal disease**
  - **Use silicone guards to minimize radiation backscatter, if patients have metal restorations**
  - **Prescribe potent topical fluoride for daily use. Duration of use to be determined by periodic caries risk assessment over time**
  - **Schedule return visit for re-evaluation and reinforcement of preventive protocol for 6–12 weeks after completion of RT**
  - **Evaluate for oral candidiasis and treat appropriately with antifungal agents**

Goals of Oral/Dental Management During Cancer Therapy:

1. Manage xerostomia
2. Prevent trismus of masticatory muscles
3. Evaluate for oral candidiasis and treat as clinically indicated

Goals of Oral/Dental Management Post-Treatment[13]:

1. Manage xerostomia
2. Prevent and minimize trismus
3. Prevent and treat dental caries
4. Prevent and manage post-radiation osteonecrosis[14]
  - **Stabilized 0.1% chlorine dioxide oral rinse[15]**
5. Prevent and manage oral candidiasis
6. Consultation with treating radiation oncologist is recommended before considering implants or extraction

Dental recall visit interval is based on risk, at least once every 6 months, or more frequently for those with xerostomia, or for those with new caries or lesions following radiotherapy.

Note: All recommendations are category 2A unless otherwise indicated.

References

Version 1.2026, 12/08/2025 © 2025 National Comprehensive Cancer Network® (NCCN®), All rights reserved. NCCN Guidelines® and this illustration may not be reproduced in any form without the express written permission of NCCN.

PLEASE NOTE that use of this NCCN Content is governed by the End-User License Agreement, and you MAY NOT distribute this Content or use it with any artificial intelligence model or tool.
Printed by Galya Basol Kochav on 1/4/2026 9:40:35 AM. Copyright © 2026 National Comprehensive Cancer Network, Inc. All Rights Reserved.

PRINCIPLES OF ORAL/DENTAL EVALUATION AND MANAGEMENT
REFERENCES

[1] Epstein JB, Barasch A. Oral and dental health in head and neck cancer patients. Cancer Treat Res 2018;174:43-57.
[2] Sroussi HY, Epstein JB, Bensadoun RJ, et al. Common oral complications of head and neck cancer radiation therapy: mucositis, infections, saliva change, fibrosis, sensory dysfunctions, dental caries, periodontal disease, and osteoradionecrosis. Cancer Med 2017;6:2918-2931.
[3] Walker MP, Wichman B, Cheng AL, et al. Impact of radiotherapy dose on dentition breakdown in head and neck cancer patients. Pract Radiat Oncol 2011;1:142-148.
[4] Little M, Schipper M, Feng FY, et al. Reducing xerostomia after chemo-IMRT for head-and-neck cancer: beyond sparing the parotid glands. Int J Radiat Oncol Biol Phys 2012; 83:1007-1014.
[5] Studer G, Glanzmann C, Studer SP, et al. Risk-adapted dental care prior to intensity-modulated radiotherapy (IMRT). Schweiz Monatsschr Zahnmed 2011;121:216-229.
[6] Murdoch-Kinch CA, Zwetchkenbaum S. Dental management of the head and neck cancer patient treated with radiation therapy. J Mich Dent Assoc 2011;93:28-37.
[7] Epstein JB, Thariat J, Bensadoun RJ, et al. Oral complications of cancer and cancer therapy: from cancer treatment to survivorship. CA Cancer J Clin 2012;62:400-422.
[8] Gorsky M, Epstein JB, Parry J, et al. The efficacy of pilocarpine and bethanechol upon saliva production in cancer patients with hyposalivation following radiation therapy. Oral Surg Oral Med Oral Pathol Oral Radiol Endod 2004;97:190-195.
[9] Jensen SB, Pedersen AM, Vissink A, et al. A systematic review of salivary gland hypofunction and xerostomia induced by cancer therapies: management strategies and economic impact. Support Care Cancer 2010;18:1061-1079.
[10] Singh ML, Papas AS. Long-term clinical observation of dental caries in salivary hypofunction patients using a supersaturated calcium-phosphate remineralizing rinse. J Clin Dent 2009;20:87-92.
[11] Gomez DR, Estilo CL, Wolden SL, et al. Correlation of osteoradionecrosis and dental events with dosimetric parameters in intensity-modulated radiation therapy for head-and-neck cancer. Int J Radiat Oncol Biol Phys 2011;81:e207-e213.
[12] Lee IJ, Koom WS, Lee CG, et al. Risk factors and dose-effect relationship for mandibular osteoradionecrosis in oral and oropharyngeal cancer patients. Int J Radiat Oncol Biol Phys 2009;75:1084-1091.
[13] Lalla RV, Treister N, Sollecito T, et al. Oral complications at 6 months after radiation therapy for head and neck cancer. Oral Dis 2017;23:1134-1143.
[14] Peterson DE, Koyfman SA, Yarom N, et al. Prevention and management of osteoradionecrosis in patients with head and neck cancer treated with radiation therapy: ISOO-MASCC-ASCO guideline. J Clin Oncol 2024;42:1975-1996.
[15] Myneni Venkatasatya SR, Wang HH, Alluri S, Ciancio SG. Phosphate buffer-stabilized 0.1% chlorine dioxide oral rinse for managing medication-related osteonecrosis of the jaw. Am J Dent 2017;30:350-352.

Note: All recommendations are category 2A unless otherwise indicated.

Version 1.2026, 12/08/2025 © 2025 National Comprehensive Cancer Network® (NCCN®), All rights reserved. NCCN Guidelines® and this illustration may not be reproduced in any form without the express written permission of NCCN.

PLEASE NOTE that use of this NCCN Content is governed by the End-User License Agreement, and you MAY NOT distribute this Content or use it with any artificial intelligence model or tool.
Printed by Galya Basol Kochav on 1/4/2026 9:40:35 AM. Copyright © 2026 National Comprehensive Cancer Network, Inc. All Rights Reserved.

Table 1
American Joint Committee on Cancer (AJCC)
TNM Staging Classification for the Oral Cavity (including mucosa of lip) (8th ed., 2017)
(Nonepithelial tumors such as those of lymphoid tissue, soft tissue, bone, and cartilage, mucosal melanoma, and cutaneous squamous cell carcinoma of the vermilion lip are not included)

Primary Tumor (T)

TX		Primary tumor cannot be assessed
Tis		Carcinoma *in situ*
T1		Tumor ≤2 cm with depth of invasion (DOI)* ≤5 mm
T2		Tumor ≤2 cm, with DOI* >5 mm *or* tumor >2 cm and ≤4 cm, with DOI* ≤10 mm
T3		Tumor >2 cm and ≤4 cm, with DOI* >10 mm *or* tumor >4 cm, with DOI* ≤10 mm
T4		Moderately advanced or very advanced local disease
	T4a	Moderately advanced local disease Tumor >4 cm, with DOI* >10 mm *or* tumor invades adjacent structures only (eg, through cortical bone of the mandible or maxilla, or involves the maxillary sinus or skin of the face) Note: Superficial erosion of bone/tooth socket (alone) by a gingival primary is not sufficient to classify a tumor as T4.
	T4b	Very advanced local disease Tumor invades masticator space, pterygoid plates, or skull base and/or encases the internal carotid artery

*DOI is depth of invasion and *not* tumor thickness.

Regional Lymph Nodes (N)

Clinical N (cN)

NX		Regional lymph nodes cannot be assessed
N0		No regional lymph node metastasis
N1		Metastasis in a single ipsilateral lymph node, 3 cm or smaller in greatest dimension ENE(–)
N2		Metastasis in a single ipsilateral node larger than 3 cm but not larger than 6 cm in greatest dimension and ENE(–); *or* metastases in multiple ipsilateral lymph nodes, none larger than 6 cm in greatest dimension and ENE(–); *or* in bilateral or contralateral lymph nodes, none larger than 6 cm in greatest dimension, and ENE(–)
	N2a	Metastasis in a single ipsilateral lymph node larger than 3 cm but not larger than 6 cm in greatest dimension, and ENE(–)
	N2b	Metastases in multiple ipsilateral lymph nodes, none larger than 6 cm in greatest dimension, and ENE(–)
	N2c	Metastases in bilateral or contralateral lymph nodes, none larger than 6 cm in greatest dimension, and ENE(–)
N3		Metastasis in a lymph node larger than 6 cm in greatest dimension and ENE(−); *or* metastasis in any node(s) and clinically overt ENE(+)
	N3a	Metastasis in a lymph node larger than 6 cm in greatest dimension and ENE(−)
	N3b	Metastasis in any node(s) and clinically overt ENE(+)

Note: A designation of "U" or "L" may be used for any N category to indicate metastasis above the lower border of the cricoid (U) or below the lower border of the cricoid (L). Similarly, clinical and pathological ENE should be recorded as ENE(−) or ENE(+).

Used with permission of the American College of Surgeons, Chicago, Illinois. The original source for this information is the AJCC Cancer Staging Manual, Eighth Edition (2017) published by Springer International Publishing. (For complete information and data supporting the staging tables, visit www.springer.com.)

Version 1.2026, 12/08/2025 © 2025 National Comprehensive Cancer Network® (NCCN®), All rights reserved. NCCN Guidelines® and this illustration may not be reproduced in any form without the express written permission of NCCN.

PLEASE NOTE that use of this NCCN Content is governed by the End-User License Agreement, and you MAY NOT distribute this Content or use it with any artificial intelligence model or tool.
Printed by Galya Basol Kochav on 1/4/2026 9:40:35 AM. Copyright © 2026 National Comprehensive Cancer Network, Inc. All Rights Reserved.

Table 1 — Continued
American Joint Committee on Cancer (AJCC)
TNM Staging Classification for the Oral Cavity (including mucosa of lip) (8th ed., 2017)
(Nonepithelial tumors such as those of lymphoid tissue, soft tissue, bone, and cartilage, mucosal melanoma, and cutaneous squamous cell carcinoma of the vermilion lip are not included)

Regional Lymph Nodes (N)

Pathological N (pN)

NX Regional lymph nodes cannot be assessed

N0 No regional lymph node metastasis

N1 Metastasis in a single ipsilateral lymph node, 3 cm or smaller in greatest dimension and ENE(–)

N2 Metastasis in a single ipsilateral lymph node, 3 cm or smaller in greatest dimension and ENE(+); *or* larger than 3 cm but not larger than 6 cm in greatest dimension and ENE(–); *or* metastases in multiple ipsilateral lymph nodes, none larger than 6 cm in greatest dimension and ENE(−); *or* in bilateral or contralateral lymph node(s), none larger than 6 cm in greatest dimension, ENE(−)

- N2a Metastasis in single ipsilateral node 3 cm or smaller in greatest dimension, and ENE(+); *or* a single ipsilateral node larger than 3 cm but not larger than 6 cm in greatest dimension and ENE(–)
- N2b Metastases in multiple ipsilateral node(s), none larger than 6 cm in greatest dimension and ENE(−)
- N2c Metastases in bilateral or contralateral lymph node(s), none larger than 6 cm in greatest dimension, and ENE(–)

N3 Metastasis in a lymph node larger than 6 cm in greatest dimension and ENE(−); *or* metastasis in a single ipsilateral node larger than 3 cm in greatest dimension and ENE(+); *or* multiple ipsilateral, contralateral or bilateral nodes any with ENE(+); *or* a single contralateral node of any size and ENE (+)

- N3a Metastasis in a lymph node larger than 6 cm in greatest dimension and ENE(−)
- N3b Metastasis in a single ipsilateral node larger than 3 cm in greatest dimension and ENE(+); *or* multiple ipsilateral, contralateral or bilateral nodes any with ENE(+); *or* a single contralateral node of any size and ENE (+)

Note: A designation of “U” or “L” may be used for any N category to indicate metastasis above the lower border of the cricoid (U) or below the lower border of the cricoid (L).
Similarly, clinical and pathological ENE should be recorded as ENE(−) or ENE(+).

Distant Metastasis (M)

M0 No distant metastasis

M1 Distant metastasis

Histologic Grade (G)

GX Cannot be assessed

G1 Well differentiated

G2 Moderately differentiated

G3 Poorly differentiated

Prognostic Stage Groups

Stage 0	Tis	N0	M0
Stage I	T1	N0	M0
Stage II	T2	N0	M0
Stage III	T1,T2	N1	M0
	T3	N0,N1	M0
Stage IVA	T1	N2	M0
	T2	N2	M0
	T3	N2	M0
	T4a	N0,N1,N2	M0
Stage IVB	Any T	N3	M0
	T4b	Any N	M0
Stage IVC	Any T	Any N	M1

Used with permission of the American College of Surgeons, Chicago, Illinois. The original source for this information is the AJCC Cancer Staging Manual, Eighth Edition (2017) published by Springer International Publishing. (For complete information and data supporting the staging tables, visit www.springer.com.)

Version 1.2026, 12/08/2025 © 2025 National Comprehensive Cancer Network® (NCCN®), All rights reserved. NCCN Guidelines® and this illustration may not be reproduced in any form without the express written permission of NCCN.

PLEASE NOTE that use of this NCCN Content is governed by the End-User License Agreement, and you MAY NOT distribute this Content or use it with any artificial intelligence model or tool.
Printed by Galya Basol Kochav on 1/4/2026 9:40:35 AM. Copyright © 2026 National Comprehensive Cancer Network, Inc. All Rights Reserved.

Table 2
American Joint Committee on Cancer (AJCC)
TNM Staging System for the Nasopharynx (9th ed., 2021)
(The following types of cancer are not included: Mucosal melanoma, lymphoma, sarcoma of the soft tissue, bone and cartilage.)

Primary Tumor (T)

TX Primary tumor cannot be assessed

T0 No tumor identified, but EBV-positive cervical node(s) involvement

Tis Carcinoma *in situ*

T1 Tumor confined to nasopharynx, or extension to oropharynx and/or nasal cavity without parapharyngeal involvement

T2 Tumor with extension to parapharyngeal space, and/or adjacent soft tissue involvement (medial pterygoid, lateral pterygoid, prevertebral muscles)

T3 Tumor with unequivocal infiltration of bony structures at skull base, cervical vertebra, pterygoid structures, and/or paranasal sinuses

T4 Tumor with intracranial extension, involvement of cranial nerves, hypopharynx, orbit, parotid gland, and/ or extensive soft tissue infiltration beyond the anterolateral surface of the lateral pterygoid muscle

Regional Lymph Nodes (N)

NX Regional lymph nodes cannot be assessed

N0 No regional lymph node metastasis

N1 Unilateral metastasis in cervical lymph node(s) and/or unilateral or bilateral metastasis in retropharyngeal lymph node(s), 6 cm or smaller in greatest dimension, above the caudal border of cricoid cartilage without advanced extranodal extension

N2 Bilateral metastasis in cervical lymph node(s), 6 cm or smaller in greatest dimension, above the caudal border of cricoid cartilage without advanced extranodal extension

N3 Unilateral or bilateral metastasis in cervical lymph node(s), larger than 6 cm in greatest dimension, and/or extension below the caudal border of cricoid cartilage, advanced radiologic extranodal extension with involvement of adjacent muscles, skin, and/or neurovascular bundle

Distant Metastasis (M)

M0 The cancer has not spread to distant parts of the body

M1a The cancer has spread to distant parts of the body, but there are no more than 3 areas of cancer spread

M1b The cancer has spread to distant parts of the body, and there are more than 3 areas of cancer spread

Histologic Grade (G)
A grading system is not used for NPCs.

Anatomic Stage/Prognostic Groups

Stage 0	Tis	N0	M0
Stage IA	T1 to T2	N0	M0
Stage IB	T0 to T2	N1	M0
Stage II	T0 to T2	N2	M0
	T3	N0 to N2	M0
Stage III	T4	Any N	M0
	Any T	N3	M0
Stage IVA	Any T	Any N	M1a
Stage IVB	Any T	Any N	M1b

©, 2021, American College of Surgeons, All Rights Reserved. *Used with permission of the American College of Surgeons, Chicago, Illinois. The original source for this information is the AJCC Cancer Staging System*.

Version 1.2026, 12/08/2025 © 2025 National Comprehensive Cancer Network® (NCCN®), All rights reserved. NCCN Guidelines® and this illustration may not be reproduced in any form without the express written permission of NCCN.

PLEASE NOTE that use of this NCCN Content is governed by the End-User License Agreement, and you MAY NOT distribute this Content or use it with any artificial intelligence model or tool.
Printed by Galya Basol Kochav on 1/4/2026 9:40:35 AM. Copyright © 2026 National Comprehensive Cancer Network, Inc. All Rights Reserved.

Table 3
American Joint Committee on Cancer (AJCC)
TNM Staging System for the Oropharynx (p16-) and Hypopharynx (8th ed., 2017)
(Not included: P16-positive (p16+) oropharyngeal cancers and nasopharyngeal cancer)

Oropharynx (p16-)

TX		Primary tumor cannot be assessed
Tis		Carcinoma *in situ*
T1		Tumor 2 cm or smaller in greatest dimension
T2		Tumor larger than 2 cm but not larger than 4 cm in greatest dimension
T3		Tumor larger than 4 cm in greatest dimension or extension to lingual surface of epiglottis
T4		Moderately advanced or very advanced local disease
	T4a	Moderately advanced local disease Tumor invades the larynx, extrinsic muscle of tongue, medial pterygoid, hard palate, or mandible*
	T4b	Very advanced local disease Tumor invades lateral pterygoid muscle, pterygoid plates, lateral nasopharynx, or skull base or encases carotid artery

**Note:* Mucosal extension to lingual surface of epiglottis from primary tumors of the base of the tongue and vallecula does not constitute invasion of the larynx.

Hypopharynx

TX		Primary tumor cannot be assessed
Tis		Carcinoma *in situ*
T1		Tumor limited to one subsite of hypopharynx and/or 2 cm or smaller in greatest dimension
T2		Tumor invades more than one subsite of hypopharynx or an adjacent site, or measures larger than 2 cm but not larger than 4 cm in greatest dimension without fixation of hemilarynx
T3		Tumor larger than 4 cm in greatest dimension or with fixation of hemilarynx or extension to esophageal mucosa
T4		Moderately advanced or very advanced local disease
	T4a	Moderately advanced local disease Tumor invades thyroid/cricoid cartilage, hyoid bone, thyroid gland, esophageal muscle or central compartment soft tissue*
	T4b	Very advanced local disease Tumor invades prevertebral fascia, encases carotid artery, or involves mediastinal structures

**Note:* Central compartment soft tissue includes prelaryngeal strap muscles and subcutaneous fat.

Used with permission of the American College of Surgeons, Chicago, Illinois. The original source for this information is the AJCC Cancer Staging Manual, Eighth Edition (2017) published by Springer International Publishing. (For complete information and data supporting the staging tables, visit www.springer.com.)

Version 1.2026, 12/08/2025 © 2025 National Comprehensive Cancer Network® (NCCN®), All rights reserved. NCCN Guidelines® and this illustration may not be reproduced in any form without the express written permission of NCCN.

PLEASE NOTE that use of this NCCN Content is governed by the End-User License Agreement, and you MAY NOT distribute this Content or use it with any artificial intelligence model or tool.
Printed by Galya Basol Kochav on 1/4/2026 9:40:35 AM. Copyright © 2026 National Comprehensive Cancer Network, Inc. All Rights Reserved.

Table 3 — Continued
American Joint Committee on Cancer (AJCC)
TNM Staging System for the Oropharynx (p16-) and Hypopharynx (8th ed., 2017)
(Not included: P16-positive (p16+) oropharyngeal cancers and nasopharyngeal cancer)

Regional Lymph Nodes (N)		
Clinical N (cN) - Oropharynx (p16-) and Hypopharynx		
NX		Regional lymph nodes cannot be assessed
N0		No regional lymph node metastasis
N1		Metastasis in a single ipsilateral lymph node, 3 cm or smaller in greatest dimension and ENE(−)
N2		Metastasis in a single ipsilateral node larger than 3 cm but not larger than 6 cm in greatest dimension and ENE(–); *or* metastases in multiple ipsilateral lymph nodes, none larger than 6 cm in greatest dimension and ENE(−); *or* in bilateral or contralateral lymph nodes, none larger than 6 cm in greatest dimension and ENE(−)
	N2a	Metastasis in a single ipsilateral node larger than 3 cm but not larger than 6 cm in greatest dimension and ENE(−)
	N2b	Metastases in multiple ipsilateral nodes, none larger than 6 cm in greatest dimension and ENE(−)
	N2c	Metastases in bilateral or contralateral lymph nodes, none larger than 6 cm in greatest dimension and ENE(−)
N3		Metastasis in a lymph node larger than 6 cm in greatest dimension and ENE(−); *or* metastasis in any node(s) and clinically overt ENE(+)
	N3a	Metastasis in a lymph node larger than 6 cm in greatest dimension and ENE(−)
	N3b	Metastasis in any node(s) and clinically overt ENE(+)

Note: A designation of “U” or “L” may be used for any N category to indicate metastasis above the lower border of the cricoid (U) or below the lower border of the cricoid (L).
Similarly, clinical and pathological ENE should be recorded as ENE(−) or ENE(+).

Used with permission of the American College of Surgeons, Chicago, Illinois. The original source for this information is the AJCC Cancer Staging Manual, Eighth Edition (2017) published by Springer International Publishing. (For complete information and data supporting the staging tables, visit www.springer.com.)

Version 1.2026, 12/08/2025 © 2025 National Comprehensive Cancer Network® (NCCN®), All rights reserved. NCCN Guidelines® and this illustration may not be reproduced in any form without the express written permission of NCCN.

PLEASE NOTE that use of this NCCN Content is governed by the End-User License Agreement, and you MAY NOT distribute this Content or use it with any artificial intelligence model or tool.
Printed by Galya Basol Kochav on 1/4/2026 9:40:35 AM. Copyright © 2026 National Comprehensive Cancer Network, Inc. All Rights Reserved.

Table 3 — Continued
American Joint Committee on Cancer (AJCC)
TNM Staging System for the Oropharynx (p16-) and Hypopharynx (8th ed., 2017)
(Not included: P16-positive (p16+) oropharyngeal cancers and nasopharyngeal cancer)

Regional Lymph Nodes (N):
Pathological N (pN) - Oropharynx (p16-) and Hypopharynx

NX		Regional lymph nodes cannot be assessed
N0		No regional lymph node metastasis
N1		Metastasis in a single ipsilateral lymph node, 3 cm or smaller in greatest dimension and ENE(−)
N2		Metastasis in a single ipsilateral lymph node, 3 cm or smaller in greatest dimension and ENE(+); *or* larger than 3 cm but not larger than 6 cm in greatest dimension and ENE(−); *or* metastases in multiple ipsilateral lymph nodes, none larger than 6 cm in greatest dimension and ENE(−); *or* in bilateral or contralateral lymph node(s), none larger than 6 cm in greatest dimension and ENE(−)
	N2a	Metastasis in single ipsilateral node 3 cm or smaller in greatest dimension and ENE(+); *or* a single ipsilateral node larger than 3 cm but not larger than 6 cm in greatest dimension and ENE(−)
	N2b	Metastases in multiple ipsilateral nodes, none larger than 6 cm in greatest dimension and ENE(−)
	N2c	Metastases in bilateral or contralateral lymph node(s), none larger than 6 cm in greatest dimension and ENE(−)
N3		Metastasis in a lymph node larger than 6 cm in greatest dimension and ENE(−); *or* in a single ipsilateral node larger than 3 cm in greatest dimension and ENE(+); *or* multiple ipsilateral, contralateral or bilateral nodes, any with ENE(+); *or* a single contralateral node of any size and ENE(+)
	N3a	Metastasis in a lymph node larger than 6 cm in greatest dimension and ENE(−)
	N3b	Metastasis in a single ipsilateral node larger than 3 cm in greatest dimension and ENE(+); *or* multiple ipsilateral, contralateral or bilateral nodes, any with ENE(+) *or* a single contralateral node of any size and ENE(+)

Note: A designation of "U" or "L" may be used for any N category to indicate metastasis above the lower border of the cricoid (U) or below the lower border of the cricoid (L).
Similarly, clinical and pathological ENE should be recorded as ENE(−) or ENE(+).

Distant Metastasis (M)

M0	No distant metastasis
M1	Distant metastasis

Histologic Grade (G)

GX	Grade cannot be assessed
G1	Well differentiated
G2	Moderately differentiated
G3	Poorly differentiated
G4	Undifferentiated

Prognostic Stage Groups

Stage 0	Tis	N0	M0
Stage I	T1	N0	M0
Stage II	T2	N0	M0
Stage III	T3	N0	M0
	T1	N1	M0
	T2	N1	M0
	T3	N1	M0
Stage IVA	T1	N2	M0
	T2	N2	M0
	T3	N2	M0
	T4a	N0,N1,N2	M0
Stage IVB	T4b	Any N	M0
	Any T	N3	M0
Stage IVC	Any T	Any N	M1

Used with permission of the American College of Surgeons, Chicago, Illinois. The original source for this information is the AJCC Cancer Staging Manual, Eighth Edition (2017) published by Springer International Publishing. (For complete information and data supporting the staging tables, visit www.springer.com.)

Version 1.2026, 12/08/2025 © 2025 National Comprehensive Cancer Network® (NCCN®), All rights reserved. NCCN Guidelines® and this illustration may not be reproduced in any form without the express written permission of NCCN.

PLEASE NOTE that use of this NCCN Content is governed by the End-User License Agreement, and you MAY NOT distribute this Content or use it with any artificial intelligence model or tool.
Printed by Galya Basol Kochav on 1/4/2026 9:40:35 AM. Copyright © 2026 National Comprehensive Cancer Network, Inc. All Rights Reserved.

Table 4
American Joint Committee on Cancer (AJCC)
TNM Staging System for HPV-Mediated (p16+) Oropharyngeal Cancer (8th ed., 2017)
(Not including: P16-negative (p16-) cancers of the oropharynx)

Primary Tumor (T)
T0 No primary identified
T1 Tumor 2 cm or smaller in greatest dimension
T2 Tumor larger than 2 cm but not larger than 4 cm in greatest dimension
T3 Tumor larger than 4 cm in greatest dimension or extension to lingual surface of epiglottis
T4 Moderately advanced local disease
Tumor invades the larynx, extrinsic muscle of tongue, medial pterygoid, hard palate, or mandible or beyond*

Mucosal extension to lingual surface of epiglottis from primary tumors of the base of the tongue and vallecula does not constitute invasion of the larynx.

Regional Lymph Nodes (N)
Clinical N (cN)
NX Regional lymph nodes cannot be assessed
N0 No regional lymph node metastasis
N1 One or more ipsilateral lymph nodes, none larger than 6 cm
N2 Contralateral or bilateral lymph nodes, none larger than 6 cm
N3 Lymph node(s) larger than 6 cm

Pathological N (pN)
NX Regional lymph nodes cannot be assessed
pN0 No regional lymph node metastasis
pN1 Metastasis in 4 or fewer lymph nodes
pN2 Metastasis in more than 4 lymph nodes

Distant Metastasis (M)
M0 No distant metastasis
M1 Distant metastasis

Histologic Grade (G)
No grading system exists for HPV-mediated oropharyngeal tumors

Prognostic Stage Groups

Clinical

Stage I	T0,T1,T2	N0,N1	M0
Stage II	T0,T1,T2	N2	M0
	T3	N0,N1,N2	M0
Stage III	T0,T1,T2,T3	N3	M0
	T4	N0,N1,N2,N3	M0
Stage IV	Any T	Any N	M1

Pathological

Stage I	T0,T1,T2	N0,N1	M0
Stage II	T0,T1,T2	N2	M0
	T3,T4	N0,N1	M0
Stage III	T3,T4	N2	M0
Stage IV	Any T	Any N	M1

Used with permission of the American College of Surgeons, Chicago, Illinois. The original source for this information is the AJCC Cancer Staging Manual, Eighth Edition (2017) published by Springer International Publishing. (For complete information and data supporting the staging tables, visit www.springer.com.)

Version 1.2026, 12/08/2025 © 2025 National Comprehensive Cancer Network® (NCCN®), All rights reserved. NCCN Guidelines® and this illustration may not be reproduced in any form without the express written permission of NCCN.

PLEASE NOTE that use of this NCCN Content is governed by the End-User License Agreement, and you MAY NOT distribute this Content or use it with any artificial intelligence model or tool.
Printed by Galya Basol Kochav on 1/4/2026 9:40:35 AM. Copyright © 2026 National Comprehensive Cancer Network, Inc. All Rights Reserved.

Table 5
American Joint Committee on Cancer (AJCC) TNM Staging System for the Larynx (8th ed., 2017)
(Nonepithelial tumors such as those of lymphoid tissue, soft tissue, bone and cartilage, and mucosal melanoma of the lip and oral cavity are not included)

Primary Tumor (T)

TX Primary tumor cannot be assessed

Tis Carcinoma *in situ*

Supraglottis

T1 Tumor limited to one subsite of supraglottis with normal vocal cord mobility

T2 Tumor invades mucosa of more than one adjacent subsite of supraglottis or glottis or region outside the supraglottis (eg, mucosa of base of tongue, vallecula, medial wall of pyriform sinus) without fixation of the larynx

T3 Tumor limited to larynx with vocal cord fixation and/or invades any of the following: postcricoid area, preepiglottic space, paraglottic space, and/or inner cortex of thyroid cartilage

T4 Moderately advanced or very advanced

T4a Moderately advanced local disease
Tumor invades through the outer cortex of the thyroid cartilage and/or invades tissues beyond the larynx (eg, trachea, soft tissues of neck including deep extrinsic muscle of the tongue, strap muscles, thyroid, or esophagus)

T4b Very advanced local disease
Tumor invades prevertebral space, encases carotid artery, or invades mediastinal structures

Glottis

T1 Tumor limited to the vocal cord(s) (may involve anterior or posterior commissure) with normal mobility

T1a Tumor limited to one vocal cord

T1b Tumor involves both vocal cords

T2 Tumor extends to supraglottis and/or subglottis, and/or with impaired vocal cord mobility

T3 Tumor limited to the larynx with vocal cord fixation and/or invasion of paraglottic space and/or inner cortex of the thyroid cartilage

T4 Moderately advanced or very advanced

T4a Moderately advanced local disease
Tumor invades through the outer cortex of the thyroid cartilage and/or invades tissues beyond the larynx (eg, trachea, cricoid cartilage, soft tissues of neck including deep extrinsic muscle of the tongue, strap muscles, thyroid, or esophagus)

T4b Very advanced local disease
Tumor invades prevertebral space, encases carotid artery, or invades mediastinal structures

Subglottis

T1 Tumor limited to the subglottis

T2 Tumor extends to vocal cord(s) with normal or impaired mobility

T3 Tumor limited to larynx with vocal cord fixation and/or inner cortex of the thyroid cartilage

T4 Moderately advanced or very advanced

T4a Moderately advanced local disease
Tumor invades cricoid or thyroid cartilage and/or invades tissues beyond the larynx (eg, trachea, soft tissues of neck including deep extrinsic muscles of the tongue, strap muscles, thyroid, or esophagus)

T4b Very advanced local disease
Tumor invades prevertebral space, encases carotid artery, or invades mediastinal structures

Used with permission of the American College of Surgeons, Chicago, Illinois. The original source for this information is the AJCC Cancer Staging Manual, Eighth Edition (2017) published by Springer International Publishing. (For complete information and data supporting the staging tables, visit www.springer.com.)

Version 1.2026, 12/08/2025 © 2025 National Comprehensive Cancer Network® (NCCN®), All rights reserved. NCCN Guidelines® and this illustration may not be reproduced in any form without the express written permission of NCCN.

PLEASE NOTE that use of this NCCN Content is governed by the End-User License Agreement, and you MAY NOT distribute this Content or use it with any artificial intelligence model or tool.
Printed by Galya Basol Kochav on 1/4/2026 9:40:35 AM. Copyright © 2026 National Comprehensive Cancer Network, Inc. All Rights Reserved.

Table 5 — Continued
American Joint Committee on Cancer (AJCC)
TNM Staging System for the Larynx (8th ed., 2017)
(Nonepithelial tumors such as those of lymphoid tissue, soft tissue, bone, and cartilage are not included)

Regional Lymph Nodes (N)

Clinical N (cN)

NX		Regional lymph nodes cannot be assessed
N0		No regional lymph node metastasis
N1		Metastasis in a single ipsilateral lymph node, 3 cm or smaller in greatest dimension ENE(–)
N2		Metastasis in a single ipsilateral node, larger than 3 cm but not larger than 6 cm in greatest dimension and ENE(–); *or* metastases in multiple ipsilateral lymph nodes, none larger than 6 cm in greatest dimension and ENE(–); *or* metastasis in bilateral or contralateral lymph nodes, none larger than 6 cm in greatest dimension and ENE(–)
	N2a	Metastasis in a single ipsilateral lymph node, larger than 3 cm but not larger than 6 cm in greatest dimension and ENE(–)
	N2b	Metastases in multiple ipsilateral lymph nodes, none larger than 6 cm in greatest dimension and ENE(–)
	N2c	Metastases in bilateral or contralateral lymph nodes, none larger than 6 cm in greatest dimension and ENE(–)
N3		Metastasis in a lymph node, larger than 6 cm in greatest dimension and ENE(–); *or* metastasis in any lymph node(s) with clinically overt ENE(+)
	N3a	Metastasis in a lymph node, larger than 6 cm in greatest dimension and ENE(−)
	N3b	Metastasis in any lymph node(s) with clinically overt ENE(+)

Note: A designation of “U” or “L” may be used for any N category to indicate metastasis above the lower border of the cricoid (U) or below the lower border of the cricoid (L).
Similarly, clinical and pathological ENE should be recorded as ENE(−) or ENE(+).

Used with permission of the American College of Surgeons, Chicago, Illinois. The original source for this information is the AJCC Cancer Staging Manual, Eighth Edition (2017) published by Springer International Publishing. (For complete information and data supporting the staging tables, visit www.springer.com.)

Version 1.2026, 12/08/2025 © 2025 National Comprehensive Cancer Network® (NCCN®), All rights reserved. NCCN Guidelines® and this illustration may not be reproduced in any form without the express written permission of NCCN.

PLEASE NOTE that use of this NCCN Content is governed by the End-User License Agreement, and you MAY NOT distribute this Content or use it with any artificial intelligence model or tool.
Printed by Galya Basol Kochav on 1/4/2026 9:40:35 AM. Copyright © 2026 National Comprehensive Cancer Network, Inc. All Rights Reserved.

Table 5 — Continued
American Joint Committee on Cancer (AJCC)
TNM Staging System for the Larynx (8th ed., 2017)
(Nonepithelial tumors such as those of lymphoid tissue, soft tissue, bone, and cartilage are not included)

Pathological N (pN)

NX Regional lymph nodes cannot be assessed
N0 No regional lymph node metastasis
N1 Metastasis in a single ipsilateral lymph node, 3 cm or smaller in greatest dimension ENE(–)
N2 Metastasis in a single ipsilateral lymph node, 3 cm or smaller in greatest dimension and ENE(+); *or* larger than 3 cm but not larger than 6 cm in greatest dimension and ENE(−); *or* metastases in multiple ipsilateral lymph nodes, none larger than 6 cm in greatest dimension and ENE(−); *or* in bilateral or contralateral lymph node(s), none larger than 6 cm in greatest dimension and ENE(−)
- N2a Metastasis in a single ipsilateral node, 3 cm or smaller in greatest dimension and ENE(+); *or* metastasis in a single ipsilateral node, larger than 3 cm but not larger than 6 cm in greatest dimension and ENE(−)
- N2b Metastases in multiple ipsilateral nodes, none larger than 6 cm in greatest dimension and ENE(−)
- N2c Metastases in bilateral or contralateral lymph node(s), none larger than 6 cm in greatest dimension and ENE(−)

N3 Metastasis in a lymph node, larger than 6 cm in greatest dimension and ENE(−); *or* metastasis in a single ipsilateral node, larger than 3 cm in greatest dimension and ENE(+); *or* multiple ipsilateral, contralateral, or bilateral lymph nodes and any with ENE(+); *or* a single contralateral node of any size and ENE(+)
- N3a Metastasis in a lymph node, larger than 6 cm in greatest dimension and ENE(−)
- N3b Metastasis in a single ipsilateral node, larger than 3 cm in greatest dimension and ENE(+); *or* multiple ipsilateral, contralateral, or bilateral lymph nodes any with ENE(+); or a single contralateral node of any size and ENE(+)

**Note:* A designation of "U" or "L" may be used for any N category to indicate metastasis above the lower border of the cricoid (U) or below the lower border of the cricoid (L).
Similarly, clinical and pathological ENE should be recorded as ENE(−) or ENE(+).

Distant Metastasis (M)

M0 No distant metastasis
M1 Distant metastasis

Histologic Grade (G)

GX Grade cannot be assessed
G1 Well differentiated
G2 Moderately differentiated
G3 Poorly differentiated

Prognostic Stage Groups

Stage 0	Tis	N0	M0
Stage I	T1	N0	M0
Stage II	T2	N0	M0
Stage III	T3	N0	M0
	T1	N1	M0
	T2	N1	M0
	T3	N1	M0
Stage IVA	T1	N2	M0
	T2	N2	M0
	T3	N2	M0
	T4a	N0,N1,N2	M0
Stage IVB	Any T	N3	M0
	T4b	Any N	M0
Stage IVC	Any T	Any N	M1

Used with permission of the American College of Surgeons, Chicago, Illinois. The original source for this information is the AJCC Cancer Staging Manual, Eighth Edition (2017) published by Springer International Publishing. (For complete information and data supporting the staging tables, visit www.springer.com.)

Version 1.2026, 12/08/2025 © 2025 National Comprehensive Cancer Network® (NCCN®), All rights reserved. NCCN Guidelines® and this illustration may not be reproduced in any form without the express written permission of NCCN.

PLEASE NOTE that use of this NCCN Content is governed by the End-User License Agreement, and you MAY NOT distribute this Content or use it with any artificial intelligence model or tool.
Printed by Galya Basol Kochav on 1/4/2026 9:40:35 AM. Copyright © 2026 National Comprehensive Cancer Network, Inc. All Rights Reserved.

Table 6
American Joint Committee on Cancer (AJCC)
TNM Staging System for the Nasal Cavity and Paranasal Sinuses (8th ed., 2017)
(Mucosal melanoma of the nasal cavity and paranasal sinuses are not included)

Primary Tumor (T)

TX Primary tumor cannot be assessed

Tis Carcinoma *in situ*

Maxillary Sinus

T1 Tumor limited to maxillary sinus mucosa with no erosion or destruction of bone

T2 Tumor causing bone erosion or destruction including extension into the hard palate and/or middle nasal meatus, except extension to posterior wall of maxillary sinus and pterygoid plates

T3 Tumor invades any of the following: bone of the posterior wall of maxillary sinus, subcutaneous tissues, floor or medial wall of orbit, pterygoid fossa, ethmoid sinuses

T4 Moderately advanced or very advanced local disease

T4a Moderately advanced local disease
Tumor invades anterior orbital contents, skin of cheek, pterygoid plates, infratemporal fossa, cribriform plate, sphenoid or frontal sinuses

T4b Very advanced local disease
Tumor invades any of the following: orbital apex, dura, brain, middle cranial fossa, cranial nerves other than maxillary division of trigeminal nerve (V2), nasopharynx, or clivus

Nasal Cavity and Ethmoid Sinus

T1 Tumor restricted to any one subsite, with or without bony invasion

T2 Tumor invading two subsites in a single region or extending to involve an adjacent region within the nasoethmoidal complex, with or without bony invasion

T3 Tumor extends to invade the medial wall or floor of the orbit, maxillary sinus, palate, or cribriform plate

T4 Moderately advanced or very advanced local disease

T4a Moderately advanced local disease
Tumor invades any of the following: anterior orbital contents, skin of nose or cheek, minimal extension to anterior cranial fossa, pterygoid plates, sphenoid or frontal sinuses

T4b Very advanced local disease
Tumor invades any of the following: orbital apex, dura, brain, middle cranial fossa, cranial nerves other than (V2), nasopharynx, or clivus

Used with permission of the American College of Surgeons, Chicago, Illinois. The original source for this information is the AJCC Cancer Staging. Manual, Eighth Edition (2017) published by Springer International Publishing. (For complete information and data supporting the staging tables, visit www.springer.com.)

Version 1.2026, 12/08/2025 © 2025 National Comprehensive Cancer Network® (NCCN®), All rights reserved. NCCN Guidelines® and this illustration may not be reproduced in any form without the express written permission of NCCN.

PLEASE NOTE that use of this NCCN Content is governed by the End-User License Agreement, and you MAY NOT distribute this Content or use it with any artificial intelligence model or tool.
Printed by Galya Basol Kochav on 1/4/2026 9:40:35 AM. Copyright © 2026 National Comprehensive Cancer Network, Inc. All Rights Reserved.

Table 6 — Continued
American Joint Committee on Cancer (AJCC)
TNM Staging System for the Nasal Cavity and Paranasal Sinuses (8th ed., 2017)
(Mucosal melanoma of the nasal cavity and paranasal sinuses are not included)

Regional Lymph Nodes (N)		
Clinical N (cN)		
NX		Regional lymph nodes cannot be assessed
N0		No regional lymph node metastasis
N1		Metastasis in a single ipsilateral lymph node, 3 cm or smaller in greatest dimension and ENE(–)
N2		Metastasis in a single ipsilateral lymph node larger than 3 cm but not larger than 6 cm in greatest dimension and ENE(–); *or* metastases in multiple ipsilateral lymph nodes, none larger than 6 cm in greatest dimension and ENE(–); *or* in bilateral or contralateral lymph nodes, none larger than 6 cm in greatest dimension and ENE(–)
	N2a	Metastasis in a single ipsilateral node larger than 3 cm but not larger than 6 cm in greatest dimension and ENE(–)
	N2b	Metastases in multiple ipsilateral nodes, none larger than 6 cm in greatest dimension and ENE(–)
	N2c	Metastases in bilateral or contralateral lymph nodes, none larger than 6 cm in greatest dimension and ENE(–)
N3		Metastasis in a lymph node larger than 6 cm in greatest dimension and ENE(–); *or* metastasis in any node(s) with clinically overt ENE(+)
	N3a	Metastasis in a lymph node larger than 6 cm in greatest dimension and ENE(–)
	N3b	Metastasis in any node(s) with clinically overt ENE (ENE_c)

Note: A designation of “U” or “L” may be used for any N category to indicate metastasis above the lower border of the cricoid (U) or below the lower border of the cricoid (L).
Similarly, clinical and pathological ENE should be recorded as ENE(−) or ENE(+).

Used with permission of the American College of Surgeons, Chicago, Illinois. The original source for this information is the AJCC Cancer Staging Manual, Eighth Edition (2017) published by Springer International Publishing. (For complete information and data supporting the staging tables, visit www.springer.com.)

Version 1.2026, 12/08/2025 © 2025 National Comprehensive Cancer Network® (NCCN®), All rights reserved. NCCN Guidelines® and this illustration may not be reproduced in any form without the express written permission of NCCN.

PLEASE NOTE that use of this NCCN Content is governed by the End-User License Agreement, and you MAY NOT distribute this Content or use it with any artificial intelligence model or tool.
Printed by Galya Basol Kochav on 1/4/2026 9:40:35 AM. Copyright © 2026 National Comprehensive Cancer Network, Inc. All Rights Reserved.

Table 6 — Continued
American Joint Committee on Cancer (AJCC)
TNM Staging System for the Nasal Cavity and Paranasal Sinuses (8th ed., 2017)
(Mucosal melanoma of the nasal cavity and paranasal sinuses are not included)

Regional Lymph Nodes (N)

Pathological N (pN)

NX		Regional lymph nodes cannot be assessed
N0		No regional lymph node metastasis
N1		Metastasis in a single ipsilateral lymph node, 3 cm or smaller in greatest dimension and ENE(–)
N2		Metastasis in a single ipsilateral lymph node, 3 cm or smaller in greatest dimension and ENE(+); *or* larger than 3 cm but not larger than 6 cm in greatest dimension and ENE(–); *or* metastases in multiple ipsilateral lymph nodes, none larger than 6 cm in greatest dimension and ENE(−); *or* in bilateral or contralateral lymph node(s), none larger than 6 cm in greatest dimension and ENE(–);
	N2a	Metastasis in single ipsilateral node 3 cm or less in greatest dimension and ENE(+); or a single ipsilateral node larger than 3 cm but not larger than 6 cm in greatest dimension and ENE(−)
	N2b	Metastases in multiple ipsilateral nodes, none larger than 6 cm in greatest dimension and ENE(–)
	N2c	Metastases in bilateral or contralateral lymph node(s), none larger than 6 cm in greatest dimension and ENE(–)
N3		Metastasis in a lymph node larger than 6 cm in greatest dimension and ENE(−); *or* in a single ipsilateral node larger than 3 cm in greatest dimension and ENE(+); *or* multiple ipsilateral, contralateral or bilateral nodes, any with ENE(+); *or* a single contralateral node of any size and ENE(+)
	N3a	Metastasis in a lymph node larger than 6 cm in greatest dimension and ENE(–)
	N3b	Metastasis in a single ipsilateral node larger than 3 cm in greatest dimension and ENE(+); *or* multiple ipsilateral, contralateral or bilateral nodes, any with ENE(+); *or* a single contralateral node of any size and ENE(+)

Note: A designation of “U” or “L” may be used for any N category to indicate metastasis above the lower border of the cricoid (U) or below the lower border of the cricoid (L).
Similarly, clinical and pathological ENE should be recorded as ENE(−) or ENE(+).

Used with permission of the American College of Surgeons, Chicago, Illinois. The original source for this information is the AJCC Cancer Staging Manual, Eighth Edition (2017) published by Springer International Publishing. (For complete information and data supporting the staging tables, visit www.springer.com.)

Version 1.2026, 12/08/2025 © 2025 National Comprehensive Cancer Network® (NCCN®), All rights reserved. NCCN Guidelines® and this illustration may not be reproduced in any form without the express written permission of NCCN.

PLEASE NOTE that use of this NCCN Content is governed by the End-User License Agreement, and you MAY NOT distribute this Content or use it with any artificial intelligence model or tool.
Printed by Galya Basol Kochav on 1/4/2026 9:40:35 AM. Copyright © 2026 National Comprehensive Cancer Network, Inc. All Rights Reserved.

Table 6 — Continued
American Joint Committee on Cancer (AJCC)
TNM Staging System for the Nasal Cavity and Paranasal Sinuses (8th ed., 2017)
(Mucosal melanoma of the nasal cavity and paranasal sinuses are not included)

Prognostic Stage Groups

Stage 0	Tis	N0	M0
Stage I	T1	N0	M0
Stage II	T2	N0	M0
Stage III	T1	N1	M0
	T2	N1	M0
	T3	N0, N1	M0
Stage IVA	T1	N2	M0
	T2	N2	M0
	T3	N2	M0
	T4a	N0,N1,N2	M0
Stage IVB	Any T	N3	M0
	T4b	Any N	M0
Stage IVC	Any T	Any N	M1

Distant Metastasis (M)

M0 No distant metastasis (no pathologic M0; use clinical M to complete stage group)
M1 Distant metastasis

Histologic Grade (G)

GX Grade cannot be assessed
G1 Well differentiated
G2 Moderately differentiated
G3 Poorly differentiated

Used with permission of the American College of Surgeons, Chicago, Illinois. The original source for this information is the AJCC Cancer Staging Manual, Eighth Edition (2017) published by Springer International Publishing. (For complete information and data supporting the staging tables, visit www.springer.com.)

Version 1.2026, 12/08/2025 © 2025 National Comprehensive Cancer Network® (NCCN®), All rights reserved. NCCN Guidelines® and this illustration may not be reproduced in any form without the express written permission of NCCN.

PLEASE NOTE that use of this NCCN Content is governed by the End-User License Agreement, and you MAY NOT distribute this Content or use it with any artificial intelligence model or tool.
Printed by Galya Basol Kochav on 1/4/2026 9:40:35 AM. Copyright © 2026 National Comprehensive Cancer Network, Inc. All Rights Reserved.

Table 7
American Joint Committee on Cancer (AJCC)
TNM Staging System for Cervical Lymph Nodes and Unknown Primary Tumors of the Head and Neck (8th ed., 2017)
(Squamous cell carcinoma and salivary gland carcinoma of all head and neck sites *except* HPV-related oropharynx cancer, nasopharynx cancer, melanoma, thyroid carcinoma, and sarcoma. Staging of the patient who presents with an occult primary tumor and EBV-unrelated and HPV-unrelated metastatic cervical lymphadenopathy is also included.)

Regional Lymph Nodes (N)

Clinical N (cN): For patients who are treated with primary nonsurgical treatment without a cervical lymph node dissection.

NX		Regional lymph nodes cannot be assessed
N0		No regional lymph node metastasis
N1		Metastasis in a single ipsilateral lymph node, 3 cm or smaller in greatest dimension and ENE(-)
N2		Metastasis in a single ipsilateral lymph node larger than 3 cm but not larger than 6 cm in greatest dimension and ENE(-); *or* metastases in multiple ipsilateral lymph nodes, none larger than 6 cm in greatest dimension and ENE(-); *or* in bilateral or contralateral lymph nodes, none larger than 6 cm in greatest dimension, ENE(-)
	N2a	Metastasis in a single ipsilateral node larger than 3 cm but not larger than 6 cm in greatest dimension and ENE(-)
	N2b	Metastases in multiple ipsilateral nodes, none larger than 6 cm in greatest dimension and ENE(-)
	N2c	Metastases in bilateral or contralateral lymph nodes, none larger than 6 cm in greatest dimension and ENE(-)
N3		Metastasis in a lymph node larger than 6 cm in greatest dimension and ENE(-); *or* metastasis in any node(s) with clinically overt ENE(+) (ENE_c)[2]
	N3a	Metastasis in a lymph node larger than 6 cm in greatest dimension and ENE(−)
	N3b	Metastasis in any node(s) with clinically overt ENE(+) (ENE_c)[2]

[1]Midline nodes are considered ipsilateral nodes.
[2]ENE_c is defined as invasion of skin, infiltration of musculature, dense tethering or fixation to adjacent structures, or cranial nerve, brachial plexus, sympathetic trunk, or phrenic nerve invasion with dysfunction.

Note: A designation of “U” or “L” may be used for any N category to indicate metastasis above the lower border of the cricoid (U) or below the lower border of the cricoid (L). Similarly, clinical and pathological ENE should be recorded as ENE(−) or ENE(+).

Used with permission of the American College of Surgeons, Chicago, Illinois. The original source for this information is the AJCC Cancer Staging Manual, Eighth Edition (2017) published by Springer International Publishing. (For complete information and data supporting the staging tables, visit www.springer.com.)

Version 1.2026, 12/08/2025 © 2025 National Comprehensive Cancer Network® (NCCN®), All rights reserved. NCCN Guidelines® and this illustration may not be reproduced in any form without the express written permission of NCCN.

PLEASE NOTE that use of this NCCN Content is governed by the End-User License Agreement, and you MAY NOT distribute this Content or use it with any artificial intelligence model or tool.
Printed by Galya Basol Kochav on 1/4/2026 9:40:35 AM. Copyright © 2026 National Comprehensive Cancer Network, Inc. All Rights Reserved.

Table 7 — Continued
American Joint Committee on Cancer (AJCC)
TNM Staging System for Cervical Lymph Nodes and Unknown Primary Tumors of the Head and Neck (8th ed., 2017)
(Squamous cell carcinoma and salivary gland carcinoma of all head and neck sites *except* HPV-related oropharynx cancer, nasopharynx cancer, melanoma, thyroid carcinoma, and sarcoma. Staging of the patient who presents with an occult primary tumor and EBV-unrelated and HPV-unrelated metastatic cervical lymphadenopathy is also included.)

Regional Lymph Nodes (N)

Pathological N (pN): For patients who are treated surgically with a cervical lymph node dissection.

NX		Regional lymph nodes cannot be assessed
N0		No regional lymph node metastasis
N1		Metastasis in a single ipsilateral lymph node, 3 cm or smaller in greatest dimension and ENE(-)
N2		Metastasis in a single ipsilateral lymph node, 3 cm or smaller in greatest dimension and ENE(+); *or* larger than 3 cm but not larger than 6 cm in greatest dimension and ENE(-); *or* metastases in multiple ipsilateral lymph node(s), none larger than 6 cm in greatest dimension and ENE(-); *or* in bilateral or contralateral lymph nodes, none larger than 6 cm in greatest dimension and ENE(-)
	N2a	Metastasis in a single ipsilateral node 3 cm or less in greatest dimension and ENE(+); *or* a single ipsilateral node larger than 3 cm but not larger than 6 cm in greatest dimension and ENE(-)
	N2b	Metastases in multiple ipsilateral nodes, none larger than 6 cm in greatest dimension and ENE(-)
	N2c	Metastases in bilateral or contralateral lymph nodes, none larger than 6 cm in greatest dimension and ENE(-)
N3		Metastasis in a lymph node larger than 6 cm in greatest dimension and ENE(-); *or* metastasis in a single ipsilateral node larger than 3 cm in greatest dimension and ENE(+); *or* multiple ipsilateral, contralateral, or bilateral nodes any size and ENE(+) in any node; *or* a single contralateral node of any size and ENE(+)
	N3a	Metastasis in a lymph node larger than 6 cm in greatest dimension and ENE(−)
	N3b	Metastasis in a single ipsilateral node larger than 3 cm in greatest dimension and ENE(+); *or* multiple ipsilateral, contralateral, or bilateral nodes any size and ENE(+) in any node; *or* a single contralateral node of any size and ENE(+)

Anatomic Stage/Prognostic Groups

Stage III	T0	N1	M0
Stage IVA	T0	N2	M0
Stage IVB	T0	N3	M0
Stage IVC	T0	Any N	M1

[1]Midline nodes are considered ipsilateral nodes.
[2]ENE detected on histopathologic examination is designated as ENE_{mi} (microscopic ENE ≤ 2 mm) or ENE_{ma} (major ENE > 2 mm). Both ENE_{mi} and ENE_{ma} qualify as ENE(+) for definition of pN.
Note: A designation of "U" or "L" may be used for any N category to indicate metastasis above the lower border of the cricoid (U) or below the lower border of the cricoid (L). Similarly, clinical and pathological ENE should be recorded as ENE(−) or ENE(+).

Used with permission of the American College of Surgeons, Chicago, Illinois. The original source for this information is the AJCC Cancer Staging Manual, Eighth Edition (2017) published by Springer International Publishing. (For complete information and data supporting the staging tables, visit www.springer.com.)

Version 1.2026, 12/08/2025 © 2025 National Comprehensive Cancer Network® (NCCN®), All rights reserved. NCCN Guidelines® and this illustration may not be reproduced in any form without the express written permission of NCCN.

PLEASE NOTE that use of this NCCN Content is governed by the End-User License Agreement, and you MAY NOT distribute this Content or use it with any artificial intelligence model or tool.
Printed by Galya Basol Kochav on 1/4/2026 9:40:35 AM. Copyright © 2026 National Comprehensive Cancer Network, Inc. All Rights Reserved.

Table 8
American Joint Committee on Cancer (AJCC)
TNM Staging System for the Major Salivary Glands (8th ed., 2017)
(Parotid, submandibular, and sublingual)

Primary Tumor (T)

TX		Primary tumor cannot be assessed
T0		No evidence of primary tumor
Tis		Carcinoma *in situ*
T1		Tumor 2 cm or smaller in greatest dimension without extraparenchymal extension*
T2		Tumor larger than 2 cm but not larger than 4 cm in greatest dimension without extraparenchymal extension*
T3		Tumor larger than 4 cm and/or tumor having extraparenchymal extension*
T4		Moderately advanced or very advanced disease
	T4a	Moderately advanced disease Tumor invades skin, mandible, ear canal, and/or facial nerve
	T4b	Very advanced disease Tumor invades skull base and/or pterygoid plates and/or encases carotid artery

Note: Extraparenchymal extension is clinical or macroscopic evidence of invasion of soft tissues. Microscopic evidence alone does not constitute extraparenchymal extension for classification purposes.

Regional Lymph Nodes (N)

Clinical N (cN)

NX		Regional lymph nodes cannot be assessed
N0		No regional lymph node metastasis
N1		Metastasis in a single ipsilateral lymph node, 3 cm or smaller in greatest dimension and ENE(-)
N2		Metastasis in a single ipsilateral lymph node, larger than 3 cm but not larger than 6 cm in greatest dimension and ENE(-); *or* metastases in multiple ipsilateral lymph node(s), none larger than 6 cm in greatest dimension and ENE(-); *or* in bilateral or contralateral lymph nodes, none larger than 6 cm in greatest dimension and ENE(-)
	N2a	Metastasis in a single ipsilateral node larger than 3 cm but not larger than 6 cm in greatest dimension and ENE(-)
	N2b	Metastases in multiple ipsilateral nodes, none larger than 6 cm in greatest dimension and ENE(-)
	N2c	Metastases in bilateral or contralateral lymph nodes, none larger than 6 cm in greatest dimension and ENE(-)
N3		Metastasis in a lymph node larger than 6 cm in greatest dimension and ENE(-); *or* metastasis in any node(s) with clinically overt ENE(+)
	N3a	Metastasis in a lymph node larger than 6 cm in greatest dimension and ENE(−)
	N3b	Metastases in any node(s) with clinically overt ENE(+)

Note: A designation of “U” or “L” may be used for any N category to indicate metastasis above the lower border of the cricoid (U) or below the lower border of the cricoid (L). Similarly, clinical and pathological ENE should be recorded as ENE(−) or ENE(+).

Used with permission of the American College of Surgeons, Chicago, Illinois. The original source for this information is the AJCC Cancer Staging Manual, Eighth Edition (2017) published by Springer International Publishing. (For complete information and data supporting the staging tables, visit www.springer.com.)

Version 1.2026, 12/08/2025 © 2025 National Comprehensive Cancer Network® (NCCN®), All rights reserved. NCCN Guidelines® and this illustration may not be reproduced in any form without the express written permission of NCCN.

PLEASE NOTE that use of this NCCN Content is governed by the End-User License Agreement, and you MAY NOT distribute this Content or use it with any artificial intelligence model or tool.
Printed by Galya Basol Kochav on 1/4/2026 9:40:35 AM. Copyright © 2026 National Comprehensive Cancer Network, Inc. All Rights Reserved.

Table 8 — Continued
American Joint Committee on Cancer (AJCC)
TNM Staging System for the Major Salivary Glands (8th ed., 2017)
(Parotid, submandibular, and sublingual)

Regional Lymph Nodes (N)

Pathological N (pN)

NX		Regional lymph nodes cannot be assessed
N0		No regional lymph node metastasis
N1		Metastasis in a single ipsilateral lymph node, 3 cm or less smaller in greatest dimension and ENE(-)
N2		Metastasis in a single ipsilateral lymph node, 3 cm or smaller in greatest dimension and ENE(+); *or* larger than 3 cm but not larger than 6 cm in greatest dimension and ENE(−); *or* metastases in multiple ipsilateral lymph node(s), none larger than 6 cm in greatest dimension and ENE(−); *or* in bilateral or contralateral lymph nodes, none larger than 6 cm in greatest dimension and ENE(−)
	N2a	Metastasis in a single ipsilateral lymph node 3 cm or smaller in greatest dimension and ENE(+) *or* a single ipsilateral node larger than 3 cm but not larger than 6 cm in greatest dimension and ENE(-)
	N2b	Metastases in multiple ipsilateral lymph nodes, none larger than 6 cm in greatest dimension and ENE(-)
	N2c	Metastases in bilateral or contralateral lymph node(s), none more than 6 cm in greatest dimension and ENE(-)
N3		Metastasis in a lymph node larger than 6 cm in greatest dimension and ENE(-); *or* in a single ipsilateral node larger than 3 cm in greatest dimension and ENE(+); *or* multiple ipsilateral, contralateral, or bilateral nodes any with ENE(+); *or* a single contralateral node of any size and ENE(+)
	N3a	Metastasis in a lymph node larger than 6 cm in greatest dimension and ENE(−)
	N3b	Metastasis in a single ipsilateral node larger than 3 cm in greatest dimension and ENE(+); *or* multiple ipsilateral, contralateral, or bilateral nodes any with ENE(+); *or* a single contralateral node of any size and ENE(+)

Note: A designation of "U" or "L" may be used for any N category to indicate metastasis above the lower border of the cricoid (U) or below the lower border of the cricoid (L). Similarly, clinical and pathological ENE should be recorded as ENE(−) or ENE(+).

Distant Metastasis (M)

M0	No distant metastasis
M1	Distant metastasis

Anatomic Stage/Prognostic Groups

Stage 0	Tis	N0	M0
Stage I	T1	N0	M0
Stage II	T2	N0	M0
Stage III	T3	N0	M0
	T0,T1,T2,T3	N1	M0
Stage IVA	T0	N2	M0
	T1	N2	M0
	T2	N2	M0
	T3	N2	M0
	T4a	N0,N1,N2	M0
Stage IVB	Any T	N3	M0
	T4b	Any N	M0
Stage IVC	Any T	Any N	M1

Used with permission of the American College of Surgeons, Chicago, Illinois. The original source for this information is the AJCC Cancer Staging Manual, Eighth Edition (2017) published by Springer International Publishing. (For complete information and data supporting the staging tables, visit www.springer.com.)

Version 1.2026, 12/08/2025 © 2025 National Comprehensive Cancer Network® (NCCN®), All rights reserved. NCCN Guidelines® and this illustration may not be reproduced in any form without the express written permission of NCCN.

PLEASE NOTE that use of this NCCN Content is governed by the End-User License Agreement, and you MAY NOT distribute this Content or use it with any artificial intelligence model or tool.
Printed by Galya Basol Kochav on 1/4/2026 9:40:35 AM. Copyright © 2026 National Comprehensive Cancer Network, Inc. All Rights Reserved.

Table 9
American Joint Committee on Cancer (AJCC)
TNM Staging System for Mucosal Melanoma of the Head and Neck (8th ed., 2017)

Primary Tumor (T)

T3 Tumors limited to the mucosa and immediately underlying soft tissue, regardless of thickness or greatest dimension; for example, polypoid nasal disease, pigmented or nonpigmented lesions of the oral cavity, pharynx, or larynx

T4 Moderately advanced or very advanced

T4a Moderately advanced disease
Tumor involving deep soft tissue, cartilage, bone, or overlying skin

T4b Very advanced disease
Tumor involving brain, dura, skull base, lower cranial nerves (IX, X, XI, XII), masticator space, carotid artery, prevertebral space, or mediastinal structures

Regional Lymph Nodes (N)

NX Regional lymph nodes cannot be assessed

N0 No regional lymph node metastases

N1 Regional lymph node metastases present

Distant Metastasis (M)

M0 No distant metastasis

M1 Distant metastasis

Histologic Grade (G)

There is no recommended histologic grading system at this time.

Prognostic Stage Groups

Currently, there is no clear ability to determine prognosis based on histologic differences.

Used with permission of the American College of Surgeons, Chicago, Illinois. The original source for this information is the AJCC Cancer Staging Manual, Eighth Edition (2017) published by Springer International Publishing. (For complete information and data supporting the staging tables, visit www.springer.com.)

Version 1.2026, 12/08/2025 © 2025 National Comprehensive Cancer Network® (NCCN®), All rights reserved. NCCN Guidelines® and this illustration may not be reproduced in any form without the express written permission of NCCN.

PLEASE NOTE that use of this NCCN Content is governed by the End-User License Agreement, and you MAY NOT distribute this Content or use it with any artificial intelligence model or tool.
Printed by Galya Basol Kochav on 1/4/2026 9:40:35 AM. Copyright © 2026 National Comprehensive Cancer Network, Inc. All Rights Reserved.

ABBREVIATIONS

3D-CRT	three-dimensional conformal radiation therapy
ACC	adenoid cystic carcinoma
ACTH	adrenocorticotropic hormone
BED	biologically effective dose
CPS	combined positive score
CR	complete response
dMMR	mismatch repair deficient
EBER	Epstein-Barr virus-encoded RNA
EBNA	Epstein-Barr virus nuclear antigen
EBRT	external beam radiation therapy
EBV	Epstein-Barr virus
EQD2	equivalent dose at 2 Gy
EUA	examination under anesthesia
FDG	fluorodeoxyglucose
FNA	fine-needle aspiration
FSH	follicle-stimulating hormone
GH	growth hormone
H&P	history and physical
HDR	high dose rate
HPV	human papillomavirus
HR	hazard ratio
IGF-1	insulin-like growth factor 1
IGRT	image-guided radiation therapy
IHC	immunohistochemistry
IMRT	intensity-modulated radiation therapy
IORT	intraoperative radiation therapy
ISH	in situ hybridization
LDR	low dose rate
LH	luteinizing hormone
LHRH	luteinizing hormone-releasing hormone
LMP	latent membrane protein
MGPT	multigene panel testing
MMR	mismatch repair
MSI	microsatellite instability
MSI-H	microsatellite instability-high
NaF	sodium fluoride
NG	nasogastric
NGS	next-generation sequencing
NJ	nasojejunal
NOS	not otherwise specified
OAR	organ at risk
OPSCC	oropharyngeal squamous cell carcinoma
PEG	percutaneous endoscopic gastrostomy
PEJ	percutaneous endoscopic jejunostomy
PD-1	programmed cell death protein 1
PD-L1	programmed death ligand 1
PBT	proton beam therapy
PCR	polymerase chain reaction
PFT	pulmonary function test
PR	partial response
PS	performance status
PTV	planning target volume
SBRT	stereotactic body radiation therapy
SCC	squamous cell carcinoma
SEQ	sequential
SIB	simultaneous integrated boost
S-IMRT	sequential intensity-modulated radiation therapy
SLN	sentinel lymph node
SNEC	sinonasal neuroendocrine carcinoma
SNF_2	stannous fluoride
SNUC	sinonasal undifferentiated carcinoma
TMB	tumor mutational burden
TMB-H	tumor mutational burden-high
TMJ	temporomandibular joint
TORS	transoral robotic surgery
TSH	thyroid-stimulating hormone
TTF	thyroid transcription factor
VMAT	volumetric modulated arc therapy

Version 1.2026, 12/08/2025 © 2025 National Comprehensive Cancer Network® (NCCN®), All rights reserved. NCCN Guidelines® and this illustration may not be reproduced in any form without the express written permission of NCCN.

PLEASE NOTE that use of this NCCN Content is governed by the End-User License Agreement, and you MAY NOT distribute this Content or use it with any artificial intelligence model or tool.
Printed by Galya Basol Kochav on 1/4/2026 9:40:35 AM. Copyright © 2026 National Comprehensive Cancer Network, Inc. All Rights Reserved.

NCCN Categories of Evidence and Consensus	
Category 1	Based upon high-level evidence (≥1 randomized phase 3 trials or high-quality, robust meta-analyses), there is uniform NCCN consensus (≥85% support of the Panel) that the intervention is appropriate.
Category 2A	Based upon lower-level evidence, there is uniform NCCN consensus (≥85% support of the Panel) that the intervention is appropriate.
Category 2B	Based upon lower-level evidence, there is NCCN consensus (≥50%, but <85% support of the Panel) that the intervention is appropriate.
Category 3	Based upon any level of evidence, there is major NCCN disagreement that the intervention is appropriate.

All recommendations are category 2A unless otherwise indicated.

NCCN Categories of Preference	
Preferred	Interventions that are based on superior efficacy, safety, and evidence; and, when appropriate, affordability.
Other recommended	Other interventions that may be somewhat less efficacious, more toxic, or based on less mature data; or significantly less affordable for similar outcomes.
Useful in certain circumstances	Other interventions that may be used for selected patient populations (defined with recommendation).

All recommendations are considered appropriate.

Version 1.2026, 12/08/2025 © 2025 National Comprehensive Cancer Network® (NCCN®), All rights reserved. NCCN Guidelines® and this illustration may not be reproduced in any form without the express written permission of NCCN.

PLEASE NOTE that use of this NCCN Content is governed by the End-User License Agreement, and you MAY NOT distribute this Content or use it with any artificial intelligence model or tool.
Printed by Galya Basol Kochav on 1/4/2026 9:40:35 AM. Copyright © 2026 National Comprehensive Cancer Network, Inc. All Rights Reserved.

Discussion

This discussion corresponds to the NCCN Guidelines for Head and Neck Cancers. Last updated: June 20, 2025.

Table of Contents

Overview MS-2
Guidelines Update Methodology MS-2
Literature Search Criteria and Guidelines Update Methodology MS-2
Sensitive/Inclusive Language Usage MS-2
Human Papillomavirus Infection MS-3
Management Approaches MS-3
Comorbidity and Quality of Life MS-6
Imaging of Head and Neck Cancers MS-6
Treatment Principles MS-9
Principles of Supportive Care MS-24
Cancer of the Oral Cavity (Including Mucosal Lip) MS-26
Cancer of the Oropharynx MS-29
Cancer of the Hypopharynx MS-35
Cancer of the Nasopharynx MS-37
Cancer of the Larynx MS-44
Paranasal Tumors (Maxillary and Ethmoid Sinus Tumors) MS-47
Very Advanced Head and Neck Cancers MS-49
Occult Primary Cancer MS-55
Salivary Gland Tumors MS-57
Mucosal Melanoma of the Head and Neck MS-60
Figure 1: Anatomic Sites and Subsites of the Head and Neck MS-62
Figure 2: Level Designation for Cervical Lymphatics in the Right Neck MS-62
References MS-63

Discussion update in progress

Version 1.2026 © 2025 National Comprehensive Cancer Network© (NCCN©), All rights reserved. NCCN Guidelines® and this illustration may not be reproduced in any form without the express written permission of NCCN.

PLEASE NOTE that use of this NCCN Content is governed by the End-User License Agreement, and you MAY NOT distribute this Content or use it with any artificial intelligence model or tool.
Printed by Galya Basol Kochav on 1/4/2026 9:40:35 AM. Copyright © 2026 National Comprehensive Cancer Network, Inc. All Rights Reserved.

Overview

The NCCN Clinical Practice Guidelines in Oncology (NCCN Guidelines®) for Head and Neck Cancers address tumors arising from the oral cavity (including mucosal lip), pharynx, larynx, and paranasal sinuses. Occult primary cancers, salivary gland cancers, and mucosal melanoma (MM) are also addressed. In 2025, it is estimated that about 72,680 new cases of oral cavity, pharyngeal, and laryngeal cancers will occur, which account for approximately 3.6% of new cancer cases in the United States.[1] An estimated 16,680 deaths from head and neck (H&N) cancers will occur during the same time period.[1] Squamous cell carcinomas account for >90% of these tumors. Tobacco and alcohol use disorders are the most common etiologies for oral cavity, hypopharynx, larynx, and human papillomavirus (HPV)-unrelated (p16 negative) oropharynx cancers. Patients whose H&N cancers due to tobacco and alcohol are at risk for harboring synchronous primary tumors and/or developing second primary neoplasms of the H&N, lung, esophagus, bladder, and other potential sites that are exposed to these carcinogens.

Stage at diagnosis predicts survival rates and guides care of patients with H&N cancers. In general, stage I or II disease defines a relatively small primary tumor without regional nodal involvement amongst HPV-unrelated cancers. Stage III or IVa/b HPV-unrelated cancers and stages I, II, and III HPV-related (p16 positive) cancers may include larger primary tumors, which may invade underlying structures and/or spread to regional nodes. Distant metastases (Stage IVc HPV-unrelated cancers or Stage IV HPV-related cancers are less common at presentation as compared to lung and esophagus cancers. More advanced TNM (tumor, node, metastasis) stages are associated with worse survival.

Guidelines Update Methodology

The complete details of the Development and Update of the NCCN Guidelines are available at www.NCCN.org.

Literature Search Criteria and Guidelines Update Methodology

Prior to the update of the NCCN Guidelines® for Head and Neck Cancers, an electronic search of the PubMed database was performed to obtain key literature in H&N cancers published since the previous Guidelines update, using the following search terms: (head and neck cancer) OR (head and neck squamous cell carcinoma) OR (lip cancer) OR (oral cavity cancer) OR (oropharynx cancer) OR (hypopharynx cancer) OR (nasopharynx cancer) OR (larynx cancer) OR (paranasal tumor) OR (ethmoid sinus tumor) OR (maxillary sinus tumor) OR (salivary gland tumor) OR (mucosal melanoma head) OR (mucosal melanoma neck) OR (recurrent metastatic head neck cancer). The PubMed database was chosen because it remains the most widely used resource for medical literature and indexes peer-reviewed biomedical literature.

The search results were narrowed by selecting studies in humans published in English. Results were confined to the following article types: Clinical Trial, Phase II; Clinical Trial, Phase III; Clinical Trial, Phase IV; Guideline; Practice Guideline; Randomized Controlled Trial; Meta-Analysis; Systematic Reviews; and Validation Studies. The data from key PubMed articles as well as articles from additional sources deemed as relevant to these guidelines as discussed by the Panel during the Guidelines update have been included in this version of the Discussion section. Recommendations for which high-level evidence is lacking are based on the Panel's review of lower-level evidence and expert opinion.

Sensitive/Inclusive Language Usage

NCCN Guidelines strive to use language that advances the goals of equity, inclusion, and representation. NCCN Guidelines endeavor to use language that is person-first; not stigmatizing; anti-racist, anti-classist, anti-misogynist, anti-ageist, anti-ableist, and anti-weight-biased; and inclusive of individuals of all sexual orientations and gender identities. NCCN

Discussion update in progress

Version 1.2026 © 2025 National Comprehensive Cancer Network© (NCCN©), All rights reserved. NCCN Guidelines® and this illustration may not be reproduced in any form without the express written permission of NCCN.

PLEASE NOTE that use of this NCCN Content is governed by the End-User License Agreement, and you MAY NOT distribute this Content or use it with any artificial intelligence model or tool.
Printed by Galya Basol Kochav on 1/4/2026 9:40:35 AM. Copyright © 2026 National Comprehensive Cancer Network, Inc. All Rights Reserved.

Guidelines incorporate non-gendered language, instead focusing on organ-specific recommendations. This language is both more accurate and more inclusive and can help fully address the needs of individuals of all sexual orientations and gender identities. NCCN Guidelines will continue to use the terms *men*, *women*, *female*, and *male* when citing statistics, recommendations, or data from organizations or sources that do not use inclusive terms. Most studies do not report how sex and gender data are collected and use these terms interchangeably or inconsistently. If sources do not differentiate gender from sex assigned at birth or organs present, the information is presumed to predominantly represent cisgender individuals. NCCN encourages researchers to collect more specific data in future studies and organizations to use more inclusive and accurate language in their future analyses.

Human Papillomavirus Infection

HPV infection is a predominant cause of squamous cell carcinomas of the oropharynx (particularly cancers of the tonsils and tongue base).[2-9] However, small subsets of squamous cell carcinomas of the oral cavity, larynx, nasopharynx, and paranasal sinuses are HPV positive,[10] and 50% of patients with squamous cell carcinoma of unknown primary in the H&N are HPV positive.[11] The overall incidence of HPV-positive oropharynx cancers is increasing in the United States, particularly in men,[12] while the incidence of HPV-negative (primarily tobacco- and alcohol-related) cancer is decreasing.[13] The attributable fraction for HPV in newly diagnosed oropharyngeal cancer is estimated as 60% to 70% in the United States and parts of the European Union.[13-17] Patients with HPV-positive cancer have tended to be younger[9,18]; however, HPV-positive oropharynx cancer rates are rising among older adults as the exposed cohorts age.[19,20] Oral HPV16 infection increases the risk of oropharynx cancer,[2,8,21,22] and a strong causal relationship has been established.[2,21] HPV16 accounts for ~90% of cases, and HPV18, 33, and 35 are responsible for the vast majority of the small remaining fraction.[9] The prevalence of HPV16 is higher in oropharyngeal cancer than in cervical cancer (~50%), in which HPV18 is also highly prevalent.[14,23-25] Expression of the HPV E6 and E7 oncogenes inactivates the tumor suppressor proteins p53 and pRb, respectively, which are frequently mutated in tobacco-related mucosal squamous cell carcinomas. Inactivation of p53 and pRb promotes genomic instability and the development of cancer and is responsible for the upregulation of p16 protein expression, a reliable surrogate marker of the presence of HPV DNA in these tumors. Genetic profiling of HPV-positive cancer has demonstrated it to be genetically distinct from HPV-negative squamous cell carcinoma of the head and neck (SCCHN).[26]

Analyses from the National Health and Nutrition Examination Survey (2011–2014), including 2627 adults aged 18 to 33 years, showed that HPV vaccination was associated with reduced vaccine-type oral HPV infection (0.1% in vaccinated individuals vs. 1.6% in unvaccinated individuals; P = .008).[27] Moreover, HPV vaccination in the United States has led to herd protection against oral HPV16, 18, 6, and 11 infections in unvaccinated males.[28] Results of an ongoing randomized clinical trial to investigate the efficacy of HPV vaccines for the prevention of oral HPV infections have not yet been reported. While data are not yet available, the HPV types that cause the overwhelming majority of SCCHN are included in the HPV nonavalent vaccine (provides protection against nine high-risk HPV types). Since there is evidence that vaccination prevents HPV-related cervical and anal cancers,[29-31] the U.S. Food and Drug Administration (FDA) expanded the indication for HPV vaccination to include prevention of oral HPV infections and related oropharyngeal cancers in 2020.

Patients with locally advanced HPV-positive SCCHN have improved response to treatment and survival (overall survival [OS] and progression-free survival [PFS]) when compared with HPV-negative tumors.[11,32-37] Treatment response is improved in patients receiving radiation therapy (RT) or chemoradiation.[32,38,39]

Discussion update in progress

Version 1.2026 © 2025 National Comprehensive Cancer Network© (NCCN©), All rights reserved. NCCN Guidelines® and this illustration may not be reproduced in any form without the express written permission of NCCN.

PLEASE NOTE that use of this NCCN Content is governed by the End-User License Agreement, and you MAY NOT distribute this Content or use it with any artificial intelligence model or tool.
Printed by Galya Basol Kochav on 1/4/2026 9:40:35 AM. Copyright © 2026 National Comprehensive Cancer Network, Inc. All Rights Reserved.

Distinguishing patients with p16 positivity by HPV tumor status informs prognosis. A multicenter individual patient data analysis including 13 cohorts of patients from Canada and Europe (N = 7654) showed that patients with discordant p16 expression and HPV status (5-year OS of 53.2%; 95% CI, 46.6%–60.8% for p16-negative/HPV-positive; 5-year OS of 54.7%; 95% CI, 49.2%–60.9% for p16-positive/HPV-negative) had worse prognosis compared to patients with concordant positive p16 expression and HPV status (5-year OS of 81.1%; 95% CI, 79.5%–82.7% for p16-negative/HPV-positive).[40] Prognosis was worst for patients with concordant negative p16 expression and HPV status (5-year OS of 40.4%; 95% CI, 38.6%–42.4% for p16-negative/HPV-positive).[41,42] A retrospective cohort analysis (N = 1070) also showed better OS in patients with HPV 16/18 positive sinonasal cancer, compared to patients with HPV negative disease (adjusted hazard ratio [HR], 0.63; 95% CI, 0.48–0.82).[43]

The impact of smoking and cancer stage on survival of patients with HPV-positive SCCHN has been investigated in numerous studies.[44-46] For example, analyses of patients with oropharyngeal cancer who were enrolled in RTOG 9003 or 0129 (*n* = 165) showed that smoking was associated with decreased OS and PFS, regardless of p16 status.[44] An analysis of data compiled from four cooperative group trials estimated that those who never smoked had a 51% (HR, 0.40; 95% CI, 0.33–0.75) reduction in risk of cancer progression when compared to those who formerly or currently smoked and had HPV-positive SCCHN.[46] A retrospective analysis from a clinical trial (RTOG 0129) showed no difference in the rate of distant metastasis in patients with p16-positive versus p16-negative disease.[32] Additional analyses have suggested that individuals with T4 or N3 disease or radiographically detectable matted lymph nodes may have a worse prognosis, and therefore should be excluded from deintensification trials.[47-50] These studies on prognostic and predictive factors in HPV-positive oropharyngeal cancers form the basis for RT deintensification studies. Moreover, the striking difference in prognosis for HPV-positive versus HPV-negative SCCHN led to the creation of new AJCC staging criteria in 2018 (see *Cancer of the Oropharynx* in the NCCN Guidelines for Head and Neck Cancers; available at www.NCCN.org).

Management Approaches

The specific site of disease, histology, stage, and baseline comorbid conditions guide treatment decisions (eg, the appropriate surgical procedures, radiotherapy treatment parameters [target volumes, total dose, and fractionation regimen], indications for systemic therapy, patient-specific considerations). Single-modality treatment with surgery or RT is generally recommended for the approximately 30% to 40% of patients who present with early-stage disease (stage I or II) HPV-unrelated cancers. Surgery and RT result in similar survival for many H&N cancers, but surgery is usually preferred for oral cavity and paranasal sinus cancers, while RT with or without chemotherapy is nearly always preferred for all stages of nasopharyngeal carcinoma (NPC) and more advanced stages of HPV-associated oropharyngeal cancer. The choice of surgery or RT as the primary treatment modality is often based on local institutional expertise and/or perceived relative morbidity of these treatment options. With the evolution of conformal techniques of RT and less invasive surgery, as well as improving supportive care for patients receiving systemic therapy, morbidity is also a moving target. Combined modality therapy (eg, surgery and radiation or chemoradiation) is generally recommended for the approximately 60% of patients with locally or regionally advanced disease at diagnosis.

Participation in clinical trials is a preferred or recommended treatment option in many situations. In formulating these NCCN Guidelines, Panel members have tried to create them with evidence-based practices while providing a statement of consensus as to the acceptable range of treatment options. In numerous population-based studies, patients treated

Discussion update in progress

Version 1.2026 © 2025 National Comprehensive Cancer Network© (NCCN©), All rights reserved. NCCN Guidelines® and this illustration may not be reproduced in any form without the express written permission of NCCN.

PLEASE NOTE that use of this NCCN Content is governed by the End-User License Agreement, and you MAY NOT distribute this Content or use it with any artificial intelligence model or tool.
Printed by Galya Basol Kochav on 1/4/2026 9:40:35 AM. Copyright © 2026 National Comprehensive Cancer Network, Inc. All Rights Reserved.

at high-volume centers appear to have better outcomes relative to patients treated at low-volume centers.[51-56]

Multidisciplinary Team Involvement

The initial evaluation and treatment planning for patients with H&N cancers requires a multidisciplinary team of health care providers with expertise in caring for such patients.[57,58] Similarly, managing and preventing sequelae following surgery, RT, and systemic therapy (eg, trismus, pain, lymphedema and muscle spasm of the neck, xerostomia, dysphagia, speech and swallowing problems, dental and jaw decay, depression, peripheral neuropathy, hearing loss, renal failure) requires professionals familiar with these diseases.[59,60] Follow-up for such sequelae should include a comprehensive H&N examination, supportive care, and rehabilitation (see *Follow-Up Recommendations* in the NCCN Guidelines for Head and Neck Cancers).[57] Adequate nutritional support can help to prevent severe weight loss in patients receiving treatment for H&N cancers and shorten post-treatment recovery times; therefore, patients should be referred to a registered dietitian at diagnosis, during, and after treatment, as needed (see *Principles of Nutrition: Management and Supportive Care* in the NCCN Guidelines for Head and Neck Cancers).[61] Dental care to prevent and treat radiation-related effects must be provided (see *Principles of Oral/Dental Evaluation and Management* in the NCCN Guidelines for Head and Neck Cancers). Evaluation by a speech-language/swallowing therapist before and after treatment is also strongly recommended. Evaluation and management of lymphedema and trismus should be conducted as clinically indicated with appropriate referrals to occupational and physical therapy. Patients are at risk for depression from H&N cancer and its sequelae, thus screening and treatment for depression is advised (see the NCCN Guidelines for Distress Management, available at www.NCCN.org).[62-65] Fertility/reproductive counseling should be offered to patients who have these concerns [see the NCCN Guidelines for Adolescent and Young Adult (AYA) Oncology, available at www.NCCN.org]. Specific components of patient support and follow-up are listed in the algorithm (see *Team Approach* in the NCCN Guidelines for Head and Neck Cancers). Panel members also recommend referring to the NCCN Guidelines for Palliative Care and NCCN Guidelines for Adult Cancer Pain as needed (available at www.NCCN.org). Patients should be kept well-informed of the risks, benefits, and potential outcomes of treatment options and should be fully involved in their shared decision-making process.

Cigarette smoking is associated with at least 30% of cancer deaths,[66] and, therefore, patients' history of tobacco use must be assessed. Patients should be encouraged to stop smoking (and remain abstinent in particular during treatment with RT) and to modify excessive alcohol consumption. These habits cannot only decrease the efficacy of treatment, but adversely affect other health outcomes.[67-69] Information on smoking cessation resources and support can be found in the NCCN Guidelines for Smoking Cessation (available at www.NCCN.org). Alcohol use is also associated causally with H&N cancer.[70,71] Therefore, alcohol use should be documented during history and physical (H&P) and counseling administered as indicated.

Universal screening for hepatitis B for patients undergoing cancer therapy is recommended.[72] All patients with cancer anticipating systemic therapy treatment should be screened for hepatitis B through three tests. People living with chronic hepatitis B (HBV) receiving any systemic therapy for cancer treatment should receive antiviral prophylaxis for the duration of treatment, as well as for at least 12 months after receipt of the last systemic therapy treatment. While screening is important for all patients, it is particularly important for patients who are disproportionately affected by hepatitis B, including persons of Asian, Pacific Islander, and African descent.

Discussion update in progress

Version 1.2026 © 2025 National Comprehensive Cancer Network© (NCCN©), All rights reserved. NCCN Guidelines® and this illustration may not be reproduced in any form without the express written permission of NCCN.

PLEASE NOTE that use of this NCCN Content is governed by the End-User License Agreement, and you MAY NOT distribute this Content or use it with any artificial intelligence model or tool.
Printed by Galya Basol Kochav on 1/4/2026 9:40:35 AM. Copyright © 2026 National Comprehensive Cancer Network, Inc. All Rights Reserved.

Resectable Versus Unresectable Disease

The NCCN Member Institutions have teams experienced in the comprehensive treatment of H&N cancers and maintain the multidisciplinary infrastructure needed for reconstruction and rehabilitation. A patient's cancer is deemed unresectable if H&N surgeons at NCCN Member Institutions do not think they can remove the gross tumor on anatomic grounds or if local control is unlikely to be achieved with surgery (even with the addition of RT to the treatment approach). Typically, these unresectable tumors densely involve the prevertebral fascia, cervical vertebrae, skull base, brachial plexus, deep muscles of the neck, mediastinal structures, or critical H&N vasculature (see *Principles of Surgery* in the NCCN Guidelines for Head and Neck Cancers). Unresectable tumors are associated with overall poor prognosis.

Unresectable tumors should be distinguished from inoperable tumors in those patients whose constitutional state of health precludes an operation (even if the cancer could be readily resected with few sequelae). Additionally, a subgroup of patients will decline surgical management, but their tumors should not be deemed unresectable. In some patients, adequate reconstructive options may be lacking; therefore, the patient's disease is considered functionally unresectable. Examples include bilateral orbital exenteration or exenteration in the only seeing eye, extensive mandibular resection without reconstruction options, or total pharyngectomy when reconstitution of the alimentary tract is not feasible. Although these are rare occurrences, the impact on quality of life (QOL) and the need for continual supportive care are significant and open-ended. Although local and regional disease may be surgically treatable, patients with distant metastases may not benefit from surgery, and therefore their disease is deemed inoperable. In incurable situations, surgery may still be considered for symptom palliation in select cases. Thus, patient choice or a physician's expectations regarding cure and morbidity will influence or determine treatment. Patients with locally advanced but resectable tumors, who can also be adequately treated without surgery, represent a very important group that is distinct from patients with unresectable disease. Definitive treatment with RT alone or RT combined with systemic therapy may represent equivalent or preferable approaches to surgery in these individuals. Although such patients may not undergo surgery, their tumors should not be labeled as unresectable. Their disease is usually far less extensive than those with disease that truly cannot be removed.

Comorbidity and Quality of Life

Comorbidity

Comorbidity refers to the presence of concomitant disease(s) (in addition to H&N cancers) that may affect diagnosis, treatment, and prognosis. Documentation of comorbidity is important to facilitate optimal treatment selection. Comorbidity is known to be a strong independent predictor for mortality in patients with H&N cancers,[73,74] and it also influences QOL and health care costs and utilization.[75-77] The Adult Comorbidity Evaluation-27 (ACE-27) is a validated instrument for assessing comorbidity in numerous cancer types including H&N cancers.[78] An important consideration when interpreting published clinical trial data is the applicability of the results to patients with significant comorbidities, who may have been ineligible/excluded from such studies.

Quality of Life

Health-related QOL issues are important in patients with H&N cancers. These tumors affect the patient's basic physiologic functions (ie, the ability to chew, swallow, breathe), the senses (ie, taste, smell, hearing), and uniquely human characteristics (ie, appearance, voice). *Health status* describes an individual's physical, emotional, and social capabilities and limitations. *Function* and *performance* refer to how well an individual is able to perform important roles, tasks, or activities. *QOL* differs because the central focus is on the *value* (determined by the patient alone) that individuals place on their health status and function.

Discussion update in progress

Version 1.2026 © 2025 National Comprehensive Cancer Network© (NCCN©), All rights reserved. NCCN Guidelines® and this illustration may not be reproduced in any form without the express written permission of NCCN.

PLEASE NOTE that use of this NCCN Content is governed by the End-User License Agreement, and you MAY NOT distribute this Content or use it with any artificial intelligence model or tool.
Printed by Galya Basol Kochav on 1/4/2026 9:40:35 AM. Copyright © 2026 National Comprehensive Cancer Network, Inc. All Rights Reserved.

Patient-completed scales should be used to measure QOL.[79] Three validated and accepted measures for H&N cancer-specific issues are: 1) the University of Washington Quality of Life Questionnaire (UW-QOL)[80]; 2) the European Organization for Research and Treatment of Cancer Quality of Life Questionnaire Head and Neck Module (EORTC-QLQ-H&N35)[81]; and 3) the Functional Assessment of Cancer Therapy Head and Neck (FACT-H&N) scale.[82] The Performance Status Scale is a clinician-rated performance scale that is widely used for patients with H&N cancers.[83] The Oral Mucositis Weekly Questionnaire HN (OMWQ-HN) is a validated patient-reported instrument that measures the symptoms of oral mucositis, including mouth and throat pain, and its impact on well-being and function.[84] Use of the Patient-Reported Outcomes version of the Common Terminology Criteria for Adverse events, which was developed to facilitate evaluation of symptomatic toxicity in patients enrolled in cancer clinical trials, is encouraged (https://healthcaredelivery.cancer.gov/pro-ctcae/).

Imaging of Head and Neck Cancers

Appropriate selection and utilization of imaging studies is crucial for proper care of patients with H&N cancers. Initial imaging of the primary site is performed with CT and/or MRI. MRI is generally preferred over CT in patients with symptoms that involve the cranial nerves or tumors that encroach on the skull base. CT, however, is complementary to MRI for evaluation of bony erosion or cartilage invasion that may occur with some H&N tumors (eg, laryngeal cancer). In patients with H&N cancers that involve the bone, MRI is needed to evaluate the extent of bone marrow invasion, while CT is preferred to evaluate cortical bone erosion or periosteal invasion. For cancers originating in the base of the tongue, MRI can often delineate the boundary between gross tumor and normal muscle more effectively than CT. MRI is also preferable to CT for differentiating tumor extent from obstructed sinuses or secretions and to evaluate intracranial/dural involvement. Evaluation of lymph node metastases can be done with either CT or MRI, depending on the primary site, although both have lower accuracy as compared with FDG-PET/CT.[85] Ultimately, choosing CT or MRI should be driven by the information desired as both are not routinely indicated.

There is evidence to support the superiority of FDG-PET/CT for detecting locoregional nodal and distant metastases in patients with H&N cancers. A meta-analysis including 18 studies showed that the positive predictive value (PPV) and negative predictive value (NPV) of FDG-PET/CT for detection of cervical lymph node involvement in patients with clinically node-negative SCCHN was 0.62 (95% CI, 0.55–0.69) and 0.83 (95% CI, 0.79–0.86), respectively.[85] Analyses from the prospective ACRIN 6685 study (SCCHN; 64% oral cavity) showed that, in patients with cN0 disease, 125/144 (87%) negative PET scans were pathologically negative at neck dissection.[86] Findings from PET/CT changed the surgical plan in 22% of patients. A prospective single-center study from Germany (N = 150) showed an NPV of 93.3% (95% CI, 88.2%–98.5%) for detection of cervical lymph node metastases by FDG-PET/CT.[87] If there is concern about metastasis to a specific anatomic area, then directed CT or MRI may also be performed (eg, contrast-enhanced chest CT to evaluate pulmonary metastases and/or mediastinal lymph node involvement; contrast-enhanced brain MRI for evaluation of brain metastases or skull base invasion). H&N cancers rarely metastasize to the brain by a hematogenous route. Therefore, ordering a full brain study as part of the initial imaging workup is not routine.

For patients who are dentulous and expected to receive postoperative RT, a panoramic dental x-ray should be completed before treatment as part of the dental evaluation (see *Principles of Oral/Dental Evaluation and Management* in the NCCN Guidelines for Head and Neck Cancers). Panorex is also helpful for evaluation of dentition and mandibular height if a marginal resection is being considered.

Discussion update in progress

Version 1.2026 © 2025 National Comprehensive Cancer Network© (NCCN©), All rights reserved. NCCN Guidelines® and this illustration may not be reproduced in any form without the express written permission of NCCN.

PLEASE NOTE that use of this NCCN Content is governed by the End-User License Agreement, and you MAY NOT distribute this Content or use it with any artificial intelligence model or tool.
Printed by Galya Basol Kochav on 1/4/2026 9:40:35 AM. Copyright © 2026 National Comprehensive Cancer Network, Inc. All Rights Reserved.

Short-Term Evaluation of Locoregionally Advanced Disease

Imaging is often part of response assessment following definitive therapy. Careful consideration should be given as to the type of imaging performed. It is unlikely all three modalities (CT, MRI, and FDG-PET/CT) will be needed, and this may add cost and inconvenience without significant added value.

Patients treated with induction chemotherapy may receive imaging with CT or MRI after two or three cycles of chemotherapy. If there is high concern for distant metastasis, a chest CT or FDG-PET/CT may be needed to evaluate whether to proceed to the planned definitive local therapy.

For patients with locoregionally advanced disease who have undergone surgery, postoperative imaging is recommended if there are signs of early recurrence or for patients considered high risk of early recurrence. This may be needed to evaluate whether to proceed with the planned adjuvant radiation-based therapy and/or to determine targets and dosing of radiation in case of unexpected recurrence. Patients with positive margins, advanced T or N stage, or oral cavity cancers are at particular risk for rapid recurrence after surgery.[88]

After definitive-intent treatment completion, the Panel generally recommends imaging 3 to 4 months after the end of treatment, or as early as 4 to 8 weeks after definitive treatment if there is concern about an incomplete treatment response. Of note, proximity to recent treatment can complicate interpretation of radiographic studies, and communication with the interpreting radiologist/nuclear medicine physicians is important to distinguish recurrent disease from post-treatment effect. Positive PET results can be particularly difficult to interpret earlier than 12 weeks following treatment, as shown in multiple prospective and retrospective studies.[89-91]

Careful and regular follow-up examinations are recommended so that any local or regional recurrence is detected early. After RT-based treatment, evaluation with imaging (ie, CT and/or MRI with contrast or FDG-PET/CT) guides the use of neck dissection (see *Follow-Up Recommendations: Post Systemic Therapy/RT or RT Neck Evaluation* in the NCCN Guidelines for Head and Neck Cancers).[92-96] A meta-analysis of 27 studies showed that the PPV and NPV for PET or PET/CT to detect local residual or recurrent disease were 52.7% and 96.3%, respectively, and 72.3% and 88.3%, respectively, for detection of nodal residual or recurrent disease.[91] If PET/CT is used for follow-up, the first scan should be performed at a minimum of 12 weeks after treatment to reduce the false-positive rate.[89-91] PET/CT surveillance in patients with advanced nodal disease who received systemic therapy/RT yielded a comparable survival rate and QOL and may be more cost-effective, relative to planned neck dissection.[97,98] A 2023 Cochrane review compared the risks and benefits of surgical, or other treatment modalities, for tumors of the oral cavity or oropharynx among 15 studies.[99] One trial found no difference (moderate certainty) in OS or locoregional recurrence when comparing individuals (n = 564) who received a PET/CT post-chemoradiation (with neck dissection only if no or incomplete response) to those who underwent planned neck dissection (prior to or after chemoradiation). Care should be taken regarding the timing and interpretation of PET studies, as false-positive results may occur due to recent infection or treatment-related inflammation.

Note that a *complete clinical response* (ie, clinically negative) may be defined as no visible or palpable evidence of residual disease and no concerning findings on CT or MRI[92,100]; a complete pathologic response requires pathologic confirmation. If a complete clinical response to RT-based treatment has been achieved, then the Panel recommends observing the patient.[92,100,101] In patients who have a clinically negative neck, PET/CT is associated with NPVs ranging from 97% to 100%.[102-104] Panel members also concur that any patient with residual disease after

Discussion update in progress

Version 1.2026 © 2025 National Comprehensive Cancer Network© (NCCN©), All rights reserved. NCCN Guidelines® and this illustration may not be reproduced in any form without the express written permission of NCCN.

PLEASE NOTE that use of this NCCN Content is governed by the End-User License Agreement, and you MAY NOT distribute this Content or use it with any artificial intelligence model or tool.
Printed by Galya Basol Kochav on 1/4/2026 9:40:35 AM. Copyright © 2026 National Comprehensive Cancer Network, Inc. All Rights Reserved.

RT-based treatment should be considered for surgical resection for refractory disease, including a neck dissection if indicated.[92] If the residual, persistent, or progressing disease is unresectable, then these patients should receive systemic therapy and/or RT as described for recurrent or persistent disease in the NCCN Guidelines for Head and Neck Cancers. For patients with equivocal PET/CT scan results in the neck, a prospective study suggests that a repeat PET/CT scan 4 to 6 weeks later may help identify those patients who can be safely observed without surgery to the neck.[105] These patients may also continue to be observed if the clinical examination is reassuring.

Long-Term Evaluation of Recurrent Disease

Recurrences in patients with H&N cancer tend to occur in the first 3 years following treatment, with more occurring earlier rather than later in this interval. There is little evidence to support imaging surveillance in the long-term (ie, >6 months following treatment) in patients who have negative imaging results,[90,106] although delayed or late recurrences are more common in patients with HPV-related H&N cancer.[107] Imaging should be prompted by new symptoms or physical examination findings. A meta-analysis including seven studies with 577 scans showed that FDG-PET/CT showed high sensitivity (92%) and specificity (91%) values for detection of H&N cancer recurrence 12 months after treatment.[108] However, a retrospective study including 1114 patients with H&N cancer showed that PET/CT scans conducted at 12 and 24 months after treatment completion become less equivocal with time.[106] Further, among patients with negative 3-month scans, there were no significant differences in subsequent survival outcomes in patients whose recurrences were detected through PET/CT versus those with clinically detected recurrences.

H&N cancer treatment can result in fibrosis and altered anatomy, which frequently leads to challenges in physical examination that may be assisted by follow-up imaging. Ultimately, the plan for long-term surveillance should consider tumor site, stage, prognostic factors, presence of symptoms, and changes based on clinical examination. Neck ultrasound (US), which is widely available, inexpensive, safe, and accurate, may be used to evaluate suspected nodal disease. For areas difficult to visualize by clinical examination (ie, due to anatomy or areas obscured by treatment change), routine annual imaging using the pretreatment imaging modality (usually CT or MRI) may be indicated. The impact of annual screening for lung metastasis or synchronous lung cancer in patients with a heavy smoking history is an area in need of investigation. Annual low-resolution chest CT should be considered for these patients. Many clinicians obtain a chest x-ray for lung screening, but this is not supported by strong evidence due to limited sensitivity[109,110] (see NCCN Guidelines for Lung Cancer Screening, available at www.NCCN.org). H&N RT treatment is associated with development of carotid artery stenosis,[111,112] and RT dose to the carotid artery is associated with increased stroke risk.[113] The Society for Vascular Surgery recommends initial carotid imaging surveillance within 2 years following the completion of radiation therapy, followed by screening every 3 years.[114] This recommendation acknowledges the high risk of atherosclerotic disease in patients who have undergone neck irradiation, thus justifying screening in asymptomatic patients.[115]

Treatment Principles

Head and Neck Surgery

All patients should be evaluated by an H&N surgical oncologist before any treatment is administered. In addition, it is critical that multidisciplinary evaluation and treatment be well coordinated. Minimally invasive surgery may be useful for decreasing morbidity.[116,117] For H&N cancer surgery, transoral resection using robotic, endoscopic, or direct access surgery may offer advantages over conventional methods.[118-120] Use of robotic surgery is increasing in the United States. Postoperative hemorrhage is

Discussion update in progress

Version 1.2026 © 2025 National Comprehensive Cancer Network© (NCCN©), All rights reserved. NCCN Guidelines® and this illustration may not be reproduced in any form without the express written permission of NCCN.

PLEASE NOTE that use of this NCCN Content is governed by the End-User License Agreement, and you MAY NOT distribute this Content or use it with any artificial intelligence model or tool.
Printed by Galya Basol Kochav on 1/4/2026 9:40:35 AM. Copyright © 2026 National Comprehensive Cancer Network, Inc. All Rights Reserved.

reported in 13% to 16% of patients who are treated with transoral robotic surgery (TORS).[121,122] The risk of this complication can be reduced through use of appropriate surgical strategies (eg, transcervical arterial ligation). TORS is associated with favorable QOL and swallowing outcomes, although outcome may vary depending on baseline function, T stage, and adjuvant treatment.[123,124] Evaluation, integration of therapy, assessment of resectability, principles for primary tumor resection, margins, surgical management of the neck and cranial nerves (VII, X–XII), management of recurrences, and principles for surveillance (including post-treatment neck evaluation) are discussed in the algorithm (see *Principles of Surgery* in the NCCN Guidelines for Head and Neck Cancers).[125,126]

Neck Dissection

Historically, cervical lymph node (ie, neck) dissections have been classified as *radical* or *modified radical* procedures. The less radical procedures preserved the sternocleidomastoid muscle, jugular vein, spinal accessory nerve, or selective lymph node levels. The NCCN Panel prefers to classify cervical lymphadenectomy using contemporary nomenclature; thus, cervical lymph node dissections are classified as either *comprehensive* or *selective.*[127] A *comprehensive* neck dissection removes all lymph node groups that would be included in a classic radical neck dissection. Whether the sternocleidomastoid muscle, jugular vein, or spinal accessory nerve is preserved does not affect whether the dissection is classified as comprehensive.

Selective neck dissections have been developed based on the common pathways for spread of H&N cancers to regional nodes (see Figure 2).[128,129] Depending on the site, selective neck dissection is often recommended for N0 disease (see the algorithm for specific sites and *Neck Management* in *Principles of Surgery* in the NCCN Guidelines for Head and Neck Cancers). To remove the nodes most commonly involved with metastases from the oral cavity, a selective neck dissection is recommended, which includes the nodes found above the omohyoid muscle (levels I–III and sometimes the superior parts of level IV).[127,130] Similarly, to remove the nodes most commonly involved with metastases from the pharynx and larynx, a selective neck dissection is recommended, which includes the nodes in levels II to IV and level V when appropriate.[127] SCCHN with no clinical nodal involvement rarely presents with nodal metastasis beyond the confines of an appropriate selective neck dissection (<10% of the time).[131-133]

The chief role of selective neck dissections in these NCCN Guidelines is to determine which patients are candidates for possible adjuvant therapy (ie, systemic therapy/RT or RT), although selective neck dissections may be used as treatment when neck tumor burden is low.[134] In general, patients undergoing selective neck dissection should not have clinical nodal disease; however, selective neck dissection may prevent morbidity as opposed to comprehensive neck dissection in patients with low-volume nodal disease, specifically in certain patients with N1–N2 disease.[135-137] In patients with pathologically positive lymph nodes, radiation with or without chemotherapy should be considered and a decision should be made following multidisciplinary evaluation. In the NCCN Guidelines, patients with cervical node metastasis who undergo operations with therapeutic intent are generally treated with cervical lymphadenectomy to remove all clinically positive nodes, other levels of the neck that may be at high risk for harboring metastasis, and non-lymphatic structures that are directly involved with cancer. Determining whether an ipsilateral or bilateral neck dissection is needed depends on location and the extent of the tumor, particularly for tumors that approach or involve the midline where bilateral lymphatic drainage is likely.[125] When anatomic imaging and/or fine-needle aspiration (FNA) identify pathologic adenopathy bilaterally, both sides of the neck should be dissected.

Discussion update in progress

Version 1.2026 © 2025 National Comprehensive Cancer Network© (NCCN©), All rights reserved. NCCN Guidelines® and this illustration may not be reproduced in any form without the express written permission of NCCN.

PLEASE NOTE that use of this NCCN Content is governed by the End-User License Agreement, and you MAY NOT distribute this Content or use it with any artificial intelligence model or tool.
Printed by Galya Basol Kochav on 1/4/2026 9:40:35 AM. Copyright © 2026 National Comprehensive Cancer Network, Inc. All Rights Reserved.

Guidance on neck management following definitive RT or systemic therapy/RT treatment can be found in *Follow-Up Recommendations: Post Systemic Therapy/RT or RT Neck Evaluation* in the NCCN Guidelines for Head and Neck Cancers.

Postoperative Management of High-Risk Disease

Many factors influence survival and locoregional tumor control in patients with H&N cancers. The role of systemic therapy/RT in the postoperative care of the patient with adverse prognostic risk factors has been clarified by two separate multicenter randomized trials for patients with high-risk cancers of the oral cavity, oropharynx, larynx, or hypopharynx.[138,139] A combined analysis of data from the two trials has been done.[140]

The US Intergroup trial (RTOG 9501) randomly assigned patients with two or more involved nodes, positive margins, or extracapsular nodal spread of tumor to receive standard postoperative RT or the same RT plus cisplatin (100 mg/m^2 every 3 weeks for three doses).[139] Note that long-term results from RTOG 9501 have been published.[141] The European trial (EORTC 22931) was designed using the same chemotherapy treatment and similar RT dosing but also included as high-risk factors the presence of perineural or vascular embolism and nodal involvement at levels IV and V from an oral cavity or oropharyngeal cancer.[138] The RTOG trial showed statistically significant improvement in locoregional control and disease-free survival (DFS) but not OS, whereas the EORTC trial found significant improvement in survival and the other outcome parameters.

To better define risk, a combined analysis of prognostic factors and outcome from the RTOG 9501 and EORTC 22931 trials was performed. This analysis showed that patients in both trials with extranodal extension of tumor and/or positive resection margins benefited from the addition of cisplatin to postoperative RT. For those with multiple involved regional nodes without extranodal extension, there was no survival advantage.[140,141] However, it is important to note that the combined analysis was considered exploratory by the authors.[140] These publications form the basis for the NCCN recommendations regarding adjuvant treatment.

In NCCN Member Institutions, most patients with extranodal extension with or without positive surgical margins receive adjuvant chemoradiotherapy after surgery. The presence of other adverse pathologic risk factors—multiple positive nodes (without extranodal extension), perineural invasion, vascular invasion, lymphatic invasion, pT3 or pT4 primary, and oral cavity or oropharyngeal primary cancers with positive level IV or V nodes—are generally established indications for postoperative RT. Because patients with these other adverse pathologic features were also included in the EORTC 22931 trial that showed a survival advantage for patients receiving cisplatin concurrently with postoperative RT compared to RT alone, the NCCN Panel added a recommendation to consider chemoradiation for these features.[138] Performance status (PS) and physiologic reserve should be taken into consideration before recommending postoperative concurrent chemoradiotherapy in patients with high-risk pathology.

In a randomized phase III trial from a single institution in India, cisplatin 30 mg/m^2 weekly was compared to cisplatin 100 mg/m^2 every 3 weeks, when given concurrently with RT, in 300 patients with locally advanced SCCHN (93% in the adjuvant setting).[142] Two-year locoregional control was superior in patients randomized to receive cisplatin once every 3 weeks (73.1%), compared to patients randomized to receive weekly cisplatin (58.5%) (HR, 1.76; 95% CI, 1.11–2.79; P = .014). However, patients randomized to receive cisplatin once every 3 weeks developed more severe acute toxicities, compared to patients randomized to receive weekly cisplatin (84.6% vs. 71.6%, respectively; P = .006). The acute adverse events that were significantly more likely to have been reported in

Discussion update in progress

Version 1.2026 © 2025 National Comprehensive Cancer Network© (NCCN©), All rights reserved. NCCN Guidelines® and this illustration may not be reproduced in any form without the express written permission of NCCN.

PLEASE NOTE that use of this NCCN Content is governed by the End-User License Agreement, and you MAY NOT distribute this Content or use it with any artificial intelligence model or tool.
Printed by Galya Basol Kochav on 1/4/2026 9:40:35 AM. Copyright © 2026 National Comprehensive Cancer Network, Inc. All Rights Reserved.

patients who received cisplatin once every 3 weeks were hyponatremia, leukopenia, neutropenia, and lymphocytopenia ($P < .001$ for all). A schedule using cisplatin at 50 mg intravenously (IV) weekly has also been shown to improve survival in the adjuvant setting in a randomized trial.[143]

In a randomized phase II/III study from India in which patients with locally advanced SCCHN and who were cisplatin-ineligible received RT alone or concurrently with docetaxel (N = 356), 2-year DFS (42.0% vs. 30.3%, respectively; HR, 0.67, 95% CI, 0.52–0.87; $P = .002$), median OS (25.5 vs. 15.3 months, respectively; $P = .035$), and 2-year OS (50.8% vs. 41.7%, respectively; HR, 0.75, 95% CI, 0.57–0.98; $P = .035$) were all significantly greater in the docetaxel arm compared to the RT alone arm (39% treated postoperatively).[144] There was a significantly greater incidence of some grade 3 or above adverse events (mucositis, odynophagia, and dysphagia) in the docetaxel arm. Study results support use of docetaxel as a radiosensitizer for patients undergoing adjuvant treatment who are cisplatin ineligible.

In the randomized phase II RTOG-0234 trial, two regimens in patients with stage III and IV SCCHN were compared: 1) adjuvant chemoradiotherapy with cetuximab and docetaxel; and 2) adjuvant chemoradiotherapy with cetuximab and weekly cisplatin ($N = 238$).[145] After a median follow-up of 4.4 years, patients randomized to receive docetaxel experienced a 31% reduction in DFS failure rate (HR, 0.69; 95% CI, 0.50–0.96; $P = .01$), and a 44% reduction in mortality (HR, 0.56; 95% CI, 0.39–0.82; $P = .001$). The randomized phase II/III RTOG 1216 trial is continuing to investigate docetaxel/cetuximab with postoperative RT, compared to cisplatin or docetaxel with postoperative RT (NCT01810913). For patients with high-risk adverse pathologic features following surgery (ie, extranodal extension and/or positive margins) who are ineligible for platinum therapy, docetaxel/cetuximab is a category 2B option for postoperative systemic therapy/RT.

Surgery for Relapsed/Refractory Disease

Patients with advanced carcinoma (any T, N2–3) who undergo nonsurgical treatment, such as concurrent chemotherapy and RT, need very close follow-up both to evaluate for local recurrence and to assess for ipsilateral or contralateral neck recurrence (see *Follow-up Recommendations* in the NCCN Guidelines for Head and Neck Cancers). For patients who do not have a complete clinical response to systemic therapy/RT, surgery is recommended as indicated. However, all Panel members emphasized that it may be difficult to detect local or regional recurrence due to radiation-related tissue changes, and this may result in a delayed diagnosis of persistent or recurrent disease.

Panel members also emphasized the increased risk of complications when surgery in patients with relapsed/refractory disease is attempted. Some of these patients may require microvascular free tissue transfer to reconstruct the surgical defect at the primary site. The patients undergoing neck dissection may develop complications related to delayed wound healing, skin necrosis, neuropathy, fibrosis, pain, swallowing difficulties, and carotid exposure. Laryngectomy may be indicated to obtain clear surgical margins or to prevent aspiration (eg, in patients with advanced oropharyngeal cancer). After laryngectomy for relapsed/refractory disease, patients may have a higher incidence of pharyngocutaneous fistula, pharyngeal and stomal stenosis, and other wound complications.[146] Flaps may be advantageous (either a free flap reconstruction of the laryngopharyngeal defect, or a myocutaneous flap to buttress the suture line if the pharynx can be closed primarily).

Palliative Surgery

Cancer itself and cancer directed treatments can both lead to tissue damage and unwanted side effects. Palliative surgical interventions may be warranted. This may include placement of a tracheostomy for respiratory distress due to insufficient airway, a mandibulectomy and

Discussion update in progress

Version 1.2026 © 2025 National Comprehensive Cancer Network© (NCCN©), All rights reserved. NCCN Guidelines® and this illustration may not be reproduced in any form without the express written permission of NCCN.

PLEASE NOTE that use of this NCCN Content is governed by the End-User License Agreement, and you MAY NOT distribute this Content or use it with any artificial intelligence model or tool.
Printed by Galya Basol Kochav on 1/4/2026 9:40:35 AM. Copyright © 2026 National Comprehensive Cancer Network, Inc. All Rights Reserved.

microvascular free flap reconstruction secondary to osteoradionecrosis, or a gastrostomy tube insertion for nutrition support in those with dysphagia and/or at risk for aspiration. To promote symptom palliation and quality of life throughout the continuum of care, patients with head and neck cancer should be routinely assessed for eligibility for palliative surgical interventions.[147]

Head and Neck Radiation Therapy

RT for H&N cancers is increasingly complex. The availability and technical precision of techniques such as intensity-modulated RT (IMRT) or intensity-modulated proton therapy (IMPT) have each markedly increased. However, a thorough understanding of the natural history, anatomy, clinical circumstances, and imaging of specific disease conditions continues to guide the use of radiation as primary or adjuvant treatment.

Principles regarding radiation prescriptions and techniques as described in the NCCN Guidelines for Head and Neck Cancers are not all-inclusive. The planning and delivery of RT are rapidly evolving, and these technological advances provide much opportunity for variations and individualization in targeting and dose delivery, obviating traditional notions of *standard* fields and targets. Guidelines from the American College of Radiology describe basic technical specifications. Furthermore, major consensus contouring guidelines for treatment of H&N cancers are available for reference, especially for patients who are treated without surgery.[148,149]

When radiation is given with definitive intent, the dosages prescribed for gross disease are fairly standard, usually in the range of 70 Gy (at approximately 2 Gy/fraction/day) for the following sites: lip, oral cavity, nasopharynx, oropharynx, hypopharynx, glottic larynx, supraglottic larynx, occult primary, salivary gland tumors, and MM. A second dose (often approximately 60 Gy, but varies) may be used to cover volumes considered at the highest risk for microscopic spread, while a lower dose (often approximately 50 Gy, but varies) is used for volumes treated electively with low risk for microscopic spread.

Although several palliative RT regimens are provided, no single regimen is preferred[150,151]; specific regimens vary widely among NCCN Member Institutions. Any palliative RT regimen that might cause severe toxicities should be avoided. More hypofractionated regimens may be useful for patients with limited life expectancy, such as a few months. For example, a common version of the QUAD SHOT regimen consists of a dose of 44.4 Gy, delivered in 12 fractions over three cycles, with each cycle separated by 2 to 3 weeks.[152]

Radiation Doses

Selection of an exact radiation dose prescription and schedule of delivery depends on the primary tumor and neck node size, whether altered fractionation is used, and clinical circumstances, including whether concurrent systemic therapy will be used (see *Principles of Radiation Techniques* in the NCCN Guidelines for Head and Neck Cancers and see the individual *Principles of Radiation Therapy* for each primary site). The dose may need to be decreased if it is prescribed very close to adjacent organ at risk (eg, brain, cochlea, optic chiasm and nerves, spinal cord). In these cases, precise target definition and delineation is crucial, and on-treatment imaging should be used to ensure accurate radiation delivery. Anatomical changes (eg, rapidly shrinking tumors, changes in air cavities, significant weight loss) may necessitate repeat imaging and treatment replanning.

When treating definitively using conventional fractionation, the primary tumor and involved lymph nodes (ie, high-risk sites) generally require a total of 66 Gy (2.0–2.2 Gy/fraction) to 70 Gy (2.0 Gy/fraction).[153-156] For areas considered highly sensitive to radiation, such as neural structures, some clinicians feel that the fractionation should be slightly modified (eg,

Discussion update in progress

Version 1.2026 © 2025 National Comprehensive Cancer Network© (NCCN©), All rights reserved. NCCN Guidelines® and this illustration may not be reproduced in any form without the express written permission of NCCN.

PLEASE NOTE that use of this NCCN Content is governed by the End-User License Agreement, and you MAY NOT distribute this Content or use it with any artificial intelligence model or tool.
Printed by Galya Basol Kochav on 1/4/2026 9:40:35 AM. Copyright © 2026 National Comprehensive Cancer Network, Inc. All Rights Reserved.

<2.0 Gy/fraction for at least some of the treatment) to minimize toxicity; in these cases, additional fractions can be added depending on clinical circumstances to increase the total physical dose. For instance, a hyperfractionated schedule allows gross disease to be prescribed a dose up to 81.6 Gy (at 1.2 Gy/fraction); hyperfractionation has been used for situations when tumor is abutting brain or optic structures.[153,154] Care must be taken if prescribed doses exceed 72 Gy using conventional fractionation (2.0 Gy/fraction), as this may lead to unacceptable rates of normal tissue injury; however, these data were collected in the era prior to advanced techniques such as IMRT or IMPT.[153,157] In contrast, when using conventional fractionation, elective irradiation to low- and intermediate-risk sites is usually prescribed at 44 Gy (2.0 Gy/fraction) to 63 Gy (1.6–1.8 Gy/fraction), depending on the estimated risk of tumor involvement, and on whether 3D conformal RT (3D-CRT) or IMRT is used. For 3D-CRT and sequential plans using IMRT, a range of 44–50 Gy (2.0 Gy/fraction) is often suggested.[158,159] For simultaneous integrated boost (SIB) IMRT, a range of doses from 54–63 Gy (1.6–1.8 Gy/fraction) can be used depending on the fractionation schedule and the risk of tumor involvement in the area where the dose is prescribed.[159-161] In definitive RT, the delivery of six fractions per week is widely accepted, in a mildly accelerated schedule, especially if chemotherapy is not prescribed concurrently.[155] Hypofractionation, when RT is given at >3.0 Gy/fraction, has been reported in some single institutional experiences and clinical trials,[151,152,162,163] but a lack of high-level randomized comparator data and concerns about the possibility of long-term late toxicity have limited its widespread adoption to date.

Postoperative irradiation is recommended based on stage, histology, and surgical-pathologic findings. In general, postoperative RT is recommended for selected risk factors, including advanced T stage, close surgical margins, depth or extent of invasion, multiple positive nodes, or perineural/lymphovascular invasion. High doses of postoperative RT alone (eg, 66 Gy) and/or systemic therapy/RT are recommended for the high-risk features of extranodal extension and/or positive margins.[140,141,156] Particularly for these high-risk cases, the preferred maximum elapsed time interval between surgical resection and the start of postoperative RT is ≤6 weeks.

Postoperative radiation fractionation schedules tend to be similar (60–66 Gy at 2 Gy/fraction) whether or not systemic therapy is administered concurrently with postoperative RT. Hypofractionation may be considered for patients who are not good candidates for an extended course of several weeks of RT due to resource limitations or comorbidities, but these schedules have not been widely adopted as late effects are a particular concern in the postoperative population.

Fractionation in RT Alone

No single fractionation schedule has proven to be best for all tumors. Data strongly indicate that SCCHN can grow rapidly and may compensate for RT-induced cell loss through the mechanism of accelerated repopulation.[164,165] Especially in the RT-alone setting, schedules delivering at least 1000 cGy per week to gross disease are recommended,[166-168] although it is acknowledged that some tumors such as those of the salivary gland may have slower cell kinetics. Trials in early-stage laryngeal glottic cancer have shown higher recurrence rates with daily fraction sizes <200 cGy where the cumulative weekly dose is <1000 cGy.[169,170]

Two large, randomized trials from Europe have reported improved locoregional control using altered fractionation as compared to conventional fractionation, when concurrent chemotherapy is not given. The EORTC protocol 22791 compared hyperfractionation (1.15 Gy twice daily, or 80.5 Gy over 7 weeks) with conventional fractionation (2 Gy once daily, or 70 Gy over 7 weeks) in the treatment of T2, T3, N0–1 oropharyngeal carcinoma excluding base of tongue primaries. At 5 years, a statistically significant increase in local control was observed in the

Discussion update in progress

Version 1.2026 © 2025 National Comprehensive Cancer Network© (NCCN©), All rights reserved. NCCN Guidelines® and this illustration may not be reproduced in any form without the express written permission of NCCN.

PLEASE NOTE that use of this NCCN Content is governed by the End-User License Agreement, and you MAY NOT distribute this Content or use it with any artificial intelligence model or tool.
Printed by Galya Basol Kochav on 1/4/2026 9:40:35 AM. Copyright © 2026 National Comprehensive Cancer Network, Inc. All Rights Reserved.

hyperfractionation arm (38% vs. 56%; *P* = .01) and no increase in late complications was observed.[171] A long-term follow-up analysis has also shown a small survival advantage for hyperfractionation (*P* = .05).[172] Another EORTC protocol (22851) compared accelerated fractionation (1.6 Gy 3 times daily, or 72 Gy over 5 weeks) with conventional fractionation (1.8–2.0 Gy once daily, or 70 Gy over 7–8 weeks) in various intermediate to advanced H&N cancers (excluding cancers of the hypopharynx). Patients in the accelerated fractionation arm had significantly better locoregional control at 5 years (*P* = .02). Disease-specific survival (DSS) showed a trend in favor of the accelerated fractionation arm (*P* = .06). However, acute and late toxicity were increased with acceleration, raising questions about the net advantages of accelerated fractionation.[173]

The RTOG reported the results of a four-arm, phase III, randomized clinical trial (RTOG 90-03) comparing hyperfractionation and two variants of accelerated fractionation versus standard fractionation.[153,154,174] After 2 years of follow-up, both accelerated fractionation using a concomitant boost (AFX-C) and hyperfractionation were associated with improved locoregional control and DFS compared with standard fractionation. Acute toxicity was increased with both of these regimens. However, no significant difference was shown in the frequency of grade 3 or worse late effects at 6 to 24 months after treatment start, among the various treatment groups. Long-term follow-up confirmed a statistically significant improvement in locoregional control and OS with hyperfractionation compared to standard fractionation.[154]

The MARCH meta-analysis, including individual patient data from 15 randomized trials, analyzed the effect of hyperfractionated or accelerated RT on survival of patients with H&N cancers.[175] Standard fractionation constituted the control arm in all of the trials in this meta-analysis.[155] An absolute survival benefit for altered fractionation of 3.4% at 5 years (HR, 0.92; 95% CI, 0.86–0.97; *P* = .003) was reported. This benefit, however, was limited to patients <60 years of age.[175] Hyperfractionation was associated with a benefit of 8% after 5 years.[176] An update to the MARCH meta-analysis, including data from 33 trials, continued to show a survival benefit of hyperfractionation, compared to standard fractionation (HR, 0.83; 95% CI, 0.74–0.92; *P* < .001), in patients with locally advanced SCCHN.[177]

Consensus on the optimal use of altered fractionation schedules using either concomitant boost or hyperfractionation for stage III or IV oral cavity, oropharynx, supraglottic larynx, and hypopharyngeal squamous cell cancers has not yet emerged among NCCN Member Institutions.[175,178,179] Furthermore, as described below, using altered fractionation in conjunction with most concurrent systemic agents remains controversial.

Fractionation in Concurrent Chemoradiation

Panel members generally agree on conventionally fractionated radiation in combination with most concurrent systemic therapies in the definitive treatment setting. Most published studies have used conventional fractionation (at 2.0 Gy/fraction to a typical dose of 70 Gy in 7 weeks) with single-agent high-dose cisplatin (given every 3 weeks at 100 mg/m^2).[32] Other fraction sizes (eg, 1.8 Gy/fraction), other dosing schedules of cisplatin (eg, weekly), other single concurrent agents, concurrent multiagent systemic therapy, and altered fractionation schedules with concurrent systemic therapy have been evaluated alone or in combination. Numerous trials have shown that altered fractionation and concurrent chemotherapy are more efficacious than altered fractionation alone.[179-181] However, conversely, the GORTEC 99-02 trial reported that altered fractionation did not improve outcomes when compared with conventional fractionation given with concurrent chemotherapy.[182,183] Similarly, RTOG 0129 assessed accelerated fractionation with two cycles of concurrent cisplatin versus standard fractionation with three cycles of concurrent cisplatin. There was no significant difference in OS between the two

Discussion update in progress

Version 1.2026 © 2025 National Comprehensive Cancer Network© (NCCN©), All rights reserved. NCCN Guidelines® and this illustration may not be reproduced in any form without the express written permission of NCCN.

PLEASE NOTE that use of this NCCN Content is governed by the End-User License Agreement, and you MAY NOT distribute this Content or use it with any artificial intelligence model or tool.
Printed by Galya Basol Kochav on 1/4/2026 9:40:35 AM. Copyright © 2026 National Comprehensive Cancer Network, Inc. All Rights Reserved.

arms,[32,184,185] indicating that accelerated fractionation is not clearly more efficacious than conventional fractionation in the setting of concurrent chemotherapy.

Concurrent chemoradiation increases acute toxicity compared to radiation alone, although an increase in late toxicity beyond that caused by RT alone is less clearly established.[186-188] Multiagent systemic therapy may further increase the acute and late toxicity burden.[189] For any chemotherapeutic approach, close attention should be paid to published reports for the specific chemotherapy agent, dose, and schedule of administration. Chemoradiation should be performed by an experienced team and should include state-of-the-art supportive care.

Radiation Techniques

IMRT

Using contemporary computer-based planning and radiation delivery, the intensity of the radiation beam can be modulated to decrease doses to normal structures with minimal compromise of the doses to the cancer targets.[190,191] Over the last 15 years, IMRT has displaced older techniques in the treatment of most H&N malignancies.[192-199] IMRT is a highly advanced form of CRT permitting more precise cancer targeting while reducing dose to normal tissues.[159,200-203]

IMRT dose painting, also known as SIB, refers to the method of assigning different dose levels to different anatomic areas. These areas are all simultaneously irradiated within the same treatment fraction but receive different prescribed doses (eg, 2.0 Gy/fraction to gross tumor, 1.6 Gy/fraction to neck at risk for microscopic tumor, <1.0 Gy/fraction to parotid gland) resulting in different total doses to the different targets (eg, 70 Gy, 56 Gy, <26 Gy).[204,205] Although dose painting has been used to improve the specificity of radiation delivery to tumors and thereby reduce unwanted radiation of uninvolved areas, hot spots associated with higher toxicity can occur within large tumor targets due to the increasing heterogeneity of dose distribution that occurs when prescribing to large volumes.[205,206] An alternative to the dose painting or SIB approach is to create two plans, one irradiating widely to a low dose and one boosting specific areas to a higher dose; the boost plan may be delivered after completion of the initial plan, or the two plans may be delivered on the same day as separate fractions in twice-daily schemas (see *Principles of Radiation Techniques* in the NCCN Guidelines for Head and Neck Cancers).[155,202,207,208] A meta-analysis including seven studies (n = 1049) showed no significant difference in survival outcomes or grade 3 or higher adverse events between SIB-IMRT and sequential boost-IMRT.[209]

IMRT is now widely used in H&N cancers and is the predominant technique used at NCCN Member Institutions.[210,211] OS may be similar between patients treated with IMRT and those receiving conventional 3D-RT,[192,212-214] but both are superior to older 2D techniques. For example, a prospective Korean study showed that 3D and IMRT techniques were superior to 2D radiation for both PFS and OS in patients with NPC, and IMRT was associated with improved survival in multivariate analysis, particularly in T3–T4 tumors.[215] However, IMRT has been clearly proven to reduce long-term toxicities. Xerostomia is a common long-term side effect of RT, which is ameliorated most commonly by use of IMRT, or from application of drug therapy (eg, pilocarpine, cevimeline), salivary substitutes, and other novel approaches (eg, surgical relocation of submandibular gland).[197,216-220] Importantly, xerostomia has decreased due to the transition from older 2D and 3D radiotherapy techniques to IMRT.[192,194] Numerous phase II and III studies show that IMRT decreases late toxicity (xerostomia) without compromising tumor control for nasopharyngeal, oropharyngeal, sinonasal, and other sites.

Multiple randomized phase III trials support the clinical benefits of IMRT in H&N cancers with regard to the reduction in xerostomia. Pow et al

Discussion update in progress

Version 1.2026 © 2025 National Comprehensive Cancer Network© (NCCN©), All rights reserved. NCCN Guidelines® and this illustration may not be reproduced in any form without the express written permission of NCCN.

PLEASE NOTE that use of this NCCN Content is governed by the End-User License Agreement, and you MAY NOT distribute this Content or use it with any artificial intelligence model or tool.
Printed by Galya Basol Kochav on 1/4/2026 9:40:35 AM. Copyright © 2026 National Comprehensive Cancer Network, Inc. All Rights Reserved.

evaluated treatment of early-stage NPC with conventional RT techniques versus with IMRT.[217] The results showed a statistical improvement in salivary flow and in patient-reported QOL parameters.[217] In the study by Kam et al, patients with NPC were randomly assigned to either IMRT or conventional 2D-RT.[197] At 1 year after treatment, patients in the IMRT arm had significantly lower rates of clinician-rated severe xerostomia than patients in the 2D-RT arm (39.3% vs. 82.1%; $P = .001$). Salivary flow rates were also higher with IMRT. The mean parotid dose was 32 Gy in the IMRT group and 62 Gy in the conventional group. Although a trend for improvement in patient-reported dry mouth was observed after IMRT, recovery was incomplete and there was no significant difference in patient-reported outcomes between the two arms. The authors concluded that other salivary glands may also be important and merit protection. Finally, data from a phase III randomized trial in the United Kingdom (PARSPORT) indicate that IMRT decreases xerostomia when compared with conventional RT in patients with non-NPC cancers.[192] In this trial, patients with T1–T4, N0–N3, M0 disease were treated to a total dose of 60 or 65 Gy in 30 fractions either with conventional RT (ie, parallel opposed 3D technique) or with IMRT; 80 patients with oropharyngeal and 14 patients with hypopharyngeal tumors were included. Grade 2 or worse (LENT-SOMA scale) xerostomia 2 years after treatment was seen in 83% of patients receiving conventional RT versus 29% of patients in the IMRT group ($P < .0001$). No differences were seen in the rates of locoregional control or survival. A fourth trial, GORTEC 2004-01, showed that dose-escalated IMRT (50 Gy in 25 fractions followed by a sequential boost of 25 Gy in 10 fractions), delivered concurrently with cisplatin, reduced xerostomia in patients with locally advanced SCCHN, as compared to the control arm of 3D-RT (50 Gy in 25 fractions followed by a sequential boost of 20 Gy in 10 fractions) delivered concurrently with cisplatin (23% vs. 63%, respectively, after 1 year, and 11% vs. 45%, respectively, after 3 years).[221] Locoregional control did not significantly differ between the two study arms.

IMRT likely reduces other long-term toxicities due to decreased radiation doses to structures such as pharyngeal constrictors, larynx, temporal lobes, mandible, auditory structures (including cochlea), and optic structures.[160,197,217,222-227] For instance, in a phase III randomized control trial (RCT) from the UK and Ireland, a dysphagia-optimized IMRT intervention in which the constrictor muscles of the pharynx were spared improved swallowing outcomes at 12 months compared to standard IMRT ($P = .037$) in patients with early stage and locally advanced cancers of the oropharynx or hypopharynx.[228] Retrospective analyses including 2993 patients who received RT for treatment of H&N cancer showed that patients who received IMRT had a shorter duration of feeding tube placement, compared to those who received 3D-RT ($P = .03$).[229] There are numerous other specific advantages of IMRT that apply to challenging anatomical situations. IMRT is particularly useful in avoiding excess radiation of the optic pathway in patients with sinonasal malignancies.[222] However, the randomized phase III COSTAR trial did not show that cochlear-sparing IMRT significantly reduced hearing loss in patients with parotid tumors, compared to 3D-CRT.[227] One caveat is that additional care must be taken when using IMRT as it can create unanticipated toxicities to organs unexpectedly radiated in the beam path; a careful and informed examination of all organs potentially affected by these novel distributions of the radiation dose is mandatory.[230,231]

Proton Beam Therapy

At present, proton therapy is the predominant particle therapy under active clinical investigation in the United States.[232-235] Proton therapy has been reported in the treatment of skull base tumors, oropharyngeal cancers, sinonasal malignancies, adenoid cystic carcinomas, and MMs.[236-244] Proton therapy has typically been used to treat patients with the most challenging disease configurations, for which other RT options were not felt to be safe or of any benefit.[239,245,246] Proton therapy has also been

Discussion update in progress

Version 1.2026 © 2025 National Comprehensive Cancer Network© (NCCN©), All rights reserved. NCCN Guidelines® and this illustration may not be reproduced in any form without the express written permission of NCCN.

PLEASE NOTE that use of this NCCN Content is governed by the End-User License Agreement, and you MAY NOT distribute this Content or use it with any artificial intelligence model or tool.
Printed by Galya Basol Kochav on 1/4/2026 9:40:35 AM. Copyright © 2026 National Comprehensive Cancer Network, Inc. All Rights Reserved.

proposed for children and young adults where a reduced exposure to low-level falloff radiation dose is an appealing feature.

Data supporting the use of proton beam therapy (PBT) come mainly from nonrandomized institutional reports and a small number of systematic reviews. A systematic review and meta-analysis of non-comparative observation studies concluded that patients with malignant diseases of the nasal cavity and paranasal sinuses who received proton therapy appeared to have better outcomes than those receiving photon therapy.[247] A review of proton therapy in patients with H&N cancers included 14 retrospective reviews and four prospective nonrandomized studies.[233] The 2- to 5-year local control rates were as low as 17.5% for T4 or recurrent paranasal sinus cancers and as high as 95% for other tumor types.

In institutional series, the reported outcomes for proton therapy have included good locoregional control, freedom from distant metastasis, and acceptable toxicity.[233,241,244,248-251] PBT may be associated with even greater normal tissue sparing without sacrificing target coverage, which is hypothesized to be associated with reduced toxicity compared to IMRT.[248] This may be a particular advantage in cases of reirradiation.[252]

However, the planning and delivery of PBT continues to develop, and occasional fatal outcomes have been reported with proton therapy due to uncertainties associated with these evolving technologies, including a small number of deaths secondary to brainstem injury in children.[253-255] In general, clinicians have reported low rates of serious toxicities when using strict dose limits for proton therapy.[245,256] However, disadvantageous and advantageous outcomes continue to be more fully documented as the clinical experience accrues. A pooled analysis of 17 studies including patients with head and neck cancer treated with PBT showed a rate of grade ≥3 osteoradionecrosis is 0.01 (95% CI, 0.01–0.03),[257] although retrospective analyses have shown increased potential for this complication in single-institutional experiences.[258] In patients who have tumors that are periocular in location and/or invade the orbit, skull base, and/or cavernous sinus, or whose primary tumors extend intracranially or exhibit extensive perineural invasion, highly conformal dose distributions are crucial, and proton therapy may provide certain unique advantages. In patients with these types of tumors who are being treated with curative intent and/or have long life expectancies, PBT may offer the opportunity for lower late-onset toxicities.[259]

As described above, nonrandomized institutional reports and a small number of systematic reviews have shown that PBT is safe to use in a controlled setting where specialized physics support is available. However, without high-quality prospective comparative data, it is premature to conclude that proton therapy has been established as invariably superior to other modern radiation techniques such as IMRT, particularly with regard to tumor control. An accurate comparison of benefits to other RT options would ideally take place in the controlled setting of randomized clinical trials.

Given the unique abilities of PBT to treat more difficult tumors, randomized trials may not be possible for some scenarios. In these cases, an alternative approach may be to develop prospectively maintained databases to raise the quality of institutional reports of clinical experiences.[255] In cancers of the oropharynx, supraglottic larynx, nasopharynx, paranasal sinus, and salivary glands, as well as MM, and unknown primary tumors of the H&N, the Panel agrees that proton therapy should be considered when normal tissue constraints cannot be met by photon-based therapy, or when photon-based therapy causes compromise of standard radiation dosing to tumor or postoperative volumes. The Panel supports ongoing efforts to develop models to predict which patients would benefit the most from proton therapy and the development of higher-level and/or randomized data demonstrating greater efficacy or meaningful QOL gains potentially achieved with PBT.

Discussion update in progress

Version 1.2026 © 2025 National Comprehensive Cancer Network© (NCCN©), All rights reserved. NCCN Guidelines® and this illustration may not be reproduced in any form without the express written permission of NCCN.

PLEASE NOTE that use of this NCCN Content is governed by the End-User License Agreement, and you MAY NOT distribute this Content or use it with any artificial intelligence model or tool.
Printed by Galya Basol Kochav on 1/4/2026 9:40:35 AM. Copyright © 2026 National Comprehensive Cancer Network, Inc. All Rights Reserved.

Brachytherapy

Brachytherapy is a uniquely conformal modality that is considered to be effective and safe when delivered by an experienced team of practitioners. Brachytherapy is now necessary less often because of improved local control and lower toxicities obtained with IMRT with or without systemic therapy. However, brachytherapy still has an important role in cancers of the lip and oral cavity (see *Cancer of the Oral Cavity [Including Mucosal Lip]: Principles of Radiation Therapy* in the NCCN Guidelines for Head and Neck Cancers).[260] Brachytherapy may have a role in other select clinical scenarios such as reirradiation, as a boost for highly refractory disease or a positive surgical margin, or when extremely conformal radiation delivery is needed to a very well-defined tumor location; these are unique situations arising from challenging clinical circumstances and limited availability of head and neck brachytherapy expertise.

The potential for brachytherapy to reduce side effects, because of its uniquely conformal radiation dose distribution, remains a matter of debate. A randomized trial investigated the reduction in xerostomia at 6 months, assessed using ^{99m}Tc salivary scintigraphy, in patients receiving IMRT or IMRT combined with brachytherapy in patients with T1–T2 N0 M0 oropharyngeal SCC.[261] Ninety patients were randomized, but evaluation was not possible in 20 patients at 6 months. In the remaining 70 participants, scintigraphy-determined xerostomia rates were 14% and 44% in the brachytherapy-containing and IMRT-alone arms, respectively. However, it is uncertain if these results would be reproduced in centers without high volume and expertise in this modality.

Stereotactic Body Radiation Therapy

Stereotactic body RT (SBRT) is an advanced technique of external beam RT (EBRT) that delivers large ablative doses of radiation in a limited number of fractions. Advantages of SBRT include shorter treatment time, promising local control rates, and higher but acceptable toxicity depending on the specific location treated.[262] There is currently insufficient evidence to recommend SBRT routinely for treatment of H&N cancers, but the NCCN Panel acknowledges that it might be beneficial in the settings of re-irradiation, palliation, or for older adults.[263-265] One emerging setting where SBRT has been of increasing interest is oligometastatic disease. In the GORTEC OMET phase II trial, in which 69 patients having oligometastatic H&N cancers were randomized to receive SBRT with or without EXTREME-based chemotherapy, the median survival was 42.3 months (95% CI, 26.5–not reached) with chemotherapy-SBRT and 41.1 months (95% CI, 32.1–66.9) with SBRT alone.[266]

SBRT has been reported in numerous retrospective reviews in the reirradiation setting.[267] Careful anticipation of toxicity is especially important in planning the delivery of this modality to a patient. Small prospective studies have aimed at the purpose of demonstrating safety and feasibility in combination with systemic therapies including cetuximab or cisplatin but continued caution is advised due to the relatively limited experience with combining these modalities.[268,269]

Follow-up After RT

For patients whose cancer has been treated with RT, the recommended follow-up (see *Follow-up Recommendations* in the NCCN Guidelines for Head and Neck Cancers) includes an assessment of thyroid function (ie, the thyroid-stimulating hormone [TSH] level should be determined every 6–12 months) and surveillance-oriented physical examination, symptom assessment and supportive care, and/or imaging as clinically indicated. Increased TSH levels have been detected in 20% to 25% of patients who have received neck irradiation.[270-272] Changes in TSH may indicate thyroid gland dysfunction or hypopituitarism if the skull base was irradiated. For patients with signs or symptoms or who are at high risk for hypopituitarism, screening laboratories may include growth hormone (GH), follicle-stimulating hormone/luteinizing hormone (FSH/LH), free T4, insulin-like

Discussion update in progress

Version 1.2026 © 2025 National Comprehensive Cancer Network© (NCCN©), All rights reserved. NCCN Guidelines® and this illustration may not be reproduced in any form without the express written permission of NCCN.

PLEASE NOTE that use of this NCCN Content is governed by the End-User License Agreement, and you MAY NOT distribute this Content or use it with any artificial intelligence model or tool.
Printed by Galya Basol Kochav on 1/4/2026 9:40:35 AM. Copyright © 2026 National Comprehensive Cancer Network, Inc. All Rights Reserved.

growth factor 1 (IGF-1), TSH, adrenocorticotropic hormone (ACTH), and prolactin.

Systemic Therapy for Locally Advanced Squamous Cell Carcinoma of the Head and Neck

Treatment that includes systemic therapy of H&N cancers is recommended for locoregionally advanced and metastatic disease. This section describes systemic therapy for locally advanced SCCHN with concurrent or sequential RT-based treatment. In patients with newly diagnosed recurrent or metastatic SCCHN, testing for programmed death ligand 1 (PD-L1) combined positive score (CPS) should be performed to guide treatment decisions, and next-generation sequencing (NGS) genomic profiling for biomarker identification of actionable alterations may be considered to guide treatment options. For detailed recommendations on combination and single-agent systemic therapy for metastatic (M1) disease (without surgery or RT treatment), see the section below under *Very Advanced Head and Neck Cancers*. Systemic therapy/RT for locoregionally advanced nasopharyngeal cancer is described below under *Cancer of the Nasopharynx*.

Primary Systemic Therapy with Concurrent RT

Randomized trials[143,273-281] and meta-analyses[282-286] showed significantly improved OS, DFS, and locoregional control when a systemic therapy and RT regimen (concomitant or, less commonly, sequential) was compared with RT alone for locally advanced disease. Limited data are available comparing the efficacy of different chemoradiotherapy regimens.

High-dose cisplatin plus RT is the most studied effective systemic therapy/RT regimen and typically uses conventional fractionation or RT at 2.0 Gy per fraction to 70 Gy administered over 7 weeks with concurrent high-dose cisplatin 100 mg/m^2 given every 3 weeks for up to three doses.[156,273] Because of perceived lower toxicity, low-dose once-a-week cisplatin has been studied. A randomized phase III trial compared cisplatin 30 mg/m^2 given once weekly to high-dose cisplatin, both given with RT to patients with locally advanced SCCHN.[142] The primary endpoint was locoregional control. Most patients (93%) received study treatment in the adjuvant setting. Locoregional control was inferior in the cisplatin 30 mg/m^2 weekly arm compared to the high-dose cisplatin arm. The 2-year locoregional control rate was 58.5% in the low-dose weekly cisplatin arm and 73.1% in the high-dose cisplatin arm (P = .014). Acute toxicities of grade 3 or greater were less common in the low-dose weekly arm compared to the high-dose cisplatin arm (71.6% vs. 84.6%; P = .006). A systematic review and meta-analysis including six randomized studies with 554 patients with SCCHN showed that OS, PFS, and toxicity did not significantly differ between low-dose weekly cisplatin and high-dose cisplatin (both given with RT).[287] Based on all of the available data, high-dose cisplatin with RT is the preferred systemic therapy/RT regimen for locally advanced SCCHN. However, if the clinician has a patient-specific concern about the toxicity of high-dose cisplatin, a weekly low-dose cisplatin regimen at a dose of 40 mg/m^2/week may be substituted. The categories of evidence for other perceived better tolerated systemic regimens are lower than for high-dose cisplatin. In the absence of confirmatory and mature prospective comparison trials, it is unclear whether low-dose weekly cisplatin is either less toxic or equally efficacious as high-dose cisplatin.

Epidermal growth factor receptor (EGFR) overexpression is common in SCCHN and is associated with poor survival outcomes.[288,289] Bonner et al randomly assigned 424 patients with locally advanced stage III–IV squamous cell carcinomas of the hypopharynx, oropharynx, and larynx to receive definitive RT with or without cetuximab.[290] Locoregional control and median OS (49 vs. 29.3 months; P = .03) were significantly improved in patients treated with RT and cetuximab compared to RT alone. Five-year OS was 45.6% in patients treated with RT and cetuximab and 36.4%

Discussion update in progress

Version 1.2026 © 2025 National Comprehensive Cancer Network© (NCCN©), All rights reserved. NCCN Guidelines® and this illustration may not be reproduced in any form without the express written permission of NCCN.

PLEASE NOTE that use of this NCCN Content is governed by the End-User License Agreement, and you MAY NOT distribute this Content or use it with any artificial intelligence model or tool.
Printed by Galya Basol Kochav on 1/4/2026 9:40:35 AM. Copyright © 2026 National Comprehensive Cancer Network, Inc. All Rights Reserved.

in patients who received RT alone (HR, 0.73; 95% CI, 0.56–0.95; *P* = .018).[291]

The randomized phase III RTOG 0522 trial showed that the addition of cetuximab to cisplatin and RT did not significantly improve OS, compared to cisplatin and RT, in patients with stage III or IV SCCHN and, importantly, was more toxic.[292] Long-term updates from the randomized phase III NRG/RTOG 0522 trial confirmed the original findings of no improvement in outcomes from the addition of cetuximab to cisplatin and RT.[293] At a median follow-up of 10.1 years, data showed that the addition of cetuximab did not reduce the incidence of locoregional failure or distant metastasis, or improve OS. No improvement in PFS was reported in those with oropharyngeal cancer, regardless of p-16 positivity, in the cetuximab arm. Consistent with the original data, rates of toxicity were higher in the cetuximab arm compared to the RT + cisplatin arm, at 61.3% and 57.4%, respectively. In the phase III GORTEC 2007-01 trial, cetuximab combined with carboplatin/5-FU and RT was compared to cetuximab and RT.[294] Three-year PFS (52.3% vs. 40.5%, respectively; HR, 0.73; 95% CI, 0.57–0.94; *P* = .015) and locoregional failure (21.6% vs. 38.8%, respectively; HR, 0.54; 95% CI, 0.38–0.76; *P* < .001) rates were better with the cetuximab and carboplatin/5-FU regimen, but OS and distant metastases rates were not significantly improved. Grade 3 or 4 mucositis (73% vs. 61%, respectively; *P* = .014) and hospitalization for toxicity (42% vs. 22%, respectively; *P* < .001) were more prevalent in patients who received cetuximab combined with carboplatin/5-FU and RT. Based on all of these data, cetuximab combined with chemoradiation is not recommended.

In three randomized phase III trials, cetuximab and RT was compared to cisplatin and RT as a deintensification treatment strategy for HPV-positive locally advanced oropharyngeal cancer. These trials showed that cetuximab and RT was inferior to cisplatin and RT (in terms of OS) and was not better tolerated.[295,296] In the RTOG 1016 trial, 849 patients with locally advanced HPV-positive oropharyngeal cancer were randomized to receive accelerated IMRT with either cetuximab or cisplatin.[295] After a median follow-up of 4.5 years, the cetuximab arm did not meet the criterion for noninferiority (based on 5-year OS). Five-year OS was 77.9% for the cetuximab arm and 84.6% for the cisplatin arm. PFS and risk of locoregional failure were significantly worse in the cetuximab arm compared to the cisplatin arm (HR, 1.72; 95% CI, 1.29–2.29; *P* < .001 for PFS; HR, 2.05; 95% CI, 1.35–3.10; *P* < .001 for locoregional failure). Five-year PFS and locoregional failure rates were 67.3% and 17.3% for the cetuximab arm and 78.4% and 9.9% for the cisplatin arm, respectively. In the randomized phase III De-ESCALaTE HPV trial, cetuximab and RT was compared to cisplatin and RT in 334 patients with locally advanced p16-positive oropharyngeal squamous cell carcinoma.[296] Patients given cisplatin and RT had significantly better 2-year OS (97.5% vs. 89.4%, respectively; HR, 5.0; 95% CI, 1.7–14.7; *P* = .001) and a lower recurrence rate (6.0% vs. 16.1%, respectively; HR, 3.4; 95% CI, 1.6–7.2; *P* < .001) compared to patients given cetuximab and RT. In the multicenter TROG 12.01 trial, 189 patients with intermediate-risk HPV-positive oropharyngeal cancer were randomized to receive 70 Gy RT with either low-dose weekly cisplatin (40 mg/m^2/week) or cetuximab.[297] The 3-year failure-free survival was 93% in the RT/cisplatin arm and 80% in the RT/cetuximab arm (*P* = .015). These three phase III trials demonstrated that cetuximab and RT was inferior to cisplatin and RT in patients with HPV-positive locally advanced oropharyngeal cancer.[295-297] When concurrent systemic therapy/RT is recommended for treatment of locoregionally advanced HPV-positive oropharyngeal cancer, the Panel asserts that high-dose cisplatin is the preferred systemic agent, although low-dose weekly cisplatin is also an option. An NRG trial is currently in progress for comparing high-dose cisplatin to low-dose weekly cisplatin in locally advanced SCCHN (NCT05050162).

Discussion update in progress

Version 1.2026 © 2025 National Comprehensive Cancer Network© (NCCN©), All rights reserved. NCCN Guidelines® and this illustration may not be reproduced in any form without the express written permission of NCCN.

PLEASE NOTE that use of this NCCN Content is governed by the End-User License Agreement, and you MAY NOT distribute this Content or use it with any artificial intelligence model or tool.
Printed by Galya Basol Kochav on 1/4/2026 9:40:35 AM. Copyright © 2026 National Comprehensive Cancer Network, Inc. All Rights Reserved.

Induction Chemotherapy

The role of induction chemotherapy in the management of locally advanced SCCHN has generated considerable discussion and debate within the NCCN Panel. The lack of consensus among NCCN Member Institutions despite the extensive discussion is illustrated by the category 3 recommendation (ie, major disagreement) for induction chemotherapy for the management of locoregionally advanced p16-negative and p16-positive oropharyngeal cancer. However in other sites of disease (glottic and supraglottic larynx and hypopharynx), category 2A and 2B recommendations for induction chemotherapy are based on an update from the RTOG 91-11 trial.[298] For selected patients with hypopharyngeal and laryngeal cancers (with less than T4a in extent, for which total laryngectomy is indicated), induction chemotherapy—used as part of a larynx preservation strategy—is listed as a category 2A designation.

Panel members feel that induction chemotherapy should only be administered at sites with expertise in these regimens because of challenges associated with appropriate patient selection and management of treatment-related toxicities.[299] Residual toxicity from induction chemotherapy may complicate the subsequent delivery of definitive RT or systemic therapy/RT.

A summary of the data helps provide perspective on the NCCN Panel's recommendations. Most randomized trials comparing induction chemotherapy followed by RT and/or surgery to locoregional treatment alone did not show an improvement in OS with the incorporation of induction chemotherapy.[284] However, in some studies, a lower rate of distant metastases was noted with induction chemotherapy.[300] Also, a correlation was noted between favorable tumor response to induction chemotherapy and durable disease control with subsequent RT.[300,301] Thus, the hypothesis was developed that induction chemotherapy could facilitate organ preservation, avoid morbid surgery, and improve QOL of patients although OS was not improved. Because total laryngectomy is among the procedures most feared by patients,[302] larynx preservation was the focus of initial studies of induction chemotherapy.

Two randomized studies—the Veterans Affairs (VA) Laryngeal Cancer Study Group trial in advanced larynx cancer and the EORTC trial in advanced hypopharynx cancer—established the role of induction cisplatin/5-FU followed by definitive RT in responding patients as an alternative treatment to total laryngectomy and postoperative RT, offering potential larynx preservation without compromise in OS (see *Cancer of the Larynx* and *Cancer of the Hypopharynx* in this Discussion).[300,301] Yet, even in this setting, the utilization of induction chemotherapy has decreased with time. Randomized trials and related meta-analyses indicated that concurrent systemic therapy/RT (with cisplatin being the best-studied agent) offered superior locoregional tumor control and OS compared to RT alone,[273,276-278,280,282,283,285,286] and shorter duration of therapy compared to induction therapy followed by radiation. Meta-analyses reported that concurrent systemic therapy/RT was more efficacious than an induction chemotherapy followed by definitive RT strategy.[284,303] In the larynx preservation setting, the Intergroup 91-11 trial compared RT alone, concurrent cisplatin/RT, and induction cisplatin/5-FU followed by RT; all arms offered surgery for locally relapsed/refractory disease. The concurrent cisplatin/RT arm had the highest larynx preservation rate (see *Cancer of the Larynx* in this Discussion).[304] Long-term follow-up of the 91-11 trial confirmed that concomitant systemic therapy/RT improved the larynx preservation rate and that induction chemotherapy followed by RT was not superior to RT alone.[298] However, OS did not differ among the three treatment arms.

Nonetheless, interest in the role of induction chemotherapy endured for several reasons. First, advances in surgery, RT, and concurrent systemic therapy/RT have yielded improvements in locoregional control; thus, the

Discussion update in progress

Version 1.2026 © 2025 National Comprehensive Cancer Network© (NCCN©), All rights reserved. NCCN Guidelines® and this illustration may not be reproduced in any form without the express written permission of NCCN.

PLEASE NOTE that use of this NCCN Content is governed by the End-User License Agreement, and you MAY NOT distribute this Content or use it with any artificial intelligence model or tool.
Printed by Galya Basol Kochav on 1/4/2026 9:40:35 AM. Copyright © 2026 National Comprehensive Cancer Network, Inc. All Rights Reserved.

role of distant metastases as a source of treatment failure has increased, and induction chemotherapy is a strategy that may reduce the risk of distant metastases.[305,306] Second, clinicians have increasing concern regarding the long-term morbidity of concurrent systemic therapy/RT, and thus have an interest in exploring alternative approaches that might have a more favorable long-term side effect profile.[307] Finally, a more effective triplet induction chemotherapy regimen was identified compared to the standard cisplatin/5-FU used in the induction trials of the 1980s and 1990s, and analyzed in the related meta-analyses. Three phase III trials compared induction cisplatin plus 5-FU with or without the addition of a taxane (docetaxel or paclitaxel) followed by the same locoregional treatment in both groups. Results showed significantly improved outcomes (response rates, DFS, or OS, depending on the trial) for patients in the three-drug induction group (taxane plus cisplatin and 5-FU) compared to those receiving two drugs (cisplatin plus 5-FU).[308-311] A randomized phase III trial in the larynx preservation setting similarly showed superior larynx preservation outcome with induction docetaxel/cisplatin/5-FU (TPF) compared to cisplatin/5-FU.[312,313] A meta-analysis including five RCTs (N = 1772) showed that the TPF induction chemotherapy regimen, compared to cisplatin plus 5-FU, was associated with reduced risk of death (HR, 0.72; 95% CI, 0.63–0.83; $P < .001$) and greater reductions in progression (HR, 0.78; 95% CI, 0.69–0.87; $P < .001$), locoregional failure (HR, 0.79; 95% CI, 0.66–0.94; $P = .007$), and distant failure (HR, 0.63; 95% CI, 0.45–0.89; $P = .009$).[314]

Whether adding induction chemotherapy to concurrent chemoradiation (versus RT alone) results in a clear advantage in OS continues is unclear.[315-317] Both the DeCIDE and the PARADIGM phase III trials did not show a survival advantage with the incorporation of induction chemotherapy followed by concurrent chemoradiation.[316,317] In patients with stage III or IV SCCHN, a randomized phase II study compared induction TPF followed by concurrent cisplatin/5-FU and RT versus concurrent cisplatin/5-FU and RT alone. A higher radiologic complete response rate was reported with the incorporation of induction chemotherapy.[318] Results from a larger follow-up study suggest a survival advantage.[319]

Other induction chemotherapy regimens have been evaluated in phase II trials. The ECOG-ACRIN trial (E2303) showed promising results in terms of primary site response and survival for cetuximab, paclitaxel, and carboplatin as induction chemotherapy, followed by concurrent systemic therapy/RT with the same drug regimen in patients with stage III or IV SCCHN (N = 74),[320] but the benefit of induction chemotherapy requires validation using a randomized design. Two phase II studies evaluated the feasibility of TPF with cetuximab followed by concurrent systemic therapy/RT or RT alone.[321,322] The DeLOS-II trial showed that TPF followed by RT, with cetuximab administered throughout, was feasible but not superior to TPF and subsequent RT without cetuximab.[321] An EORTC trial evaluating this induction regimen followed by concurrent systemic therapy/RT was stopped prematurely due to numerous serious adverse events.[322]

There is a lack of consensus regarding the most appropriate concurrent systemic therapy/RT regimen to be administered following induction chemotherapy.[323] Panel members agree that weekly carboplatin is a reasonable agent to use with RT.[316] Intent-to-treat analyses from the randomized phase II TREMPLIN study showed no significant difference in larynx preservation rate at 3 months in patients with locally advanced larynx or hypopharynx cancers who received either cisplatin (95%) or cetuximab (93%) with RT following induction TPF.[324] Although surgery for persistent disease was feasible only in patients who received cetuximab with RT following TPF, rate of treatment failure was lower in patients who received cisplatin with RT. Long-term results of this trial showed no significant differences between the study arms for 5-year OS, LRC, and

Discussion update in progress

Version 1.2026 © 2025 National Comprehensive Cancer Network© (NCCN©), All rights reserved. NCCN Guidelines® and this illustration may not be reproduced in any form without the express written permission of NCCN.

PLEASE NOTE that use of this NCCN Content is governed by the End-User License Agreement, and you MAY NOT distribute this Content or use it with any artificial intelligence model or tool.
Printed by Galya Basol Kochav on 1/4/2026 9:40:35 AM. Copyright © 2026 National Comprehensive Cancer Network, Inc. All Rights Reserved.

laryngo-esophageal dysfunction-free survival.[325] There were also no significant differences in toxicities, although late toxicities tended to be more common in the cetuximab arm, compared to the cisplatin arm (96.1% vs. 86.2% respectively; $P = .10$). A randomized phase III noninferiority trial showed no differences in PFS, overall response rates, or adverse event rates between cisplatin and cetuximab, delivered concurrently with RT following induction TPF.[326]

Results of the phase III GORTEC 2007-02 trial, in which 370 patients with bulky nodal disease (N2b, N2c, or N3) were randomized to receive carboplatin/5-FU with RT or TPF followed by cetuximab/RT, showed no significant differences between the study arms for survival outcomes and local control.[327] There was a trend towards a lower rate of distant metastases in the TPF arm (HR, 0.54; 95% CI, 0.30–0.99; $P = .05$).

The Panel recommends cetuximab administered concurrent with RT following induction chemotherapy only in select circumstances such as in patients who are cisplatin-ineligible. Low-dose weekly cisplatin with RT following induction chemotherapy is a category 2B option, based on extrapolation.[316,324] However, because of toxicity concerns, high-dose cisplatin (100 mg/m^2 every 21 days × 3 doses) is not recommended with RT after induction cisplatin-based chemotherapy.[315,324]

The data summarized in this section highlights overarching concerns that any efficacy gains of a strategy of induction chemotherapy followed by RT may be offset by the poorer patient adherence with the RT-based part of treatment and the alternative option of shorter duration, better-tolerated, and effective concurrent systemic therapy/RT regimens. Because of these uncertainties, enrollment of patients in appropriate clinical trials of induction chemotherapy is encouraged. Outside of a clinical trial, concurrent systemic therapy/RT—with high-dose cisplatin preferred—is considered the gold standard by many NCCN Panel Members (see *Principles of Systemic Therapy for Non-Nasopharyngeal Cancers* in the NCCN Guidelines for Head and Neck Cancers).[138-141,273,328] When induction chemotherapy is used, data show that the addition of a taxane to cisplatin/5-FU (of which TPF is the most extensively studied) is more efficacious than cisplatin/5-FU.[314,323] Therefore, when used as induction chemotherapy for SCCHN, docetaxel with cisplatin/5-FU is a category 1 preferred recommendation. Paclitaxel/cisplatin/5-FU and carboplatin/paclitaxel with or without cetuximab are also options for induction chemotherapy, though the latter option is category 2B based on less Panel consensus.[309,329-331]

Principles of Supportive Care

Nutrition

The *Principles of Nutrition: Management and Supportive Care* section in the NCCN Guidelines for Head and Neck Cancers outlines nutritional management and supportive care for patients with H&N cancers who are prone to weight loss, which can often be severe, as a result of treatment-related toxicity, disease, and health behaviors such as poor nutritional habits.[332,333] Patients with H&N cancers are also at risk for dehydration. The multidisciplinary expertise of a registered dietitian and a speech-language/swallowing therapist should be utilized throughout the continuum of care.

Patients who have had significant weight loss (5% body weight loss over 1 month, or 10% body weight loss over 6 months) need nutritional evaluation and close monitoring of their weight to prevent further weight loss.[334,335] In addition, all patients should receive nutritional evaluation before and after treatment to assess the need for interventions (eg, enteral support via feeding tubes).[336,337] Lymphedema of the head and neck commonly occurs in patients and is associated with increased symptom burden (eg, negative cosmetic impact, trouble breathing, swallow dysfunction, and pain).[338-340] Fibrosis can also occur.[341] As lymphedema and fibrosis negatively impact function and QOL, evaluation and

Discussion update in progress

Version 1.2026 © 2025 National Comprehensive Cancer Network© (NCCN©), All rights reserved. NCCN Guidelines® and this illustration may not be reproduced in any form without the express written permission of NCCN.

PLEASE NOTE that use of this NCCN Content is governed by the End-User License Agreement, and you MAY NOT distribute this Content or use it with any artificial intelligence model or tool.
Printed by Galya Basol Kochav on 1/4/2026 9:40:35 AM. Copyright © 2026 National Comprehensive Cancer Network, Inc. All Rights Reserved.

management is warranted. Patient referrals to occupational therapy to learn massage techniques (eg, lymphatic decompression therapy) or to be fitted for custom-made compression devices may be warranted. Patients are also at risk for problems with speech and/or swallowing. Treatment and/or the progression of their disease may cause deterioration in their ability to speak and/or swallow.[342-345] Evaluation by a speech-language/swallowing therapist is needed before, during, and after treatment to help mitigate potential problems.[346-348] Patients are also at risk for dental problems (see *Principles of Oral/Dental Evaluation and Management* in the NCCN Guidelines for Head and Neck Cancers). Long-term swallowing and dental dysfunction are particular risks that are worsened by multimodality therapy and require long-term specialized attention.

Oral mucositis, or tissue damage, is common in patients treated with RT for H&N cancers,[349-354] although use of advanced RT techniques (eg, IMRT) may decrease the incidence and duration of this damage.[349,355,356] Oral mucositis causes pain in the mouth, which may affect the ability to eat and drink.[349,352,353,357] Oral mucositis may be associated with breaks and/or delays in treatment, as well as hospitalization.[350,351,353] Oral mucositis is more severe in patients receiving concurrent systemic therapy/RT.[353] The Multinational Association of Supportive Care in Cancer and the International Society of Oral Oncology have published clinical practice guidelines for treatment of oral mucositis, although there are few high-quality studies in this area.[358,359] Prevention and management of mucositis constitute an unmet medical need.

In the randomized phase III Alliance A221304 trial, patients with H&N cancer who were treated with RT (N = 275) were randomized to receive a diphenhydramine-lidocaine-antacid mouthwash, doxepin mouthwash, or a placebo.[360] The reduction in mucositis pain during the first 4 hours of treatment was significantly greater in the patients who received the diphenhydramine-lidocaine-antacid mouthwash (P = .004) or the doxepin mouthwash (P = .02), compared to the placebo. The practicality and effectiveness of the doxepin-based regimen through an entire course of RT is not established. Gabapentin is also under investigation for treatment of pain from oral mucositis. In a prospective randomized pilot study, patients with H&N cancer who were treated with chemoradiation (N = 79) were randomized to receive gabapentin or usual care.[361] Patients randomized to receive gabapentin reported a greater reduction in pain, compared to patients randomized to receive usual care (P = .004). A small retrospective study including patients with H&N cancer treated with RT or systemic therapy/RT showed that treatment with gabapentin for pain from oral mucositis is associated with a reduced need for narcotic pain medication and high doses of opioids.[352] A single-institution study demonstrated that very-high-dose prophylactic gabapentin (2700 mg daily) also reduced the number of patients requiring narcotics.[362] An unplanned secondary analysis of two consecutive prospective clinical trials showed that high-dose prophylactic gabapentin (3600 mg daily) was associated with greater time to first use of opioids, compared to 900 mg daily (P < .001).[363] The toxicity of large dosages should not be underestimated and was not adequately explored in these studies. Larger scale studies are awaited to fully assess the generalizability and toxicity of this dosing schedule. In a randomized double-blind placebo-controlled study from China (N = 128), patients with RT-related neuropathic pain who received pregabalin reported greater pain relief (P = .006 for 30% pain relief and P = .003 for 50% pain relief) and greater pain intensity reduction (P = .003) than patients who received a placebo.[364] The Panel recommends consideration of doxepin, diphenhydramine-lidocaine-antacid mouthwash, pregabalin (category 2B), or gabapentin for pain related to oral mucositis, as clinically indicated and as tolerated.

NCCN Panel members agree that reactive feeding tube placement, in which patients are first given oral nutrition supplements, followed by

Discussion update in progress

Version 1.2026 © 2025 National Comprehensive Cancer Network© (NCCN©), All rights reserved. NCCN Guidelines® and this illustration may not be reproduced in any form without the express written permission of NCCN.

PLEASE NOTE that use of this NCCN Content is governed by the End-User License Agreement, and you MAY NOT distribute this Content or use it with any artificial intelligence model or tool.
Printed by Galya Basol Kochav on 1/4/2026 9:40:35 AM. Copyright © 2026 National Comprehensive Cancer Network, Inc. All Rights Reserved.

enteral feeding, when maintenance of nutritional requirements is no longer possible, is appropriate in selected patients with H&N cancers,[333] such as those in which tumors or mucositis interfere with swallowing function.[365] Reactive feeding tube placement should be considered if at least two of the following criteria are met: inability to maintain adequate intake (ie, <60% of estimated energy expenditure) for >10 days; >5% weight loss in a single month; severe mucositis, odynophagia, dysphagia, or aspiration; or older age (ie, >60 years).[366] A retrospective analysis including 100 patients treated with chemoradiation for advanced SCCHN showed that age >60 years was the most significant risk factor predicting need for enteral feeding (P = .003).[367]

There is no consensus about whether prophylactic tube placement is appropriate. Advantages of prophylactic tube placement include reductions in hospitalizations and treatment-related weight loss, as well as improved QOL.[368] However, this practice is also associated with disadvantages, such as longer dependence on feeding tubes and worse long-term functional outcomes, compared to a reactive approach.[368] The NCCN Guidelines provide recommendations for prophylactic tube placement, which should be strongly considered in high-risk patients (eg, those with severe pretreatment weight loss, ongoing dehydration or dysphagia, significant comorbidities, severe aspiration risk, anticipated swallowing issues).[333,335] In patients with adequate swallowing function, care must be given with the help of speech and language pathologists to ensure that patients continue to swallow to prevent severe fibrosis and permanent feeding tube dependence (see *Principles of Nutrition: Management and Supportive Care* in the NCCN Guidelines for Head and Neck Cancers). With swallowing therapy, adequate pain control, and access to IV fluids, feeding tubes can be avoided in most patients. The NCCN Guidelines do not recommend prophylactic tube placement in lower-risk patients (ie, those without significant pretreatment weight loss, significant aspiration, or severe dysphagia), although these patients' weights should be carefully monitored during and after treatment.

Oral/Dental Evaluation and Management

Patients with H&N cancers are at risk of oral and dental complications after surgery or RT because of treatment-induced xerostomia and salivary gland dysfunction, which are associated with increased dental caries.[345,349,353,369-373] In addition, RT to the salivary and oral soft tissues is also associated with bone demineralization and trismus of the masticatory muscles. Using IMRT and limiting the RT dose to the salivary glands and oral cavity have been shown to decrease xerostomia and damage to the teeth.[369,370,374-380] Dental/oral evaluation and management can help decrease dental caries and associated problems such as dentoalveolar infection and osteoradionecrosis.[349,353,373,374,380-389]

The recommended dental/oral evaluations before, during, and after RT are described in detail in the algorithm and are summarized here. A dental/oral treatment plan needs to be implemented before RT and should include the following: 1) eliminating potential sources of infection; 2) if performing dental extractions, allowing adequate time for healing before RT; 3) treating active dental caries and periodontal disease; 4) treating oral candidiasis; and 5) educating patients about preventive strategies, including the elimination of sugar-based candies or gum for dry mouth prevention.[373,390] Some of the general strategies to decrease oral and dental complications include: 1) decrease dry mouth (eg, by using salivary substitutes, stimulation with xylitol lozenges or discs that adhere to the gums, teeth or dentures, and the minimization of alcohol and caffeine consumption)[391-393]; 2) reduce risk of dental caries (eg, by using high-potency topical fluoride)[353,381,394]; 3) decrease dentoalveolar infection (eg, with frequent evaluations to detect and treat disease promptly); 4) prevent and address osteoradionecrosis; 5) decrease trismus of the masticatory muscles (eg, by using custom mouth-opening devices to maintain range of

Discussion update in progress

Version 1.2026 © 2025 National Comprehensive Cancer Network© (NCCN©), All rights reserved. NCCN Guidelines® and this illustration may not be reproduced in any form without the express written permission of NCCN.

PLEASE NOTE that use of this NCCN Content is governed by the End-User License Agreement, and you MAY NOT distribute this Content or use it with any artificial intelligence model or tool.
Printed by Galya Basol Kochav on 1/4/2026 9:40:35 AM. Copyright © 2026 National Comprehensive Cancer Network, Inc. All Rights Reserved.

motion)[395,396]; and 6) have patient undergo evaluations during and after treatment to help minimize complications.[373,391,392,397] Submandibular gland transfer is an approach that may be used in select circumstances to prevent xerostomia,[398] but the Panel does not endorse this approach due to lack of evidence and the availability of other options for xerostomia prevention and management. Major dental work such as extractions can be problematic for an irradiated mandible. Therefore, any planned procedures should be performed by dentists well-acquainted with this treatment setting and potential related morbidities, and in consultation with the treating radiation oncologist.

During and after treatment, the goals of dental/oral management include: 1) addressing xerostomia; 2) preventing trismus; and 3) detecting and treating oral candidiasis.[353,373,390] Additional goals after treatment include: 1) preventing and treating dental caries; 2) surveying the mouth for early signs of post-radiation osteonecrosis; and 3) preventing oral candidiasis.[353,373,390]

Cancer of the Oral Cavity (Including Mucosal Lip)

The oral cavity includes the buccal mucosa, upper and lower alveolar ridges, retromolar trigone, floor of mouth, hard palate, and the anterior two-thirds of the tongue. It has a rich lymphatic network, with initial regional spread typically occurring to lymph nodes in levels I through III. Regional node involvement at presentation is evident in approximately 30% of patients, but the risk varies by subsite. The risk of lymph node metastases is influenced by location, size, tumor thickness, depth of invasion, and tumor grade. For example, primaries of the alveolar ridge and hard palate rarely involve the neck, whereas occult neck metastasis is common (50%–60%) in patients with anterior (oral) tongue cancers. The incidence of lymph node metastases in cancer of the mucosal lip (especially early-stage lower lip) is historically low based on AJCC 7th edition staging,[399] averaging <10%, with higher rates seen in T3/4 disease or with oral commissure involvement. With depth of invasion now incorporated into T staging in the AJCC 8th edition,[400] indications for neck dissection in T2 mucosal lip lesions will likely require clarification. Specifically, early stage lesions with depth of invasion >10 mm would now be upstaged to T3.

Cancers of the lip mucosa are now staged as oral cavity cancers (see Table 1). The AJCC TNM staging system reflects tumor size, extension, and nodal disease.[400] In the 8th edition of the AJCC Cancer Staging Manual, cancers of the external vermilion lip are staged as cutaneous carcinomas of the H&N, due to their similarity to non-melanoma skin cancer.[400] For treatment guidance, see the NCCN Guidelines for Squamous Cell Skin Cancer (available at www.NCCN.org).

Workup

Imaging to assess mandibular involvement and regional nodal disease, along with a thorough dental evaluation is particularly important for staging (see Table 1) and treatment planning in oral cavity cancers. A complete H&N examination, biopsy, and other studies (see *Cancer of the Oral Cavity (Including Mucosal Lip): Workup* in the NCCN Guidelines for Head and Neck Cancers) are also recommended. For patients likely to receive RT (primary or adjuvant), pretreatment dental evaluation and ongoing dental care are critical to minimize the risk of osteoradionecrosis. Nutrition, speech, and swallowing evaluations are recommended for selected at-risk patients (see *Principles of Nutrition: Management and Supportive Care* in the NCCN Guidelines for Head and Neck Cancers).

Treatment

Treatment is based on clinical stage, patient medical status, anticipated functional and cosmetic outcomes, and patient preference. Surgery is the preferred approach for most oral cancers, except for early-stage mucosal

Discussion update in progress

Version 1.2026 © 2025 National Comprehensive Cancer Network© (NCCN©), All rights reserved. NCCN Guidelines® and this illustration may not be reproduced in any form without the express written permission of NCCN.

PLEASE NOTE that use of this NCCN Content is governed by the End-User License Agreement, and you MAY NOT distribute this Content or use it with any artificial intelligence model or tool.
Printed by Galya Basol Kochav on 1/4/2026 9:40:35 AM. Copyright © 2026 National Comprehensive Cancer Network, Inc. All Rights Reserved.

lip cancer where RT is equally effective. A nonsurgical approach may also be considered when surgical morbidity is high (eg, total glossectomy) or when the patient prefers organ preservation with systemic therapy and radiation. Postoperative radiation is recommended based on pathological findings and disease stage. Treatment decisions are informed by TN stage and the risk of nodal involvement in N0 disease (see *Cancer of the Oral Cavity (Including Mucosal Lip)* in the NCCN Guidelines for Head and Neck Cancers).

Multidisciplinary team involvement is essential for this site due to the impact on mastication, swallowing, and speech. Surgery is generally preferred for resectable tumors, even advanced ones, as functional outcomes are often favorable due to microvascular reconstruction techniques. Most small or superficial cancers can be treated surgically without significant functional or cosmetic issues. Thus, organ preservation via systemic therapy is less frequently pursued in the oral cavity, being considered generally less effective for locoregional control than upfront surgery. Definitive RT may be offered to patients who are medically inoperable, decline surgery,[401] or need local control in incurable cases.

For early-stage oral cavity cancers, the preferred initial treatment is surgical resection of the primary tumor. Most patients undergo ipsilateral or bilateral neck dissection, guided by factors such as depth of invasion, proximity to the midline, and tumor location (see *Head and Neck Surgery: Neck Dissection* above). Although the risk of occult metastasis to levels IV and V in squamous cell carcinoma of the oral cavity is low, study results are mixed. Therefore, the role of surgical resection with extended supraomohyoid neck dissection remains uncertain.[402] The benefit of elective neck dissection in early-stage, node-negative oral cavity cancers is debated and often based on the relative risk of occult metastasis from the subsite. A depth of invasion ≥4 mm is a key indication for elective neck dissection.[403]

A meta-analysis of five RCTs and 28 retrospective studies (n = 4366) showed that elective neck dissection should be considered in patients with T2 tumors (AJCC 7th edition),[399] due to the risk of occult nodal disease.[404] Patients with cT1–2, N0 disease who were observed had higher recurrence rates than those who had elective neck dissection (odds ratio [OR], 4.18; 95% CI, 2.78–6.28), though studies were heterogeneous.

A 2023 Cochrane review of 15 trials (n = 2583) evaluated surgical treatments for N0 oral/oropharyngeal cancers.[99] Five trials found that elective neck dissection improves OS versus therapeutic dissection (HR, 0.64; 95% CI, 0.50–0.83; moderate certainty). It also improved DFS and reduced locoregional recurrence. However, elective neck dissection was associated with more adverse events (relative risk [RR], 1.31; 95% CI, 1.11–1.54; moderate certainty). The review also found no significant differences in OS, DFS, or recurrence between SLNB and elective dissection.

Elective neck dissection in early-stage mucosal lip cancer remains controversial. Historically, it was reserved for T3 or T4 disease, prior to classification of mucosal lip as part of the oral cavity. While depth of invasion is a known risk factor for nodal spread in lip cancer, this has not been specifically examined in mucosal lip tumors.[405] Nonetheless, a depth >4 mm or T2 classification may justify elective dissection (supraomohyoid), with special attention to submental and perifacial nodes. SLNB may also be considered, as with other oral cavity sites.

SLNB can identify occult cervical metastases (see *Sentinel Lymph Node Biopsy* in NCCN Guidelines).[406-412] While early-stage lip cancers rarely have occult nodal disease, SLNB is feasible in patients at high risk based on tumor size and depth.[413-415] A systematic review of 98 studies showed sensitivity and specificity of 82.7% and 98.1%, respectively, for detecting cervical metastases in cT1–2 N0 cancers.[416] In a phase III multicenter RCT (n = 307), SLNB and elective neck dissection showed no significant

Discussion update in progress

Version 1.2026 © 2025 National Comprehensive Cancer Network© (NCCN©), All rights reserved. NCCN Guidelines® and this illustration may not be reproduced in any form without the express written permission of NCCN.

PLEASE NOTE that use of this NCCN Content is governed by the End-User License Agreement, and you MAY NOT distribute this Content or use it with any artificial intelligence model or tool.
Printed by Galya Basol Kochav on 1/4/2026 9:40:35 AM. Copyright © 2026 National Comprehensive Cancer Network, Inc. All Rights Reserved.

differences in recurrence-free survival, DSS, or OS.[417] A meta-analysis of 12 trials also found no differences in OS, DFS, or recurrence between SLNB and elective neck dissection, and confirmed SLNB's non-inferiority regarding DSS.[418] However, the evidence was of low quality, supporting the need for further RCTs. Results from an ongoing NRG trial (NCT04333537) may provide additional clarity. Although agents like technetium Tc99m tilmanocept have been evaluated for SLNB in oral [419,420]cancers,[419,420] the data are insufficient for the Panel to recommend a specific agent.

Postsurgical adjuvant treatment depends on the presence of adverse pathologic features. Positive or close margins and extranodal extension (ENE) are indications for systemic therapy with radiation. Perineural, vascular, and lymphatic invasion are less established indications but typically warrant adjuvant RT. Patients with ENE with or without positive mucosal margins should receive postoperative systemic therapy/RT (category 1). For close or positive margins, re-resection is preferred if feasible; otherwise, RT or systemic therapy/RT may be considered.

Surgery is preferred for locally advanced disease. For resected advanced-stage cancers with ENE and/or positive mucosal margins, systemic therapy/RT (category 1) is recommended.[138-141,143] Positive or close margins may also be managed with re-resection if feasible, though this is more complex following free flap reconstruction. EBRT should be considered; the role of brachytherapy remains underexplored (see *Radiation Therapy* below). For other high-risk features (eg, pT3/4, pN2/3, level IV/V nodes, perineural, vascular, or lymphatic invasion), RT alone is recommended, or systemic therapy/RT may be considered.

Radiation Therapy

For definitive RT in T1–2, N0 disease, doses to intermediate and low-risk sites range from 54 Gy (2.0 Gy/fraction) to 63 Gy (1.6 Gy/fraction) (see *Principles of Radiation Therapy* in NCCN Guidelines). Suspected subclinical disease sites may receive 54–60 Gy in sequential IMRT, or 54–63 Gy in IMRT with dose painting, depending on fraction size (1.6–1.8 Gy). Doses of 66–70 Gy are appropriate for high-risk disease.

RT may include EBRT with or without brachytherapy depending on tumor size. Brachytherapy should only be performed at experienced centers and may be appropriate in select cases (eg, close/positive margins after resection and flap reconstruction). While supportive data are limited, NCCN provides guidance on both low- and high-dose rate brachytherapy.[421,422]

Follow-up/Surveillance

Surveillance recommendations are provided in the algorithm (see *Follow-up Recommendations* in the NCCN Guidelines for Head and Neck Cancers).

Cancer of the Oropharynx

The oropharynx includes the base of the tongue, tonsils, soft palate, and pharyngeal wall. The oropharynx is extremely rich in lymphatics. Depending on the subsite involved, 15% to 75% of patients present with lymph node involvement. Oropharyngeal cancer that is p16-positive (ie, HPV-mediated) is a different disease than p16-negative cancer. To take into account these differences, separate staging criteria were published for p16-negative and p16-positive oropharyngeal cancer in the 8th edition of the AJCC Cancer Staging Manual.[400] In 2018, the Panel created separate algorithms for p16-positive (HPV-mediated) oropharyngeal cancer. See the section below on *Staging*.

Workup and Staging

A multidisciplinary consultation is encouraged including a registered dietitian and a speech-language/swallowing therapist as clinically indicated (see *Principles of Nutrition: Management and Supportive Care* in the

Discussion update in progress

Version 1.2026 © 2025 National Comprehensive Cancer Network© (NCCN©), All rights reserved. NCCN Guidelines® and this illustration may not be reproduced in any form without the express written permission of NCCN.

PLEASE NOTE that use of this NCCN Content is governed by the End-User License Agreement, and you MAY NOT distribute this Content or use it with any artificial intelligence model or tool.
Printed by Galya Basol Kochav on 1/4/2026 9:40:35 AM. Copyright © 2026 National Comprehensive Cancer Network, Inc. All Rights Reserved.

NCCN Guidelines for Head and Neck Cancers). Accurate staging (see Table 3 for p16-negative oropharyngeal cancer and Table 4 for p16-positive oropharyngeal cancer) depends on a complete H&N examination and appropriate imaging studies (see *Cancer of the Oropharynx: Workup* in NCCN Guidelines for Head and Neck Cancers).[400,423]

The Panel recommends examination under anesthesia (EUA) with biopsy confirmation for patients presenting with a p16-positive cervical lymph node prior to treatment decision-making. There may be situations in which the EUA is undesirable or could be bypassed. These include patients at high risk for general anesthesia and those who undergo a thorough examination including tongue base palpation, or those who require systemic therapy/RT and will not have their treatment plan affected, regardless of surgical evaluation. These situations remain the minority of cases.

Tumor HPV testing by use of surrogate p16 immunohistochemistry (IHC) is now required for cancers of the oropharynx because of the new AJCC 8th edition staging system[400] (see the following section on *HPV Testing*).

HPV Testing

p16 expression correlates with HPV status in geographic regions where HPV is etiologically responsible for a high proportion of cancers.[424,425] There are currently no diagnostic tests with regulatory approval. The NCCN Guidelines for Head and Neck Cancers recommend evaluation of tumor HPV status by use of a surrogate of p16 IHC in all patients diagnosed with an oropharyngeal cancer. Expression of p16 as detected by IHC is a widely available surrogate biomarker that has very good agreement with HPV status as determined by HPV E6/E7 mRNA expression.[42,424-427] Confirmatory HPV testing of tumor is recommended for clinical trials of HPV-targeted therapeutics or designed to test de-intensification strategies. Direct HPV confirmatory tests include polymerase chain reaction (PCR) and RNA or DNA in situ hybridization (ISH). The performance of various plasma cell-free HPV DNA detection assays (preferably validated per CLIA and CAP regulatory guidelines) for a diagnosis of HPV-positive oropharyngeal cancer against a gold standard of E6/E7 mRNA detection is unknown. Sensitivity and specificity against p16-IHC are approximately 90% and 94%, respectively.[428] At this time, persistent cell-free oncogenic HPV DNA detection in plasma (among those positive and quantifiable at diagnosis) may identify patients at increased risk for progression after completion of curative intent therapy.[429,430] However, without concurrent clinical, radiographic or pathological correlates represents an outcome without actionable therapeutic implications outside of clinical trials.

Analyses of HPV testing methods have shown that sensitivity and specificity of p16 IHC range from 94% to 97% and 83% to 84%, respectively, with sensitivity and specificity of HPV16 ISH ranging from 85% to 88% and 88% to 95%.[42,427] The reduced specificity for p16 IHC may be due to the presence of p16-positive tumors that do not have evidence of HPV DNA, while the reduced sensitivity for HPV16 ISH may be due to the presence of other high-risk HPV types in the tumor. PCR may provide additional sensitivity while ISH provides increased specificity.[9,424,427,431,432] PCR may also increase false positive rates from specimen contamination; for example, by a prevalent oral oncogenic infection unrelated to the cancer in approximately 13% of U.S. men who smoke. Sufficient pathologic material for HPV testing can be obtained by FNA.[9,433] Institutions should evaluate concordance between p16 and direct HPV testing, as this may vary by regions, particularly if considering use of p16 IHC alone as a surrogate. According to the guidelines for HPV testing published by the College of American Pathologists, when using p16, the 70% cutoff with nuclear and cytoplasmic expression with at least moderate to strong intensity if recommended; see these guidelines for additional information about HPV testing.[434] HPV testing may prompt questions

Discussion update in progress

Version 1.2026 © 2025 National Comprehensive Cancer Network© (NCCN©), All rights reserved. NCCN Guidelines® and this illustration may not be reproduced in any form without the express written permission of NCCN.

PLEASE NOTE that use of this NCCN Content is governed by the End-User License Agreement, and you MAY NOT distribute this Content or use it with any artificial intelligence model or tool.
Printed by Galya Basol Kochav on 1/4/2026 9:40:35 AM. Copyright © 2026 National Comprehensive Cancer Network, Inc. All Rights Reserved.

about prognosis and sexual history that the clinician should be prepared to address.

Staging

The algorithms for *Oropharyngeal Cancer* in the NCCN Guidelines for Head and Neck Cancers reflect the staging criteria published in the 8th edition of the AJCC Cancer Staging Manual for p16-negative oropharyngeal cancer and p16-positive oropharyngeal cancer.[400] In the staging criteria for p16-negative oropharyngeal cancer, separate pathologic criteria are now presented for involvement of regional lymph nodes, since extranodal extension is difficult to accurately capture through the imaging workup that is routinely done for clinical staging.[435] The treatment algorithm for p16-negative disease is divided into three staging categories: 1) cT1–2, cN0–1; 2) cT3–4a, cN0–1; and 3) cT1-4a, N2–3. Of note, the following categories are treated as advanced cancer: T4b, any N; unresectable nodal disease; unfit for surgery; or M1 disease at initial presentation (see *Very Advanced Head and Neck Cancer* in the NCCN Guidelines for Head and Neck Cancers).

A clinical staging system for p16-positive oropharyngeal cancer was developed using data from 1907 patients with non-metastatic HPV-positive oropharyngeal cancer from seven cancer centers in Europe and the United States.[436] OS did not significantly differ between T4a and T4b disease (P = .41). Therefore, these were collapsed into one T4 category. Five-year OS rates did not significantly differ in patients with N1, N2a, or N2b disease, based on the AJCC 7th edition N classification,[399] so the study investigators reasoned that these patients could be grouped into one category (ie, at least one ipsilateral metastatic node ≤6 cm).

An analysis of 704 patients with resected p16-positive oropharyngeal squamous cell carcinoma from five cancer centers showed that the N-classification system for oropharyngeal cancer that was described in the 7th edition of the AJCC Cancer Staging Manual[399] was not significantly associated with OS.[437] However, patients with four or fewer pathologically confirmed metastatic nodes had a higher 5-year OS rate, compared to patients with five or more pathologically confirmed metastatic nodes (89% vs. 71%, respectively).

The recommendations for p16 (HPV)-positive oropharyngeal cancer in the NCCN Guidelines for Head and Neck Cancers accommodate the AJCC 8th edition staging system for p16-positive oropharyngeal cancer.[400] However, differences in recommendations between p16-negative disease and p16-positive disease are relatively modest, since the staging system is based on prognostic models and is not based on prospective data from clinical trials that guide clinical decision-making. Based on differences in features associated with prognosis,[436,437] the staging criteria for p16-positive oropharyngeal cancer differs from staging for p16-negative oropharyngeal cancer in the following ways[400]:

- T4b disease has been removed from the staging criteria for defining the primary tumor.
- Criteria for defining nodal involvement (both clinical and pathologic) have been simplified for p16-positive disease. Clinical N staging for p16-positive oropharyngeal cancer is based on lymph node size and laterality, while pathologic N staging is based on number of lymph nodes. Further, pN3 disease has been removed for pathologic N.

The treatment algorithms for p16-positive disease have been divided by the Panel into four staging categories:

1) cT1–2, cN0
2) cT0–2, cN1 (single node ≤3 cm)
3) cT0–2, cN1 (single node >3 cm, or 2 or more ipsilateral nodes ≤6 cm); or cT0–2, cN2; or cT3, cN0–2
4) cT0–3, cN3 or cT4, cN0-3

Discussion update in progress

Version 1.2026 © 2025 National Comprehensive Cancer Network© (NCCN©), All rights reserved. NCCN Guidelines® and this illustration may not be reproduced in any form without the express written permission of NCCN.

PLEASE NOTE that use of this NCCN Content is governed by the End-User License Agreement, and you MAY NOT distribute this Content or use it with any artificial intelligence model or tool.
Printed by Galya Basol Kochav on 1/4/2026 9:40:35 AM. Copyright © 2026 National Comprehensive Cancer Network, Inc. All Rights Reserved.

The algorithms for p16 (HPV)-positive oropharyngeal cancer in the NCCN Guidelines for Head and Neck Cancers incorporate the staging criteria presented in the 8th Edition of the AJCC Cancer Staging Manual[400] based on clinical staging criteria. This is to acknowledge that decision-making continues to be frequently based on data from trials that included oropharyngeal as well as other anatomic sites that were staged utilizing AJCC 7th edition nodal staging criteria.[399]

Treatment

Expert consensus is that HPV status should be used as a stratification factor or should be addressed in separate trials (HPV-related vs. -unrelated disease) for which patients with oropharyngeal cancer are eligible.[438-440] With some exceptions, which are noted in this section below, the treatment algorithms for p16-negative and p16-positive oropharyngeal cancer are identical. There is currently no evidence that the staging criteria published in the 8th edition of the AJCC Cancer Staging Manual[400] should drive clinical decision-making, as it is currently unknown how to therapeutically address the vast biological differences between the two distinct cancers. Panel members urge that patients with HPV-positive cancers be enrolled in clinical trials evaluating biological and treatment-related questions.[441-443]

Some clinicians have suggested that less-intense treatment may be adequate for HPV-positive oropharyngeal cancers (ie, deintensification).[48] While not considered deintensification, other RT-based strategies that may be used to potentially minimize harm in patients with p16-positive oropharyngeal cancer include use of image-guided RT and consideration of unilateral neck irradiation in disease that is well-lateralized.[444] Available data supporting these assertions are limited by retrospective analyses, single-institution phase 3 trials, variability in HPV testing method used, and short follow-up periods.[48,442,445,446] Deintensification treatment protocols for HPV-positive locally advanced oropharyngeal cancer are being investigated in ongoing clinical trials. Strategies under active investigation include reducing or using biomarker or response-stratified RT dose or tumor hypoxia, using RT alone versus chemoradiation, using less invasive surgical procedures such as transoral laser microsurgery or TORS, using sequential systemic therapy/RT, and using immunotherapy.[442,444,447,448]

Early-stage (T1–2, N0–1 for p16-negative disease; T1–2, N0 or single node ≤3 cm for p16-positive disease) oropharyngeal cancers may be treated with definitive RT or resection of the primary with neck dissection.[116,119,449,450] Tumors at or approaching the midline (ie, tumors in the base of the tongue, posterior pharyngeal wall, soft palate, and tonsil invading the tongue base) are at risk of contralateral metastasis and warrant bilateral treatment. A staged contralateral neck dissection can be performed in order to avoid RT in patients with cT1–2 p16-negative oropharyngeal cancer if the primary tumors is near the midline and resected to adequate margins with no adverse pathologic features.

The randomized phase II ORATOR trial aimed to compare swallow-related QOL outcomes in patients with early-stage T1–T2, N0–2 oropharyngeal cancer treated with primary RT or systemic therapy/RT, versus those treated with TORS with neck dissection with or without adjuvant RT or systemic therapy/RT.[451] The study enrolled 68 patients from six hospitals in Canada and Australia (88% p16-positive), and compared MDADI scores between the two groups at 1 year. Swallow-related QOL outcomes reached statistical significance favoring the primary RT cohort; however, this difference did not meet criteria for a clinically meaningful change and with long-term follow-up, the difference in scores became less pronounced with the passage of time.[451,452] Study results showed that there were excellent and similar PFS and OS rates in both arms. The authors concluded that “RT- and TORS-based approaches were associated with clinically similar QOL outcomes, but differing spectra of toxicities, and differences in QOL between arms decreased over time. Clinicians and

Discussion update in progress

Version 1.2026 © 2025 National Comprehensive Cancer Network© (NCCN©), All rights reserved. NCCN Guidelines® and this illustration may not be reproduced in any form without the express written permission of NCCN.

PLEASE NOTE that use of this NCCN Content is governed by the End-User License Agreement, and you MAY NOT distribute this Content or use it with any artificial intelligence model or tool.
Printed by Galya Basol Kochav on 1/4/2026 9:40:35 AM. Copyright © 2026 National Comprehensive Cancer Network, Inc. All Rights Reserved.

patients should be involved in shared decision-making, in a multidisciplinary context, to individualize treatment of OPSCC."[452] The randomized open-label phase II ORATOR2 trial expanded upon the design of ORATOR and aimed to evaluate long-term survival, disease outcomes, and toxicities.[453] Patients with early-stage p16-positive T1–T2, N0–2 oropharyngeal cancer (N = 61) were randomized to receive primary RT (with concurrent weekly cisplatin if node-positive disease) or TORS with neck dissection (with adjuvant reduced-dose RT based on pathologic findings). Study accrual was halted early due to unacceptable grade 5 toxicities (two attributed to treatment) in the TORS arm. Results showed 2-year PFS and OS of 100% in the primary RT arm compared with 86% and 90%, respectively in the TORS arm, both significantly favoring primary RT.[454] Additional randomized trials of minimally invasive transoral surgery or RT for oropharyngeal cancer are ongoing (NCT02984410, NCT05144100).

Results from multiple phase II trials show that RT deintensification is associated with promising PFS rates in patients with p16-positive oropharyngeal cancer.[455-459] A phase II randomized trial of low-risk HPV-associated oropharyngeal cancer (≤10 pack years, T1–2 N1 or T3 N0–1) demonstrated that de-escalated RT to 60 Gy with concurrent cisplatin was associated with a 2-year PFS rate of 90.5%, and accelerated RT alone to 60 Gy was associated with a 2-year PFS rate of 87.6%.[460] A follow up phase II/III trial comparing 70 Gy with cisplatin, 60 Gy with cisplatin, or 60 Gy with nivolumab was stopped after phase II for futility, with preliminary results favoring 70 Gy with cisplatin, with a 2-year PFS of 98.1%, compared with 88.6% for 60 Gy with cisplatin, and 90.3% for 60 Gy with nivolumab.[461] A prospective phase II feasibility trial of initial TORS followed by risk-adapted adjuvant treatment demonstrated a 2-year PFS rate of 96.9% for low-risk disease with TORS alone, 94.9% for intermediate-risk disease with 50 Gy adjuvant RT, 96% for intermediate-risk disease with 60 Gy adjuvant RT, and 90.7% for high-risk disease with 66 Gy adjuvant RT with concurrent weekly cisplatin.[462]

Research on the impact of adverse pathologic features such as extranodal extension and number of involved nodes on outcomes in patients with p16-positive disease who have undergone resection is rapidly evolving. Analyses from the RTOG 9501[139] and EORTC 22931 trials,[138] prior to the era of p16/HPV testing, showed that extranodal extension is associated with poor prognosis and demonstrated benefit to adjuvant systemic therapy/RT in patients with locally advanced SCCHN who have undergone surgical resection.[140] Data suggesting equivalent outcomes of adjuvant RT and systemic therapy/RT for p16-positive oropharyngeal cancer with extranodal extension are restricted to retrospective trials,[45,438,463-468] although clinical trials are being conducted to validate the revised AJCC staging[400] for clinical decision-making. Secondary to lack of high-quality, prospective clinical evidence in the modern era, systemic therapy/RT is a category 2A option for both patients with p16-positive disease and p16-negative disease and extranodal extension. Adjuvant systemic therapy/RT remains a category 1 recommendation for patients with non-oropharyngeal SCCHN who have extranodal extension. Since patients with p16-positive oropharyngeal cancer have a generally favorable prognosis and may live longer, toxicity and QOL are concerns for these patients.[442,443] On the other hand, they are also younger, with fewer comorbidities, so they can probably tolerate combined adjuvant therapy better. Omitting systemic therapy and administering radiotherapy alone is a category 2B option for patients with p16-positive cT0–2, cN0–1 disease (single node ≤3 cm) who have extranodal extension following surgery. For patients with positive or close margins, re-resection (if feasible), RT, and systemic therapy/RT are treatment options.[156] For patients with other risk features such as pT3 or pT4 primary, one positive node >3 cm or multiple positive nodes, nodal disease in levels IV or V, perineural invasion, vascular invasion, or lymphatic invasion, adjuvant treatment options include RT or systemic

Discussion update in progress

Version 1.2026 © 2025 National Comprehensive Cancer Network© (NCCN©), All rights reserved. NCCN Guidelines® and this illustration may not be reproduced in any form without the express written permission of NCCN.

PLEASE NOTE that use of this NCCN Content is governed by the End-User License Agreement, and you MAY NOT distribute this Content or use it with any artificial intelligence model or tool.
Printed by Galya Basol Kochav on 1/4/2026 9:40:35 AM. Copyright © 2026 National Comprehensive Cancer Network, Inc. All Rights Reserved.

therapy/RT. If p16-positive disease, systemic therapy/RT in this setting is a category 2B option. If p16-negative disease that is pN1 following resection with no other adverse pathologic features present, RT may be considered.

Based on results from the phase III randomized GORTEC trial[186] and retrospective analyses from the National Cancer Database (NCDB),[469,470] systemic therapy/RT is a treatment option for patients with p16-negative N1 disease. However, this is a category 2B option, since the number of patients with T1–T2, N1 disease enrolled in the GORTEC trial is small, and more data from prospective trials are needed. For patients with p16-positive disease, systemic therapy/RT is also a category 2B option for T0–T2 disease and the involvement of a single node ≤3 cm.

For locally advanced resectable disease (T3–4a, N0–1, or N2–3 for p16-negative disease; T0–2, cN1 [single node >3 cm, or 2 or more ipsilateral nodes ≤6 cm] or N2, or T3, N0–3, or T4 for p16-positive disease), treatment recommendations include concurrent systemic therapy/RT[156,186] and resection of the primary and neck dissection (with appropriate adjuvant therapy [systemic therapy/RT or RT]), in addition to enrollment in clinical trials. As with early-stage disease, tumors at or approaching the midline should be strongly considered for bilateral treatment of the neck. The Panel asserts that concurrent systemic therapy/RT is preferred in patients with locoregionally advanced HPV-positive disease who have clinical evidence of fixed or matted nodes or obvious extranodal extension in patients, as surgery is not recommended for these patients.

Induction chemotherapy (followed by RT or systemic therapy/RT, though surgery may be an option in very select patients with disease that does not respond to induction chemotherapy) is listed as a treatment option for patients with locally advanced resectable oropharyngeal cancer regardless of p16 status,[116,119,471] but is a category 3 option due to lack of consensus among NCCN Member Institutions. Panel concerns are based on absence of benefit of induction chemotherapy in randomized clinical trials and concerns that use of better-tolerated—but potentially less effective—concurrent regimens or poorer patient adherence with RT may compromise outcomes (see *Induction Chemotherapy* in this Discussion, and *Cancer of the Oropharynx* in the NCCN Guidelines for Head and Neck Cancers). Patients with p16-positive cN2–3 disease who are treated with initial surgery have a high likelihood of extranodal extension, which warrants adjuvant systemic therapy/RT treatment. Triple modality management is associated with increased toxicity. Beginning treatment with concurrent systemic therapy/RT may help decrease the need for triple modality therapy and additional treatment-induced morbidity. Therefore, definitive concurrent systemic therapy/RT is preferred over upfront surgery for p16-positive cT4 or cN3 oropharyngeal cancer. Panel recommendations regarding adjuvant therapy for locally advanced disease do not differ between p16-positive and p16-negative oropharyngeal cancer.

Concurrent systemic therapy/RT—with high-dose cisplatin as the preferred systemic agent—is recommended for treatment of locoregionally advanced p16-positive and p16-negative cancer of the oropharynx (see *Principles of Systemic Therapy for Non-Nasopharyngeal Cancers* in the NCCN Guidelines for Head and Neck Cancers). Evidence from multiple prospective trials in HPV-positive oropharyngeal cancer demonstrates that cetuximab and RT is inferior to cisplatin (in terms of OS).[295,296]

Radiation Therapy Fractionation

IMRT is preferred for radiation treatment of oropharynx cancer, as it is associated with decreased toxicity.[472,473] There is an ongoing randomized trial comparing IMRT with IMPT in oropharyngeal cancer (NCT01893307). A fractionation schedule of 66–70 Gy at 2 Gy/fraction daily (Monday–Friday) for 6 to 7 weeks is recommended for patients with gross disease. Hypofractionation, hyperfractionation, or accelerated fractionation is

Discussion update in progress

Version 1.2026 © 2025 National Comprehensive Cancer Network© (NCCN©), All rights reserved. NCCN Guidelines® and this illustration may not be reproduced in any form without the express written permission of NCCN.

PLEASE NOTE that use of this NCCN Content is governed by the End-User License Agreement, and you MAY NOT distribute this Content or use it with any artificial intelligence model or tool.
Printed by Galya Basol Kochav on 1/4/2026 9:40:35 AM. Copyright © 2026 National Comprehensive Cancer Network, Inc. All Rights Reserved.

acceptable in patients with early-stage oropharyngeal cancer and may be associated with improved locoregional control.[156,162] For elective nodal treatment, a biologically equivalent dose of approximately 40–50 Gy in 2 Gy/fraction is recommended.[156,474] The complete list of recommended schedules for radiation treatment of p16-positive oropharynx cancer are shown in the algorithm (see *Cancer of the Oropharynx: Principles of Radiation Therapy* in the NCCN Guidelines for Head and Neck Cancers). Based on results from the prospective phase II ECOG-ACRIN Cancer Research Group trial (E3311), de-escalation to 50 Gy may be considered in patients with p16-positive oropharynx cancer who have up to 4 positive lymph nodes, AJCC 7th edition N1–2b disease with ≤1 mm ENE, and T1–2 resected to negative or close margins (<3 mm), but this is a category 2B option based on less Panel consensus.[462] Despite the evidence that RT dose deintensification may improve long-term function while preserving PFS in patients with p16-positive disease,[455-457,475] more studies are needed in this area. The majority of clinical trials in this space have been single-arm phase 2 and need to be compared to the standard of care in randomized trials.

Follow-up/Surveillance

Recommendations for surveillance are provided in the algorithm (see *Follow-up Recommendations* in the NCCN Guidelines for Head and Neck Cancers).

Cancer of the Hypopharynx

The hypopharynx extends from the superior border of the hyoid bone to the lower border of the cricoid cartilage and is essentially a muscular, lined tube extending from the oropharynx to the cervical esophagus. For staging purposes, the hypopharynx is divided into three areas: 1) the pyriform sinus (the most common site of cancer in the hypopharynx); 2) the posterior pharyngeal walls; and 3) the postcricoid area.

Workup and Staging

A multidisciplinary consultation is encouraged. Accurate staging (see Table 3) depends on a complete H&N examination coupled with appropriate studies (see *Cancer of the Hypopharynx: Workup* in the NCCN Guidelines for Head and Neck Cancers).[400] For patients with cancer of the hypopharynx, the prognosis can be poor despite aggressive combined modality treatment.

Treatment

Patients with resectable disease are divided into two groups based on the indicated surgical options: 1) those with early-stage cancer who are amenable to larynx-preserving (conservation) surgery (most T1, N0; selected T2, N0); and 2) those with advanced resectable cancer who require pharyngectomy with total or partial laryngectomy (T1–4a, any N). The surgery and RT options for the former group (see *Cancer of the Hypopharynx* in the NCCN Guidelines for Head and Neck Cancers) represent a consensus among the Panel members.

Patients with T1–3, any N disease, for whom the indicated surgical option is partial or total laryngopharyngectomy, may be managed with three approaches (see *Cancer of the Hypopharynx* in the NCCN Guidelines for Head and Neck Cancers) in addition to enrollment in clinical trials: 1) induction chemotherapy followed by additional treatment, depending on the response; 2) surgery with neck dissection(s), and postoperative RT or chemoradiation as dictated by pathologic risk features; or 3) concurrent systemic therapy/RT. When using concurrent systemic therapy/RT, the preferred systemic agent is high-dose cisplatin (category 1) (see *Principles of Systemic Therapy for Non-Nasopharyngeal Cancers* in the NCCN Guidelines for Head and Neck Cancers). Given the overall poor prognosis for advanced hypopharyngeal cancer, participation in clinical trials is encouraged.

Discussion update in progress

Version 1.2026 © 2025 National Comprehensive Cancer Network© (NCCN©), All rights reserved. NCCN Guidelines® and this illustration may not be reproduced in any form without the express written permission of NCCN.

PLEASE NOTE that use of this NCCN Content is governed by the End-User License Agreement, and you MAY NOT distribute this Content or use it with any artificial intelligence model or tool.
Printed by Galya Basol Kochav on 1/4/2026 9:40:35 AM. Copyright © 2026 National Comprehensive Cancer Network, Inc. All Rights Reserved.

The option of the induction chemotherapy/definitive RT is based on an EORTC randomized trial.[300] This trial enrolled 194 eligible patients with stage II–IV resectable squamous cell carcinoma of the pyriform sinus (152 patients) and aryepiglottic fold (42 patients), excluding patients with T1 or N2c disease. Patients were randomly assigned either to laryngopharyngectomy and postoperative RT, or to systemic therapy with cisplatin and 5-FU for a maximum of three cycles, followed by definitive RT. In contrast to a similar approach used for laryngeal cancer, a complete response to induction chemotherapy was required before proceeding with definitive RT. The published results showed equivalent survival, with median survival duration and a 3-year survival rate of 25 months and 43% (95% CI, 27%–59%), respectively, for the surgery group versus 44 months and 57% (95% CI, 42%–72%), respectively, for the induction chemotherapy group.[300] A functioning larynx was preserved in 42% of patients who did not undergo surgery. Local or regional failure rates did not differ between the patients treated with surgery and patients treated with chemotherapy, although the patients receiving chemotherapy showed a significant reduction in distant metastases as a site of first failure (P = .041).

For induction chemotherapy as part of a larynx preservation strategy, inclusion of only patients with the specified TNM stages is recommended. Success on larynx preservation with an induction chemotherapy strategy is best established for patients who had a complete response to induction therapy at the primary site and stable or improved disease in the neck. A randomized trial showed that an alternating regimen of cisplatin/5-FU with RT yielded larynx preservation, progression-free interval, and OS rates equivalent to those obtained with induction platinum/5-FU followed by RT.[476,477] However, a long-term update from this trial showed that larynx preservation rate was higher in patients who were randomized to receive the alternating regimen (32%), compared to patients who received the sequential regimen (25%).[477] Given available randomized data demonstrating the superiority of TPF compared with PF for induction chemoradiation, the triplet is now recommended as induction for this approach.[312,313]

As noted in the algorithm, surgery is recommended if a partial response or less occurs after induction chemotherapy (see *Cancer of the Hypopharynx* in the NCCN Guidelines for Head and Neck Cancers). The nature of the operation will depend on the stage and extent of the tumor at presentation. Partial laryngeal surgery may still be considered, although most patients will require total laryngectomy, and at least a partial pharyngectomy. In this situation, or when primary surgery is the selected management path, postoperative systemic therapy/RT is recommended (category 1) for the adverse pathologic features of extranodal extension and/or positive or close mucosal margin. For other risk features, clinical judgment should be used when deciding to use RT alone or when considering adding systemic therapy to RT (see *Cancer of the Hypopharynx* in the NCCN Guidelines for Head and Neck Cancers). Severe late toxicity appears to be associated with the amount of RT[307] and treatment with radiosensitizing systemic therapy.

Options for patients with T4a, any N disease include: 1) total laryngopharyngectomy plus neck dissection(s) followed by adjuvant systemic therapy/RT or RT; 2) enrollment in clinical trials; 3) induction chemotherapy (category 3); or 4) systemic therapy/RT (category 3) (see *Cancer of the Hypopharynx* in the NCCN Guidelines for Head and Neck Cancers, and *Primary Systemic Therapy with Concurrent RT* under *Systemic Therapy* in the Discussion).

Radiation Therapy Fractionation

Fractionation for RT is discussed in the algorithm (see *Cancer of the Hypopharynx: Principles of Radiation Therapy* in the NCCN Guidelines for Head and Neck Cancers).

Discussion update in progress

Version 1.2026 © 2025 National Comprehensive Cancer Network© (NCCN©), All rights reserved. NCCN Guidelines® and this illustration may not be reproduced in any form without the express written permission of NCCN.

PLEASE NOTE that use of this NCCN Content is governed by the End-User License Agreement, and you MAY NOT distribute this Content or use it with any artificial intelligence model or tool.
Printed by Galya Basol Kochav on 1/4/2026 9:40:35 AM. Copyright © 2026 National Comprehensive Cancer Network, Inc. All Rights Reserved.

Follow-up/Surveillance

Recommendations for surveillance are provided in the algorithm (see *Follow-up Recommendations* in the NCCN Guidelines for Head and Neck Cancers).

Cancer of the Nasopharynx

Nasopharyngeal carcinoma (NPC) is a relatively uncommon cancer, with an estimated 120,434 new cases and 73,482 deaths reported in 2022.[478] However, certain regions of the world are affected by endemic disease, with the highest global incidence rates occurring in Southeast Asia (particularly southern China), Micronesia/Polynesia, Eastern Asia, and North Africa.[478] The incidence rates are two to three times higher in men than in women.[479] Infection with the Epstein-Barr virus (EBV) is a key etiological factor in the development of NPC.[480,481] Among H&N cancers, endemic NPC has one of the highest tendencies to metastasize to distant sites, with approximately one in 10 patients presenting with distant metastases.[482] However, with the advent of modern radiotherapy techniques as part of the initial treatment, locoregional recurrences of endemic NPC have become uncommon, occurring in <10% of cases except in the most locally advanced patients.[483] The NCCN Guidelines for Head and Neck Cancers provide recommendations for the evaluation and management of NPC, addressing the risks of local, regional, and distant disease.

Workup and Staging

The workup of nasopharyngeal cancer includes a complete H&N examination and other studies (see *Cancer of the Nasopharynx* in the NCCN Guidelines for Head and Neck Cancers). These studies are important to determine the full extent of tumor to assign stage appropriately and to design radiation treatment volumes that will encompass all the disease with appropriate doses. Multidisciplinary consultation is encouraged. The 2017 AJCC staging classification (8th edition) is used as the basis for treatment recommendations (see Table 2).[400]

Epstein-Barr virus (EBV) DNA testing of plasma may also be considered (see *Epstein-Barr Virus*, below) although it has only prognostic, not predictive, value at present. HPV infection has been associated with NPC in case reports and very small case series, but the limited data regarding its impact on chemoradiation outcomes are conflicting.[484-486] In most of these reports, HPV-associated NPC appear to have better local control and survival prognosis than NPC that are neither EBV nor HPV associated ("double negative"). Therefore, while routine testing for HPV in NPC is not recommended by the NCCN Panel, it is recognized that the absence of HPV or EBV association is a highly negative prognostic factor.

Epstein-Barr Virus

Infection with EBV is an etiologic factor in the development of NPC.[480,481] Workup for NPC may include EBV testing of the tumor itself and, in some cases, plasma EBV DNA, particularly in the presence of nonkeratinizing and undifferentiated histology.[487-489] Testing methods for detection of EBV in tumor include ISH for EBV-encoded RNA (EBER)[490] and IHC staining for LMP1.[491] ISH for EBER tends to be a more sensitive testing method for carcinomas, relative to LMP1 IHC staining.[492] Real-time PCR may be used to evaluate EBV DNA titers in serum or plasma.[493] Sensitivity and specificity values range from 53% to 96%, and 88% to 100%, respectively.[494] Levels of plasma EBV DNA have been shown to be independently prognostic at baseline and following definitive chemoradiation. After induction chemotherapy, and after radiation, plasma EBV DNA levels are used in some centers as a means of outcome prognostication and residual disease monitoring.[495-498] It should be noted as an important caveat that lack of harmonization of plasma EBV DNA assays has hampered development of consensus recommendations and incorporation into prognostic models.[493] For patients with locoregionally

Discussion update in progress

Version 1.2026 © 2025 National Comprehensive Cancer Network© (NCCN©), All rights reserved. NCCN Guidelines® and this illustration may not be reproduced in any form without the express written permission of NCCN.

PLEASE NOTE that use of this NCCN Content is governed by the End-User License Agreement, and you MAY NOT distribute this Content or use it with any artificial intelligence model or tool.
Printed by Galya Basol Kochav on 1/4/2026 9:40:35 AM. Copyright © 2026 National Comprehensive Cancer Network, Inc. All Rights Reserved.

confined NPC, studies have shown that high initial levels of plasma EBV DNA, or persistently elevated levels near or at the end of induction chemotherapy or definitive intent RT or chemoradiation, are associated with a significantly poorer outcome.[499-504] A meta-analysis including 13 studies showed that plasma EBV DNA levels assessed pre-treatment were independent prognostic factors for mortality (HR, 2.81; 95% CI, 2.44–3.24; $P < .001$) and distant metastasis (HR, 3.89; 95% CI, 3.39–4.47; $P < .001$), although these studies were significantly heterogeneous ($P = .03$).[505] Plasma EBV DNA has also been studied as an indicator of disease response to chemotherapy or chemoradiation prior to additional treatment[506-508] and in patients with distant metastases and with disease that is treatment-refractory.[509,510] Studies have incorporated plasma EBV DNA to assign patients to different post radiation adjuvant therapies, but this approach has yet to be validated in clinical trial results (eg, NCT02135042). Most of these studies have been based on real-time PCR assays amplifying the *BamHI-W* fragment.

Treatment

The most recent clinical trial data on the treatment of NPC are limited to EBV-associated disease. Prospective studies that include patients with EBV-negative disease are largely lacking, or are only represented as non-prospectively defined subsets, primarily in studies conducted in the United States before the routine use of EBV testing for eligibility and monitoring in NPC clinical trials.[511]

Early-Stage and Locoregionally Advanced Disease

The Intergroup trial 0099, which randomly assigned patients to EBRT with concurrent cisplatin plus adjuvant chemotherapy with cisplatin and 5-fluorouracil (PF) for three cycles versus EBRT alone (patients not separated by EBV status), closed early when an interim analysis disclosed a highly significant survival advantage favoring the combined chemotherapy and radiation group.[328] The addition of chemotherapy also decreased local, regional, and distant recurrence rates. This study was conducted in the United States, and subsequent phase 3 randomized trials in Asia confirmed that concurrent chemoradiation without adjuvant PF similarly increased survival in endemic-area populations when compared with RT alone.[512-515] In one of these trials, 5-year OS was 70% for the chemoradiation group versus 59% for the RT group.[512] A randomized study conducted in Singapore, which was modeled after the Intergroup 0099 treatment regimen, confirmed the benefit of adding concurrent platinum to RT with adjuvant PF, using a multiday infusion of platinum instead of a single bolus high-dose approach.[514] One of the largest phase 3 randomized trials ever conducted in NPC comparing concurrent cisplatin/RT with (or without) adjuvant PF showed that adjuvant chemotherapy did not significantly improve survival following chemoradiation (HR, 0.74; 95% CI, 0.49–1.10; $P = .13$).[516]

Advanced radiation techniques are recommended for curative-intent treatment of NPC and to minimize the long-term side effects that are common in survivors. IMRT is now preferred due to its ability to encompass all areas of cancer spread, which can be located in close proximity to the brainstem, temporal lobes, cochleae, and optic nerves and chiasm. Randomized trials evaluating the optimal use of concurrent systemic therapy/RT for locoregionally advanced NPC were largely completed prior to the routine practice of IMRT, under earlier-era staging systems. Meta-analyses published in 2017 and 2018 showed that the addition of chemotherapy to IMRT did not improve survival outcomes in stage II disease (ie, T0–2, N1 and T2, N0), compared to IMRT alone.[517-519] A multicenter randomized phase 2 trial from China also showed that the addition of concurrent chemotherapy to IMRT did not significantly improve survival outcomes or disease control in patients with stage II NPC (N = 84).[520] The combined treatment was also associated with increased incidence of leukopenia ($P = .022$). Another multicenter randomized phase 2 trial from China, which also evaluated the addition of concurrent

Discussion update in progress

Version 1.2026 © 2025 National Comprehensive Cancer Network© (NCCN©), All rights reserved. NCCN Guidelines® and this illustration may not be reproduced in any form without the express written permission of NCCN.

PLEASE NOTE that use of this NCCN Content is governed by the End-User License Agreement, and you MAY NOT distribute this Content or use it with any artificial intelligence model or tool.
Printed by Galya Basol Kochav on 1/4/2026 9:40:35 AM. Copyright © 2026 National Comprehensive Cancer Network, Inc. All Rights Reserved.

chemotherapy to IMRT, showed that IMRT alone was noninferior to IMRT with concurrent cisplatin in 341 patients with T3, N0 disease and no adverse features (all nodes <3 cm, no involvement of level IV/IVb nodes, no ENE, and EBV DNA <4000 copies/mL).[521] However, as this was a single phase 2 study powered based on a 10% noninferiority margin, many practitioners continue to use chemoradiation for T3, N0, M0 disease.

An individual patient data meta-analysis by Blanchard et al,[522] which included 19 trials and 4806 patients with non-metastatic NPC, showed that both adjuvant chemotherapy following chemoradiation and chemoradiation without adjuvant chemotherapy were associated with better OS (HR, 0.65; 95% CI, 0.56–0.76 and HR, 0.80; 95% CI, 0.70–0.93, respectively) and PFS (HR, 0.62; 95% CI, 0.53–0.72 and HR, 0.81; 95% CI, 0.71–0.92, respectively) than radiation without concurrent systemic therapy. However, differences between the included studies assessing chemoradiation with and without adjuvant chemotherapy (eg, different length of follow-up, fewer patients with stage II disease in trials assessing adjuvant chemotherapy) limited the ability to make a firm conclusion regarding the efficacy of one treatment modality over the other. The NRG-HN001 trial (NCT02135042), a phase 2/3 study, aimed to investigate whether delivery of adjuvant chemotherapy should be eliminated or intensified based on the status of EBV DNA plasma levels after chemoradiation. This trial was closed slightly prematurely due to slowing accrual; as of March 2024, insufficient events had occurred to evaluate the value of the post radiation serum EBV DNA level as a biomarker for adjuvant treatment decision-making.

There is substantial evidence supporting the use of induction chemotherapy followed by concurrent systemic therapy/RT for treatment of locoregionally advanced nasopharyngeal cancer. Two randomized phase 3 trials from China published in 2019 show a survival benefit for induction chemotherapy followed by concurrent systemic therapy/RT, compared to concurrent systemic therapy/RT alone.[523,524] Results from multiple systematic reviews suggest that induction chemotherapy prior to systemic therapy/RT in patients with locally advanced NPC may potentially impact tumor control, compared to systemic therapy/RT without additional chemotherapy.[525-528] However, these reviews had inconsistent results when evaluating the impact on survival. Based on comparisons with systemic therapy/RT alone, induction chemotherapy appears to perform better than adjuvant chemotherapy for some outcomes, such as in reduction of distant metastases.[529]

Currently available evidence generally favors the addition of induction chemotherapy to concurrent systemic therapy/RT in patients with locoregionally advanced NPC defined as T stage T3 or greater or N stage N2 or greater.[525-528,530] A 2017 network meta-analysis based on an individual patient data meta-analysis (including 20 trials and 5144 patients) showed that the addition of adjuvant chemotherapy to chemoradiation was associated with better PFS (HR, 0.81; 95% CI, 0.66–0.98), compared to chemoradiation only.[525] The authors argued that more chemotherapy, in addition to concurrent chemoradiation, could reduce recurrence rates. A 2023 update to this meta-analysis, which included 28 trials and 8214 patients, continued to show that both induction chemotherapy and adjuvant chemotherapy were superior to systemic therapy/RT alone, but induction chemotherapy was associated with greater benefit for distant progression (HR, 0.66; 95% CI, 0.47–0.93 and HR, 0.65; 95% CI, 0.53–0.80 for induction chemotherapy with and without taxanes, respectively).[530] A 2017 meta-analysis including 27 trials with 7940 patients showed that induction chemotherapy prior to systemic therapy/IMRT ranked best for OS, PFS, and distant failure-free survival, although head-to-head comparisons with other treatment sequences (10 evaluated, including systemic therapy/RT, induction chemotherapy prior to systemic therapy/RT, and systemic therapy/RT followed by adjuvant chemotherapy, all with IMRT or 2D/3D RT) were not performed.[531] A randomized phase 3

Discussion update in progress

Version 1.2026 © 2025 National Comprehensive Cancer Network© (NCCN©), All rights reserved. NCCN Guidelines® and this illustration may not be reproduced in any form without the express written permission of NCCN.

PLEASE NOTE that use of this NCCN Content is governed by the End-User License Agreement, and you MAY NOT distribute this Content or use it with any artificial intelligence model or tool.
Printed by Galya Basol Kochav on 1/4/2026 9:40:35 AM. Copyright © 2026 National Comprehensive Cancer Network, Inc. All Rights Reserved.

trial from the Hong Kong Nasopharyngeal Cancer Study Group showed a survival benefit when comparing induction chemotherapy prior to systemic therapy/RT to systemic therapy/RT followed by adjuvant chemotherapy (cisplatin/5-FU), regardless of the induction regimen used (either PF or cisplatin/capecitabine).[532] The induction chemotherapy sequence was also associated with better distant control, compared to the adjuvant chemotherapy arm. However, this study was underpowered, due to the small number of patients in each study arm. Based upon the aggregate data, the NCCN Guidelines support the use of induction over adjuvant chemotherapy in patients with locoregionally advanced NPC. A randomized noninferiority phase 3 trial including 383 patients with locoregionally advanced NPC showed that, following induction using three cycles of dose-modified TPF (docetaxel 60 mg/m^2, cisplatin 60 mg/m^2, 5-FU 3000 mg/m^2), RT without low-dose concomitant cisplatin (30 mg/m^2/week) was noninferior to RT with concomitant cisplatin for 3-year PFS (76.2% vs. 76.8%, respectively; HR, 0.92; 95% CI, 0.65–1.32; P = .66).[533] Grade 3 or 4 adverse events were reported more frequently in the patients who received RT with concomitant cisplatin (73%), compared to patients who received RT alone (54%). The challenge of this study is that dose-modified TPF is less widely used than gemcitabine plus cisplatin(GC) as induction, and the doses of concurrent weekly cisplatin used were lower than the standard, which is 40 mg/m^2/week or 100 mg/m^2 every 21 days. Therefore, these data have not changed recommendations concerning the use of concurrent cisplatin following induction chemotherapy in this setting.

Three trials have reported on the adjuvant use of capecitabine following standard chemoradiation of locoregionally advanced NPC, with improvements in survival outcomes reported.[534-536] The vast majority of patients treated on the low dose metronomic adjuvant capecitabine study had received both induction chemotherapy and concurrent chemoradiation, supporting this adjuvant approach even in patients heavily pretreated with sequential chemoradiation.[536]

In summary, currently available evidence favors either the addition of induction or adjuvant chemotherapy to concurrent systemic therapy/RT, compared to systemic therapy/RT alone, in patients with locoregionally advanced NPC. Evidence suggests that induction chemotherapy may be associated with a greater benefit for distant progression, and this is the preferred approach in the NCCN Guidelines for locally advanced NPC. The routine use of adjuvant capecitabine following either induction and chemoradiation or chemoradiation alone is less established. Due to concerns about escalating toxicity, ongoing investigations continue with the goal of more precisely delineating which classes of NPC patients may be safely offered lesser-intensity regimens.

While there have been several trials studying the addition of immune checkpoint inhibitors to sequential chemoradiation in patients with locoregionally advanced NPC, none of these trials have yet to demonstrate an overall survival advantage.[537,538] Therefore, it is premature to consider the addition of checkpoint inhibitor therapy for these patients.

NCCN Recommendations

Patients with an unknown primary site after appropriate workup but harboring cervical lymph nodal squamous cell carcinoma that is EBV-positive may be treated in the same manner as locoregionally advanced NPC. For other EBV-associated NPC, the principles of treatment can mostly be outlined according to stage. Patients with T1, N0, M0 nasopharyngeal tumors should be treated with definitive RT alone. Since T2, N0 disease is less likely to progress to distant metastasis compared to T2, N1 disease, definitive RT alone could be used; concurrent systemic therapy may be indicated in the presence of high-risk features such as bulky tumor volume or high serum EBV DNA copy number.[539,540] Induction chemotherapy followed by systemic therapy/RT is preferred for advanced

Discussion update in progress

Version 1.2026 © 2025 National Comprehensive Cancer Network© (NCCN©), All rights reserved. NCCN Guidelines® and this illustration may not be reproduced in any form without the express written permission of NCCN.

PLEASE NOTE that use of this NCCN Content is governed by the End-User License Agreement, and you MAY NOT distribute this Content or use it with any artificial intelligence model or tool.
Printed by Galya Basol Kochav on 1/4/2026 9:40:35 AM. Copyright © 2026 National Comprehensive Cancer Network, Inc. All Rights Reserved.

locoregional disease (ie, T3, N1–N3; T4, N0–3; or T0–2, N2–3 disease). For patients who did not receive induction chemotherapy, adjuvant chemotherapy following treatment with concurrent systemic therapy/RT is recommended. The use of capecitabine as adjuvant treatment following induction and concurrent chemoradiation is supported by current evidence.[536] Concurrent systemic therapy/RT alone is recommended for patients with T0–2, N1 disease and can be considered for select patients with lower risk T3, N0 disease, who were excluded from randomized trials evaluating the benefits of adjuvant and induction chemotherapy.[516,523,524,541] Induction or adjuvant chemotherapy may be considered for these patients in the presence of high-risk features, including, for example, a high blood EBV DNA level, which may indicate worse prognosis. The recommended use of blood EBV DNA levels is complicated by lack of standardization and harmonization of these assays, so the NCCN Panel is unable to recommend specific quantitative guidance concerning their interpretation. For NPC that is not virally driven, similar principles are applied, although it may be a consideration that these tumors are generally more prone to local relapse and have lower rates of distant metastases.

When induction chemotherapy is used, gemcitabine/cisplatin[524,542] and modified TPF[541] are both preferred options for patients with EBV-related NPC. Other induction/sequential chemotherapy regimens are included in the NCCN Guidelines for Head and Neck Cancers based on lower-level evidence. The use of induction for patients with non–EBV-related NPC remains undefined, as all trials studying induction in NPC were in EBV-related NPC patient populations. When using induction chemotherapy for non–EBV-related NPC, it may be equally reasonable to use regimens established in other non–EBV-related SCCHN sites, such as TPF.

The Panel recommends concurrent systemic therapy/RT (cisplatin) with either induction or adjuvant chemotherapy for locoregionally advanced NPC, favoring induction over adjuvant in the clinical scenarios discussed above. Concurrent cisplatin with RT is recommended for all patients who do not have a contraindication to the drug, because the vast majority of randomized trials support the use of cisplatin in this setting.[328,512] If using adjuvant chemotherapy, the preferred option remains cisplatin/5-FU. Use of metronomic capecitabine as an adjuvant chemotherapy option for treatment of stage III–IVa disease (excluding T3–4, N0 and T3, N1) is supported by two randomized phase 3 trials (discussed above). The substitution of carboplatin or other platinum substitutes for cisplatin in induction, concurrent, and adjuvant regimens, while studied to some extent,[543-545] should be limited to patients who are cisplatin-ineligible.

Metastatic Disease

Population-based data appear to support the role of earlier RT in the management of metastatic nasopharyngeal cancer,[546] but treatment ultimately depends on whether the disease is localized or widespread and if it is symptomatic or posing a clinical risk to the patient.[328,512,543] For patients with oligometastatic disease, potentially curative therapy (ie, RT alone or surgery) is indicated if the patient is fit (ECOG 0–1); this locoregionally-focused approach is often used following robust anti-tumor effects observed with systemic chemotherapy.[547,548]

In a multicenter randomized phase 3 trial, patients (N = 126) with de novo metastatic nasopharyngeal cancer who achieved a complete response or partial response after the first 3 cycles of cisplatin/5-FU and with good PS were randomized to receive or not receive consolidative locoregional IMRT directed at the primary and nodal gross disease to total doses of 70 Gy after completion of 6 planned cycles.[549] The IMRT arm was associated with improved 24-month OS (76.4% vs. 54.5%) and PFS compared to chemotherapy alone. Based on the results of this study, RT at a definitive dose level to the primary site and involved regional nodes is recommended for patients with oligometastatic NPC if complete response

Discussion update in progress

Version 1.2026 © 2025 National Comprehensive Cancer Network© (NCCN©), All rights reserved. NCCN Guidelines® and this illustration may not be reproduced in any form without the express written permission of NCCN.

PLEASE NOTE that use of this NCCN Content is governed by the End-User License Agreement, and you MAY NOT distribute this Content or use it with any artificial intelligence model or tool.
Printed by Galya Basol Kochav on 1/4/2026 9:40:35 AM. Copyright © 2026 National Comprehensive Cancer Network, Inc. All Rights Reserved.

(or near complete response) is achieved with systemic therapy. However, it should be noted that the role of consolidative radiation has yet to be completely established in the current era where immunochemotherapy has now become the recommended initial treatment in the first-line metastatic setting.

In a randomized phase 3 trial evaluating the efficacy and safety of maintenance capecitabine following induction chemotherapy in 104 patients with newly diagnosed metastatic NPC, median PFS was greater in patients who received maintenance capecitabine, compared to patients who received best supportive care alone (35.9 months vs. 8.2 months, respectively).[535] Objective response rate (25.0% vs. 11.5%, respectively) and median duration of response (40.0 months vs. 13.2 months, respectively) both favored the maintenance capecitabine arm as well, compared to best supportive care alone. Based on study results, maintenance capecitabine without concurrent RT following induction chemotherapy is an option for patients with M1 oligometastatic disease (PS 0–1 only).

Gemcitabine plus cisplatin (GC) is recommended for first-line therapy for patients with metastatic NPC based on category 1 level evidence demonstrating a survival advantage over PF.[550,551] See discussion of immunotherapy below. Because the data for GC demonstrating superiority to PF comes from an era when GC was not typically used for induction, the superiority of GC over PF in patients who have had prior exposure to GC is unknown. Other combination regimens for these patients include cisplatin or carboplatin, plus a taxane[552,553]; cisplatin/5-FU[553,554]; gemcitabine/carboplatin[555]; or carboplatin/cetuximab.[555] Results from a comparison of five different cisplatin-based regimens for NPC showed that all had substantial anti-cancer activity.[556] Active and more commonly used single agents are listed in the algorithm (see *Systemic Therapy for Nasopharyngeal Cancers* in the NCCN Guidelines for Head and Neck Cancers).[554,557-568]

Toripalimab-tpzi, in combination with GC, is a category 1 preferred option in the NCCN Guidelines for first-line treatment of recurrent or metastatic NPC. Toripalimab, in combination with GC, was evaluated as a first-line therapy option for recurrent or metastatic NPC in the randomized phase 3 JUPITER-02 trial.[569] Patients from China, Taiwan, and Singapore (N = 289) were randomized to receive toripalimab or a placebo. PFS (HR, 0.52) and OS (HR, 0.63) were both significantly greater in the toripalimab arm (median PFS, 21.4 months, median OS not reached) compared to the placebo arm (median PFS, 8.2 months, median OS, 33.7 months). Adverse events leading to discontinuation of toripalimab or placebo, immune-related adverse events, and grade 3 or greater immune-related adverse events were more frequently reported in the toripalimab arm, although overall incidence of adverse events, grade 3 or greater adverse events, and fatal adverse events did not significantly differ between the two study arms. In addition, toripalimab monotherapy for recurrent or metastatic NPC previously treated with chemotherapy is supported by a nonrandomized phase 2 study from China (N = 190), showing an overall response rate (ORR) of 20.5%, median DOR 12.8 months, median PFS 1.9 months, and median OS 17.4 months.[570] Toripalimab-tpzi is therefore a preferred option in the NCCN Guidelines for recurrent or metastatic NPC, for disease progression on or after platinum-containing therapy.

Tislelizumab, in combination with GC, was evaluated as a first-line therapy option for recurrent or metastatic NPC in the randomized phase 3 RATIONALE-309 trial.[537] Patients from China (N = 263) were randomized to receive tislelizumab or a placebo. Interim analyses showed that PFS was significantly greater in the tislelizumab arm compared to the placebo arm (9.2 months vs. 7.4 months, respectively; HR, 0.52). A phase 2 indication-expansion study from China including 21

Discussion update in progress

Version 1.2026 © 2025 National Comprehensive Cancer Network© (NCCN©), All rights reserved. NCCN Guidelines® and this illustration may not be reproduced in any form without the express written permission of NCCN.

PLEASE NOTE that use of this NCCN Content is governed by the End-User License Agreement, and you MAY NOT distribute this Content or use it with any artificial intelligence model or tool.
Printed by Galya Basol Kochav on 1/4/2026 9:40:35 AM. Copyright © 2026 National Comprehensive Cancer Network, Inc. All Rights Reserved.

patients with nonkeratinizing NPC that progressed following prior systemic therapy treatment showed an ORR of 43% (95% CI, 21.8%–66.0%), a disease control rate of 86% (95% CI, 63.7%–97.0%), median duration of response of 8.3 months, and median PFS of 10.4 months.[571] Based on the results of these trials, tislelizumab-jsgr is a category 2B treatment option in the first-line (in combination with GC) and subsequent line settings for patients with recurrent or metastatic NPC. This drug is currently not FDA approved for treatment of NPC.

The anti-programmed cell death protein 1 (PD-1) antibody camrelizumab, administered in combination with GC, has also been evaluated in a randomized phase 3 trial from China, which a prespecified interim analysis showed significantly greater PFS in the camrelizumab arm, compared to the placebo arm (9.7 months vs. 6.9 months, respectively; HR, 0.54).[572] This agent is not currently available in the United States.

The anti-PD-1 antibodies pembrolizumab and nivolumab have been independently evaluated as monotherapy for previously treated, recurrent or metastatic NPC in nonrandomized trials. Pembrolizumab in patients with PD-L1–positive recurrent or metastatic NPC was assessed in the nonrandomized multi-institutional phase 1B KEYNOTE-028 trial (*N* = 27).[573] All but two of the patients had previously received systemic therapy for their recurrent or metastatic disease. The objective response rate (partial response only, since no patients had a complete response) was 26%, with a median duration of response of 17.1 months. The OS rate at 6 and 12 months was 85% and 63%, respectively, with PFS rates of 39% and 34%, respectively. Approximately 30% of patients experienced a grade 3–5 drug-related adverse event. Pembrolizumab is an option for patients with previously treated PD-L1–positive recurrent or metastatic NPC, but this is category 2B based on Panel consensus. Pembrolizumab is also an option for patients with previously treated tumor mutational burden-high (TMB-H; ≥10 mut/Mb) disease, based on results from the phase 2 KEYNOTE-158 trial, although there were no patients with nasopharyngeal cancer in this study.[574]

Nivolumab as treatment for recurrent or metastatic NPC has been evaluated in phase 1/2 trials. In the CheckMate 358 trial, nivolumab had an ORR of 20.8% and a disease control rate of 45.8% in 24 patients.[575] A Japanese study showed a more modest ORR of 16.7% and DCR of 41.7%.[576] In an NCI sponsored trial, 44 patients with previously treated recurrent or metastatic NPC (>80% non-keratinizing disease) were treated with nivolumab.[577] The ORR was 20.5%, 1-year OS was 59%, and 1-year PFS was 19.3%. Based on the results of these trials, nivolumab is a category 2B treatment option for patients with previously treated, recurrent or metastatic non-keratinizing NPC.

Radiation Therapy Fractionation

Radiation dose-fractionation schedules may vary slightly depending on institutional preference (see *Cancer of the Nasopharynx: Principles of Radiation Therapy* in the NCCN Guidelines for Head and Neck Cancers). Radiation doses of approximately 70 Gy given in standard fractions of approximately 2.0 Gy/fraction are recommended for control of the gross primary tumor and involved lymph nodes; one specific alternative schedule consists of 2.12 Gy/fraction daily (Monday–Friday) for 33 fractions to all areas of gross disease, also to a total dose of approximately 69.69 Gy.[578] Low-risk subclinical disease, such as in the low neck, can be treated separately to a dose of 44–50 Gy at 2.0 Gy/fraction or can be treated simultaneously within the same plan as for gross disease to doses of 54–56 Gy at 1.6–1.7 Gy/fraction. For areas considered to be at intermediate risk, slightly higher doses such as 59.4–63 Gy in 1.8–2.0 Gy/fraction can be given to regions of the skull base and neck in proximity to gross disease. The total doses and fractionation should be prescribed in relationship to each other and the overall schedule as part of an integrated plan to address the varying areas at risk.

Discussion update in progress

Version 1.2026 © 2025 National Comprehensive Cancer Network© (NCCN©), All rights reserved. NCCN Guidelines® and this illustration may not be reproduced in any form without the express written permission of NCCN.

PLEASE NOTE that use of this NCCN Content is governed by the End-User License Agreement, and you MAY NOT distribute this Content or use it with any artificial intelligence model or tool.
Printed by Galya Basol Kochav on 1/4/2026 9:40:35 AM. Copyright © 2026 National Comprehensive Cancer Network, Inc. All Rights Reserved.

Some recent initiatives have attempted to reduce treatment volumes. For instance, in a randomized multi-center phase 3 trial from China (N = 446), five-year regional relapse-free survival did not significantly differ between patients with N0-1 NPC who received elective RT to the ipsilateral upper neck (sparing the uninvolved lower neck) and patients who received standard whole-neck irradiation (95.0% vs. 94.9%, respectively).[579] Acute radiation-related toxic effects were generally similar between the study arms, though rates of some late toxicities favored the elective upper-neck RT arm, specifically hypothyroidism, skin toxicity, dysphagia, and neck tissue damage.[579,580]

Definitive-style dose-fractionation schedules are frequently used for patients with de novo metastatic disease who achieve response to initial induction therapy and then become eligible for consolidative irradiation of the gross primary and nodal disease. However, for other metastatic scenarios, a variety of palliative schedules may be used (see the NCCN Guidelines for Head and Neck Cancers for these schedules). For treatment volumes following induction chemotherapy, there are conflicting recommendations,[581] but a common practice is to reduce the volumes receiving the highest dose according to shrinkage of tumor that respects anatomic boundaries.

Reirradiation of locoregionally recurrent NPC should be conducted with careful attention to the previously delivered radiation plan and performed when complete surgical extirpation is not possible.[582] Because of the anatomic location of NPC in proximity to the optic structures, brain, brainstem, and spinal cord, there can be high risk with reirradiation of injury to critical neural structures. In a phase 3 open label trial from China, patients with locally advanced recurrent NPC (N = 144) were randomized to receive hyperfractionated RT (prescription dose of approximately 64.8 Gy in 54 fractions, twice daily with an intrafraction interval of at least 6 hours) or RT with mild hypofractionation (prescription dose of 60 Gy in 27 fractions at 2.22 Gy/fraction, given once per day).[583] Both arms delivered 54 Gy to an expanded target (1 Gy twice daily in the hyperfractionation arm, and 2 Gy once daily in the mild hypofractionation arm). Three-year OS rates were improved in the hyperfractionation arm compared to the mild hypofractionation arm (74.6% vs. 55.0%, respectively; HR, 0.54; 95% CI, 0.33–0.88; P = .014). While there was no significant difference in locoregional relapse-free survival or distant metastasis-free survival, Grade 5 late complications were less frequent in the hyperfractionation arm (7% vs. 24%). As tolerability and late complications are a frequent concern associated with reirradiation, hyperfractionation to a lower total physical dose has high appeal as an attractive option for patients who are able to manage this rigorous twice-daily schedule.

Recommendations regarding NPC reirradiation have been published,[584] and reports describe a variety of technical approaches including IMRT, SBRT, and brachytherapy.[585-587] In general, a fractionated course of IMRT in combination with concurrent chemotherapy is the most frequently used approach when the intent remains curative, with SBRT or more highly hypofractionated schedules (eg, ≥3 Gy/fraction) being more commonly used in cases of palliative intent.

Follow-up/Surveillance

Recommendations for surveillance are provided in the algorithm (see *Follow-up Recommendations* in the NCCN Guidelines for Head and Neck Cancers). Since the deep areas of the skull base are inaccessible to clinical examination, periodic cross-sectional imaging may be necessary. Likewise, inspection of the nasopharyngeal mucosa may be best accomplished with periodic endoscopy. The clinical benefit of plasma EBV DNA monitoring is not yet clearly defined (see *Epstein-Barr Virus*, above), but it may be considered in centers with experience (category 2B).

Discussion update in progress

Version 1.2026 © 2025 National Comprehensive Cancer Network© (NCCN©), All rights reserved. NCCN Guidelines® and this illustration may not be reproduced in any form without the express written permission of NCCN.

PLEASE NOTE that use of this NCCN Content is governed by the End-User License Agreement, and you MAY NOT distribute this Content or use it with any artificial intelligence model or tool.
Printed by Galya Basol Kochav on 1/4/2026 9:40:35 AM. Copyright © 2026 National Comprehensive Cancer Network, Inc. All Rights Reserved.

Cancer of the Larynx

The larynx is divided into three regions: supraglottis, glottis, and subglottis. The distribution of cancers is as follows: 30% to 35% in the supraglottic region, 60% to 65% in the glottic region, and 5% in the subglottic region. The incidence and pattern of metastatic spread to regional nodes vary with the primary region. The lymphatic drainage of the glottis is sparse and early-stage primaries rarely spread to regional nodes. Because hoarseness is an early symptom, most glottic cancers are early stage at diagnosis. Thus, glottic cancer has an excellent cure rate of 80% to 90%. Nodal involvement adversely affects survival rates and is rare in T1–2 disease. In contrast, >50% of patients with supraglottic primaries present with spread to regional nodes because of an abundant lymphatic network that crosses the midline. Bilateral cervical metastases are not uncommon with early-stage supraglottic primaries. Thus, supraglottic cancer is often metastatic and higher stage at diagnosis. Subglottic cancer is not discussed, because it is uncommon.

Workup and Staging

The evaluation of the patient to determine tumor stage is similar for glottic and supraglottic primaries (see *Cancer of the Glottic Larynx* and *Cancer of the Supraglottic Larynx* in the NCCN Guidelines for Head and Neck Cancers). Multidisciplinary consultation is frequently indicated for both sites because of the potential impact on voice quality, speech, and swallowing functions (see *Principles of Nutrition: Management and Supportive Care* in the NCCN Guidelines for Head and Neck Cancers). The 2017 AJCC staging classification (8th edition) for laryngeal primary tumors is determined by the number of subsites involved, vocal cord mobility, the presence of metastases, extranodal extension, and invasion of thyroid/cricoid cartilage (see Table 5).[400]

Treatment

In the NCCN Guidelines, the treatment of patients with laryngeal cancer is divided into two categories: 1) tumors of the glottic larynx; or 2) tumors of the supraglottic larynx.

For patients with carcinoma in situ of the larynx, recommended treatment options include: 1) endoscopic resection, which is preferred; or 2) RT.[588,589] For early-stage glottic or supraglottic cancer, a systematic review published in 2009 showed that surgery or RT have similar effectiveness[590] (see *Cancer of the Glottic Larynx* and *Cancer of the Supraglottic Larynx* in the NCCN Guidelines for Head and Neck Cancers), although the quality of studies comparing the effectiveness of RT and surgery in early laryngeal cancer is low.[591] A systematic review including 48 studies of patients with T2 glottic cancer specifically showed no difference in 5-year local control between transoral surgery (1156 patients; 77.3%) and EBRT (3191 patients; 75.8%).[592] However, a meta-analysis including 11 studies showed that OS ($P = .04$) and laryngeal preservation ($P < .001$) were both better in patients who were treated with transoral laser microsurgery, compared to patients treated with RT.[593] The choice of treatment modality depends on anticipated functional outcome, the patient's wishes, reliability of follow-up, and general medical condition.[594] In patients with significant pulmonary comorbidity, total laryngectomy may be preferable over endoscopic or open partial laryngectomy. Partial laryngeal surgery should be carefully considered if adjuvant RT is likely. Consideration should be given to any suspicious lymphadenopathy and risk of metastatic nodal disease. Neck dissection should be performed as indicated when the primary site is treated surgically. In patients with T1–2 node-negative cancer of the supraglottic larynx, lymph node dissection is associated with greater OS.[595] T1–2 supraglottic cancers have a significant risk of occult nodal disease at presentation.

Discussion update in progress

Version 1.2026 © 2025 National Comprehensive Cancer Network© (NCCN©), All rights reserved. NCCN Guidelines® and this illustration may not be reproduced in any form without the express written permission of NCCN.

PLEASE NOTE that use of this NCCN Content is governed by the End-User License Agreement, and you MAY NOT distribute this Content or use it with any artificial intelligence model or tool.
Printed by Galya Basol Kochav on 1/4/2026 9:40:35 AM. Copyright © 2026 National Comprehensive Cancer Network, Inc. All Rights Reserved.

Postoperative adjuvant treatment depends on the presence or absence of adverse pathologic features, such as margin status, nodal staging, and any extranodal extension. For cancer of the glottic larynx, subglottic extension is also considered an adverse pathologic feature. In the event of close or positive margins in organ preservation surgery, re-resection to negative margins may be considered. This may or may not require a total laryngectomy to achieve.

Resectable, advanced-stage glottic and supraglottic primaries are usually managed with a combined modality approach (see *Cancer of the Glottic Larynx* and *Cancer of the Supraglottic Larynx* in the NCCN Guidelines for Head and Neck Cancers). If laryngeal preservation is desired, concurrent systemic therapy/RT is recommended, based on results from Intergroup trial RTOG 91-11.[298,304] R91-11 was a successor trial to the VA trial and compared three non-surgical regimens: 1) induction cisplatin/5-FU followed by RT (control arm and identical to that in the VA trial); 2) concurrent RT and high-dose cisplatin 100 mg/m^2 days 1, 22, and 43; and 3) RT alone. RT was uniform in all three arms (70 Gy/7 weeks, 2 Gy/fraction), as was the option of surgery (including total laryngectomy) for relapsed/refractory disease in all arms. Patients with stage III and IV (M0) disease were eligible, excluding T1 primaries and high-volume T4 primaries (tumor extending >1 cm into the base of the tongue or tumor penetrating through cartilage). The key findings of the R91-11 trial were: 1) a statistically significant higher 2-year laryngeal preservation (local control) rate of 88% for concurrent RT with cisplatin, compared to 74% for induction chemotherapy and 69% for RT alone; 2) no significant difference in laryngeal preservation between induction and RT alone treatments; and 3) similar survival for all treatment groups. Based on these results, concurrent RT and systemic therapy (cisplatin preferred [category 1]) is a treatment option for achieving laryngeal preservation for T3, any N glottic and supraglottic cancers.[304] Long-term follow-up (10 years) of R91-11 indicates that laryngeal preservation continues to be better (ie, statistically different) with concurrent cisplatin/RT when compared with either induction chemotherapy or RT alone.[298] OS was not statistically different for all treatment groups; there was more non–cancer-related mortality among patients treated with concurrent cisplatin/RT.

Definitive RT (without systemic therapy) is an option for patients with T3, N0–1 disease who are medically unfit or refuse systemic therapy (see *Cancer of the Glottic Larynx* and *Cancer of the Supraglottic Larynx* in the NCCN Guidelines for Head and Neck Cancers). Surgery is also an option for this patient population. For those patients whose disease persists after systemic therapy/RT or RT, surgical therapy is indicated (see *Post Systemic Therapy/RT or RT Neck Evaluation* in *Follow-up Recommendations* in the NCCN Guidelines for Head and Neck Cancers).

Induction chemotherapy with management based on response is an option for all but T1–2, N0 glottic and supraglottic cancers. Based on the long-term update of RTOG 91-11, induction chemotherapy is an option for patients who require (are amenable to) total laryngectomy.[298] After a complete or partial response with induction chemotherapy for patients with laryngeal cancer, RT alone is recommended (category 1)[298]; systemic therapy/RT is a category 2B recommendation after a partial response[312,313,596] (see *Cancer of the Glottic Larynx* and *Cancer of the Supraglottic Larynx* in the NCCN Guidelines for Head and Neck Cancers).

For patients with glottic and supraglottic T4a tumors, the recommended treatment approach is total laryngectomy with possible hemi- or total thyroidectomy and appropriate neck dissection(s) followed by adjuvant treatment (RT or systemic therapy/RT)[597] (see *Cancer of the Glottic Larynx, Cancer of the Supraglottic Larynx,* and *Principles of Surgery* in the NCCN Guidelines for Head and Neck Cancers). For selected patients with T4a tumors who decline surgery, the NCCN Panel recommends: 1) considering concurrent systemic therapy/RT; 2) clinical trials; or 3)

Discussion update in progress

Version 1.2026 © 2025 National Comprehensive Cancer Network© (NCCN©), All rights reserved. NCCN Guidelines® and this illustration may not be reproduced in any form without the express written permission of NCCN.

PLEASE NOTE that use of this NCCN Content is governed by the End-User License Agreement, and you MAY NOT distribute this Content or use it with any artificial intelligence model or tool.
Printed by Galya Basol Kochav on 1/4/2026 9:40:35 AM. Copyright © 2026 National Comprehensive Cancer Network, Inc. All Rights Reserved.

induction chemotherapy with additional management based on response.[298,304]

Radiation Therapy Fractionation

Fractionation for RT is discussed in the algorithm (see *Cancer of the Glottic Larynx: Principles of Radiation Therapy* and *Cancer of the Supraglottic Larynx: Principles of Radiation Therapy* in the NCCN Guidelines for Head and Neck Cancers). For patients with T1, N0 disease of the glottic larynx, an accelerated dosing schedule of 63 Gy (2.25 Gy/fraction) is preferred over conventional fractionation (66 Gy, 2.0 Gy/fraction), based on results of a prospective randomized trial showing that this accelerated dosing schedule was associated with better 5-year local control, compared to a conventional dosing schedule (92% vs. 77%, respectively; $P = .004$), in 180 patients with stage I cancer of the glottic larynx.[169] For patients with comorbidities or travel logistics or who are older adults, 50–52 Gy (3.12–3.28 Gy/fraction) may also be considered.[598] A second accelerated dosing schedule of 60 Gy (2.4 Gy/fraction) may also be used for patients with T1–2, N0 disease based on the results of an ancillary study from the randomized, multicenter, phase III JCOG0701 trial.[599] When compared to standard fractionation (66-70 Gy, the accelerated fractionation group (60–64.8 Gy in 2.4 Gy/fraction) showed greater local control and similar 5-year PFS (76.2% vs. 78.2%, respectively) in 366 patients with stage I or II squamous cell carcinoma of the glottis. Cumulative incidence of late adverse events was also lower in the accelerated fractionation group compared to the standard fractionation arm at 7.4% and 11.9%, respectively.

Follow-up/Surveillance

Recommendations for surveillance are provided in the algorithm (see *Follow-up Recommendations* in the NCCN Guidelines for Head and Neck Cancers). Serial endoscopy is recommended during follow-up examinations and may be supplemented with high-resolution, advanced radiologic imaging because of the scarring, edema, and fibrosis that occur in the laryngeal tissues and neck after RT-based treatment.

Paranasal Tumors (Maxillary and Ethmoid Sinus Tumors)

Tumors of the paranasal sinuses are rare, and patients are often asymptomatic until late in the course of their disease. Tumors of the maxillary sinus are more common than those of the ethmoid sinus or nasal cavity.[399] Workup is similar for ethmoid and maxillary sinus tumors (see *Ethmoid Sinus Tumors* and *Maxillary Sinus Tumors* in the NCCN Guidelines for Head and Neck Cancers).

Although the most common histology for these tumors is squamous cell carcinoma, a variety of histologies have been reported including intestinal type adenocarcinoma, esthesioneuroblastoma (also known as olfactory neuroblastoma), minor salivary gland tumors, and undifferentiated carcinoma (eg, sinonasal undifferentiated carcinoma [SNUC], small cell carcinoma, midline NUT carcinoma, and sinonasal neuroendocrine carcinoma [SNEC]).[600-604] The defining features of esthesioneuroblastoma, SNUC, and SNEC continue to be debated,[605] and correct pathologic diagnosis is paramount for treatment decision-making. In the case of midline NUT carcinoma, a specific diagnosis is made based upon immunohistochemistry or pathognomonic NUT gene rearrangement. For patients diagnosed with these diseases, referral to a major medical center with expertise in confirming diagnosis of these tumors should be considered.

Locoregional control and risk of distant metastasis are dependent on T stage, N stage, and tumor histology.[606] However, T stage (see Table 6) remains the most reliable predictor of survival and locoregional control.[400] MM also occurs in the paranasal sinus region, nasal cavity, and oral cavity (see *Mucosal Melanoma* in the NCCN Guidelines for Head and Neck Cancers). Sarcoma and lymphoma should also be considered in the

Discussion update in progress

Version 1.2026 © 2025 National Comprehensive Cancer Network© (NCCN©), All rights reserved. NCCN Guidelines® and this illustration may not be reproduced in any form without the express written permission of NCCN.

PLEASE NOTE that use of this NCCN Content is governed by the End-User License Agreement, and you MAY NOT distribute this Content or use it with any artificial intelligence model or tool.
Printed by Galya Basol Kochav on 1/4/2026 9:40:35 AM. Copyright © 2026 National Comprehensive Cancer Network, Inc. All Rights Reserved.

differential diagnosis when evaluating a patient with a paranasal sinus tumor (see the NCCN Guidelines for Soft Tissue Sarcoma, the NCCN Guidelines for B-Cell Lymphomas, and the NCCN Guidelines for T-Cell Lymphomas, available at www.NCCN.org).[607,608]

Ethmoid Sinus Tumors

Patients with early-stage ethmoid sinus cancer are typically asymptomatic or have minor symptoms of nasal stuffiness, epistaxis, or anosmia. These neoplasms are often found after a routine nasal polypectomy or during the course of a nasal endoscopic examination. For a patient with gross residual disease left behind after an initial endoscopic procedure, an oncologically complete resection of the residual tumor is required. This may be done endoscopically or with an open approach. In some instances, this procedure may entail an anterior craniofacial resection to remove the cribriform plate and intracranial component of the tumor to ensure clear surgical margins. Nodal involvement is rare in ethmoid sinus tumors, and, when present, lymph node metastasis is associated with poor prognosis.[609] Patients with ethmoid sinus cancer who have N+ neck disease should undergo neck dissection with adjuvant therapy as appropriate based on the presence of adverse histopathological features. Patients with high-grade tumors have worse survival outcomes compared to those with low-grade tumors.[610]

Often patients with ethmoid sinus cancer present after having had an incomplete endoscopic resection. The patient who is diagnosed after incomplete resection (eg, polypectomy with histologically positive margin)—and has no documented residual disease on physical examination, imaging, and/or endoscopy—should be treated with surgical resection to obtain oncologically appropriate margins if feasible (see *Ethmoid Sinus Tumors* in the NCCN Guidelines for Head and Neck Cancers). If no adverse pathologic features are found, complete surgical resection may obviate the need for postoperative RT in T1 patients only (category 2B). In patients with high-risk pathologic features, such as positive or close margins adjacent to vital structures, high-grade lesions or other unfavorable histology, intracranial and/or intraorbital extension, cribriform plate or medial wall of orbit location, and/or perineural and lymphovascular space invasion, postoperative systemic therapy/RT can be considered.

RT or concurrent systemic therapy/RT may be considered as definitive treatment in patients for whom an oncologically satisfactory surgical resection is not possible. Radiation therapy fractionation for patients with ethmoid sinus tumors is described in *Ethmoid Sinus Tumors: Principles of Radiation Therapy* in the NCCN Guidelines for Head and Neck Cancers. IMRT or PBT is recommended due to the proximity of this anatomic area to the optic structures and to minimize dose to critical structures; PBT should be considered if the normal tissue constraints cannot be met by IMRT.

Systemic therapy/RT may be considered to preserve the orbital contents and avoid incomplete surgery in patients with T4 disease, based on limited case series.[611,612] In these patients, induction and concurrent chemotherapy may be given in combination with RT. A retrospective study including 123 patients with stage III or IV sinonasal squamous cell carcinoma treated from 1988 to 2017 at an NCCN Member Institution showed an ORR of 62.6% (71 partial responses, 6 complete responses) following treatment with induction chemotherapy using regimens typical for SCCHN.[613] Two-year OS, 2-year DFS, and rate of orbital preservation were 61.4%, 67.9%, and 81.5%, respectively. Distant metastasis occurred in only 6.5%.

Systemic therapy should routinely be part of the overall treatment for patients with SNUC with neuroendocrine features; small cell, high-grade olfactory esthesioneuroblastoma; midline NUT; or SNEC histologies The optimal regimen for these patients is not well-defined, but typically

Discussion update in progress

Version 1.2026 © 2025 National Comprehensive Cancer Network© (NCCN©), All rights reserved. NCCN Guidelines® and this illustration may not be reproduced in any form without the express written permission of NCCN.

PLEASE NOTE that use of this NCCN Content is governed by the End-User License Agreement, and you MAY NOT distribute this Content or use it with any artificial intelligence model or tool.
Printed by Galya Basol Kochav on 1/4/2026 9:40:35 AM. Copyright © 2026 National Comprehensive Cancer Network, Inc. All Rights Reserved.

regimens used for high-grade neuroendocrine carcinomas (eg, etoposide plus platinum, cyclophosphamide/doxorubicin/vincristine) or for advanced SCCHN (eg, TPF, PF, TP) are used.[614-623] After curative-intent treatment, long-term follow-up is necessary for esthesioneuroblastoma, since late recurrences can occur even after 15 years.[622,624,625]

Induction chemotherapy is an option for patients with newly diagnosed T3, T4a disease, and options are based on molecular features. In a single center retrospective study including 95 patients with SNUC, concurrent systemic therapy/RT following complete or partial response to induction chemotherapy (ie, etoposide with platinum-based therapy) was associated with a 5-year DSS rate of 81% (95% CI, 69%–88%), compared to 59% (95% CI, 53%–66%) for the entire sample.[626] The DSS rate for patients who received surgery with adjuvant therapy following a less than partial response to induction chemotherapy was 39% (95% CI, 30%–46%). Definitive trials of induction chemotherapy prior to surgery are currently underway within the U.S. cooperative groups.

For patients with metastatic disease, options include platinum combined with etoposide (with or without concurrent RT)[614,627,628] and cyclophosphamide/doxorubicin/vincristine (category 2B). While there remains no known effective treatment for metastatic midline NUT carcinoma, there are targeted therapies such as bromodomain inhibitors under active investigation.[629,630] Because of a paucity of data concerning the use of systemic therapies, appropriate use of other systemic options, including immunotherapy, remains undefined.

Maxillary Sinus Tumors

Surgical resection followed by postoperative radiotherapy remains a cornerstone of treatment for most maxillary sinus tumors, except limited extent T1–2 tumors resected with negative margins (see *Maxillary Sinus Tumors* in the NCCN Guidelines for Head and Neck Cancers).[631-634] The principles are generally similar to those described above for ethmoid sinus tumors. For patients with SNUC with neuroendocrine features; small cell, high-grade olfactory esthesioneuroblastoma; or midline NUT or SNEC histologies, systemic therapy should be routinely included as part of the treatment plan (see *Ethmoid Sinus Tumors* in this Discussion). Participation in clinical trials is recommended for patients with malignant tumors of the paranasal sinuses with these histologies.

RT fractionation for patients with maxillary sinus tumors is described in *Maxillary Sinus Tumors: Principles of Radiation Therapy* in the NCCN Guidelines for Head and Neck Cancers. Studies using IMRT have shown that it reduces the incidence of complications, such as radiation-induced ophthalmic toxicity, although the 5-year OS rate was not improved.[225,633,635-638] Similar to the recommendation for ethmoid sinus tumors, IMRT or PBT is recommended in this anatomic area due to proximity to the visual structures and proton therapy is preferred if the normal tissue constraints cannot be met by IMRT.

Follow-up

Recommendations for surveillance are provided in the algorithm (see *Follow-up Recommendations* in the NCCN Guidelines for Head and Neck Cancers).

Very Advanced Head and Neck Cancers

The algorithms for very advanced H&N cancers include: 1) newly diagnosed (M0) locally advanced T4b, N0–3, or newly diagnosed unresectable regional nodal disease, or those unfit for surgery; 2) metastatic disease at initial presentation (M1); 3) or recurrent or persistent disease with or without distant metastases. The treatment goal is usually cure for patients with newly diagnosed locoregional but unresectable disease. For recurrent disease, the goal is cure if surgery or radiation remains feasible, or palliation if the patient has received previous RT and

Discussion update in progress

Version 1.2026 © 2025 National Comprehensive Cancer Network© (NCCN©), All rights reserved. NCCN Guidelines® and this illustration may not be reproduced in any form without the express written permission of NCCN.

PLEASE NOTE that use of this NCCN Content is governed by the End-User License Agreement, and you MAY NOT distribute this Content or use it with any artificial intelligence model or tool.
Printed by Galya Basol Kochav on 1/4/2026 9:40:35 AM. Copyright © 2026 National Comprehensive Cancer Network, Inc. All Rights Reserved.

the disease is unresectable. For patients with widely metastatic disease, the goal is palliation or prolongation of life.

Treatment

The treatment of patients with unresectable locoregional, persistent, recurrent, or metastatic H&N cancers is dictated by the patient's PS and intent of treatment (ie, palliative vs. curative). Patients with good PS may tolerate a wide range of treatment options, whereas patients with reduced PS cannot.

Newly Diagnosed Locoregionally Advanced Disease

In patients with a PS of 0 or 1, the recommended treatment of newly diagnosed, very advanced disease is concurrent systemic therapy/RT, with a large amount of phase III data supporting high-dose cisplatin as a category 1 preferred recommendation (see *Primary Systemic Therapy with Concurrent RT* under *Systemic Therapy* in this Discussion).[273,298] There are also considerable phase III data from Europe that support the use of carboplatin/5-FU with concurrent RT.[182] This treatment is also considered a category 1 preferred option. Cisplatin-based induction systemic therapy has been studied, followed by RT alone or chemoradiation with weekly platinum or cetuximab.[324] However, an improvement in OS with the incorporation of induction chemotherapy, compared to proceeding directly to state-of-the-art concurrent systemic therapy/RT, has not been established in randomized studies.[316,317] Cetuximab with concurrent RT is a category 2B option based on phase II and phase III data but is distinctly inferior to cisplatin with concurrent RT, particularly in patients with HPV-positive disease, as discussed above (see *Primary Systemic Therapy with Concurrent RT* under *Systemic Therapy* in this Discussion).[144,291,295,296,639] Other chemoradiation options include carboplatin/paclitaxel (category 2B based on less Panel consensus), weekly cisplatin 40 mg/m^2, and docetaxel (for patients not eligible for cisplatin).[144,640-643] Category 2B chemoradiation options that the Panel has deemed useful only in select circumstances are 5-FU/hydroxyurea, cisplatin with infusional 5-FU, and cisplatin/paclitaxel.[644,645]

Other options for patients with a PS of 2–4 are described in the algorithm (see *Very Advanced Head and Neck Cancer: Treatment of Newly Diagnosed (M0) T4b, N0–3 or Unresectable Nodal Disease or Unfit for Surgery* in the NCCN Guidelines for Head and Neck Cancers). Primary systemic therapy/RT regimens are listed in the *Principles of Systemic Therapy for Non-Nasopharyngeal Cancers* in the NCCN Guidelines for Head and Neck Cancers. Radiation therapy fractionation for patients with newly diagnosed, very advanced disease is described in the *Very Advanced Head and Neck Cancers: Principles of Radiation Therapy* in the NCCN Guidelines for Head and Neck Cancers.

Metastatic Disease

For patients with metastatic (M1) disease at initial presentation, enrollment in a clinical trial is preferred. Palliative adjunctive measures include RT, surgery, analgesics, and other therapies to control manifestations of disease spread (eg, pain, hypercalcemia, malnutrition). Locoregional treatment (eg, surgery, RT, ablative therapies) may be used for oligometastatic disease.[646-648]

Historically, single-agent and combination systemic therapy have both been used.[563] Response rates to single-agent therapies range from 15% to 35%.[564,649,650] Randomized trials assessing a cisplatin-based combination regimen (cisplatin/5-FU) versus single-agent therapy with cisplatin, 5-FU, or methotrexate showed significantly higher response rates, but no difference in OS and greater toxicity for the combination regimen.[553,554,557,651,652] Complete response is associated with longer survival and, although infrequent, has been reported more often with combination regimens.[554] A phase III randomized trial (EXTREME) of 442 patients found that cetuximab plus cisplatin/5-FU or carboplatin/5-FU improved response rate (36% vs. 20%; $P < .001$) and median survival

Discussion update in progress

Version 1.2026 © 2025 National Comprehensive Cancer Network© (NCCN©), All rights reserved. NCCN Guidelines® and this illustration may not be reproduced in any form without the express written permission of NCCN.

PLEASE NOTE that use of this NCCN Content is governed by the End-User License Agreement, and you MAY NOT distribute this Content or use it with any artificial intelligence model or tool.
Printed by Galya Basol Kochav on 1/4/2026 9:40:35 AM. Copyright © 2026 National Comprehensive Cancer Network, Inc. All Rights Reserved.

compared to the standard chemotherapy doublet of platinum/5-FU in a patient population predominantly linked to tobacco and alcohol use (10.1 vs. 7.4 months; *P* = .04).[653] A randomized phase III trial found no significant difference in survival when comparing cisplatin/5-FU and cisplatin/paclitaxel.[553]

Trials evaluating immune checkpoint inhibitors demonstrated efficacy in patients with recurrent or metastatic SCCHN.[654-656] Pembrolizumab, an anti-PD-1 antibody, was evaluated as a first-line option for recurrent or metastatic SCCHN in the KEYNOTE-048 trial (*N* = 882).[654] Patients were randomized to receive pembrolizumab, pembrolizumab with a platinum and 5-FU, or the EXTREME regimen. In the total population, an OS benefit was observed in the pembrolizumab/platinum/5-FU arm, compared to the EXTREME arm (median OS, 13 vs. 10.7 months, respectively; HR, 0.77; 95% CI, 0.63–0.93; *P* = .003). PFS, however, did not significantly differ between these two study arms. Median duration of response was greater in patients treated with pembrolizumab monotherapy or pembrolizumab with chemotherapy, compared to patients treated with the EXTREME regimen.

Results from KEYNOTE-048 showed that, in patients with a PD-L1 CPS of ≥20 or ≥1, median OS was better in patients who received pembrolizumab monotherapy, compared to those who received the EXTREME regimen (median, 14.9 vs. 10.7 months, respectively; HR, 0.61; 95% CI, 0.45–0.83; *P* < .001 for CPS ≥20; median, 12.3 vs. 10.3 months, respectively; HR, 0.78; 95% CI, 0.64–0.96; *P* = .009 for CPS ≥1).[654] In an update with a median study follow-up of 45.0 months, OS improved with pembrolizumab in the PD-L1 CPS ≥ 20 (HR, 0.61; 95% CI, 0.46–0.81) and CPS ≥1 populations (HR, 0.74; 95% CI, 0.61–0.89).[657] OS improved with pembrolizumab and chemotherapy in the PD-L1 CPS ≥ 20 (HR, 0.62; 95% CI, 0.46–0.84), CPS ≥1 (HR, 0.64; 95% CI, 0.53–0.78), and total (HR, 0.71; 95% CI, 0.59–0.85) populations. This supports CPS ≥1 for pembrolizumab monotherapy, and no PD-L1-based selection for combination of chemotherapy and pembrolizumab. No formal comparison exists between both pembrolizumab-containing arms, and the selection of regimens remains based on clinical judgement. The one difference observed was that the PFS of subsequent therapy was similar after pembrolizumab and longer after pembrolizumab and taxane-containing chemotherapy and shorter after pembrolizumab and similar after pembrolizumab and non-taxane–containing chemotherapy.

The Panel considers immunotherapy as the preferred first-line systemic therapy option for all patients with recurrent, unresectable, or metastatic disease who have no surgical or radiotherapeutic option. Specifically, pembrolizumab alone (for patients with CPS ≥1) or pembrolizumab/platinum/5-FU are both category 1 preferred first-line options based on the results of KEYNOTE-048; the combination regimen may be particularly suitable in patients with a PS of 0 or 1 and either a large burden of disease or nearing a clinical crisis.[654] Other combination regimens recommended by the Panel for treatment of metastatic SCCHN include: 1) cisplatin or carboplatin, plus 5-FU with cetuximab (category 1)[653]; 2) cisplatin or carboplatin, plus a taxane[552,553]; 3) cisplatin with cetuximab[558,658]; 4) cisplatin with 5-FU[553,554]; or 5) cetuximab with a platinum and a taxane.[658-662] Extrapolating from Guigay et al,[662] a taxane can be considered, when used in combination with pembrolizumab and a platinum.[654] Cetuximab combined with an anti–PD-1 antibody (pembrolizumab or nivolumab) is also an option for recurrent or metastatic SCCHN based on results from non-randomized phase II trials.[663,664]

Other options that the Panel considers useful in certain circumstances for patients with recurrent or metastatic SCCHN are cisplatin/pemetrexed (for PS 0–1 only),[665] cetuximab with a taxane,[658,662] gemcitabine/paclitaxel,[666] and nivolumab/ipilimumab (CPS ≥20 and first-

Discussion update in progress

Version 1.2026 © 2025 National Comprehensive Cancer Network© (NCCN©), All rights reserved. NCCN Guidelines® and this illustration may not be reproduced in any form without the express written permission of NCCN.

PLEASE NOTE that use of this NCCN Content is governed by the End-User License Agreement, and you MAY NOT distribute this Content or use it with any artificial intelligence model or tool.
Printed by Galya Basol Kochav on 1/4/2026 9:40:35 AM. Copyright © 2026 National Comprehensive Cancer Network, Inc. All Rights Reserved.

line only).[667] These are all category 2B options except for paclitaxel/cetuximab. Single agents recommended by the Panel include cisplatin, carboplatin, paclitaxel, docetaxel, 5-FU, methotrexate, capecitabine, and cetuximab.[554,557-565,567,568,668,669]

Locoregionally Recurrent or Persistent Disease

A multidisciplinary evaluation is critical in defining appropriate therapy for patients with local and/or regional disease recurrence or persistence without distant metastasis. A subset of these patients can be approached with curative intent local therapy, and the therapeutic options depend on several factors, including: type of prior therapy (surgery vs. radiation), interval between prior therapy and recurrence, desire for functional preservation, and patient PS.

In general, surgery is recommended for resectable recurrent or persistent locoregional disease, in the absence of distant metastatic disease; adjuvant therapy depends on pathologic risk factors. Patients with resectable recurrent or persistent locoregional disease who have not previously been treated with RT may also be treated with concurrent systemic therapy/RT (high-dose cisplatin is the preferred [category 1] systemic agent).[273] Combination systemic therapy followed by RT or systemic therapy/RT (category 2B) may be considered for cytoreduction or symptom control, followed by local therapy such as surgery as clinically indicated.

Among patients with unresectable recurrence or persistence in a previously non-irradiated field, RT with concurrent systemic therapy is recommended, with the duration of RT and choice of systemic agent dependent on the PS. No randomized data exist that define a preferred systemic therapy/RT combination in this setting, although early-phase studies have explored carboplatin, PD-1 inhibitors, and cetuximab. In situations where patient or tumor factors render patients as poor candidates for curative-intent radiation or surgery, the treatment approach is the same as that for patients with metastatic disease; however, in the absence of distant metastatic disease and/or in the presence of symptoms, re-irradiation with systemic therapy is increasingly feasible (see below). Locoregional treatment such as palliative radiation may be considered in the presence of distant metastasis with locoregional failure to alleviate tumor burden-related symptoms. RT fractionation for patients with recurrent or persistent disease is described in *Very Advanced Head and Neck Cancers: Principles of Radiation Therapy* in the NCCN Guidelines for Head and Neck Cancers).

Reirradiation

Reirradiation may be offered to patients with locally and/or regionally recurrent or persistent H&N cancer, using IMRT, PBT, or SBRT. A randomized phase III multicenter trial in France (N = 130) showed that reirradiation combined with systemic therapy in patients following a resected recurrence improves DFS, compared to patients receiving only surgery (HR, 1.68; 95% CI, 1.13–2.50; P = .01).[670] However, the toxicity of this regimen was considerable, with grade 3 of 4 acute toxicity (mucositis/pharyngitis) in 28% of patients; however, results achieved using the older techniques in this study may not apply to the current day. As previously stated, SBRT has been investigated only in small series and studies.[268,269]

When concurrent systemic therapy is given with conventionally fractionated reirradiation, cisplatin with concurrent RT is the preferred option for individuals with unresectable recurrent or persistent disease who received prior RT.[142,641] The Panel also recommends carboplatin, cetuximab, or docetaxel with concurrent RT as useful in certain circumstances as a reirradiation and concurrent systemic therapy option (all category 2B).[144,291,543,545]

Advanced RT techniques should be used for reirradiation. A retrospective review of 227 patients who were treated at an NCCN Member Institution

Discussion update in progress

Version 1.2026 © 2025 National Comprehensive Cancer Network© (NCCN©), All rights reserved. NCCN Guidelines® and this illustration may not be reproduced in any form without the express written permission of NCCN.

PLEASE NOTE that use of this NCCN Content is governed by the End-User License Agreement, and you MAY NOT distribute this Content or use it with any artificial intelligence model or tool.
Printed by Galya Basol Kochav on 1/4/2026 9:40:35 AM. Copyright © 2026 National Comprehensive Cancer Network, Inc. All Rights Reserved.

showed that IMRT-based reirradiation of the H&N may be associated with local control and improved survival rates, but toxicity rates were considerable, with adverse events grade 3 or higher occurring in 16% of patients at 2 years.[585,671] Use of concurrent systemic therapy may be associated with greater risk of toxicity. Rates for 1-year local control, distant control, DFS, and OS were 51%, 90%, 49%, and 64%, respectively, and adverse events grade 3 or higher were rare. The best outcomes for SBRT for reirradiation are in patients with smaller tumors (<25 cc) and no skin involvement. Intraoperative RT (IORT) and brachytherapy may also be used for select patients at high-volume centers.[672-674] Intraoperative RT is usually dosed at 10–15 Gy and followed by 40—50 Gy using EBRT preferably IMRT.[675]

The decision to treat with reirradiation should take into account comorbidity, the toxicity of previous treatment methods, organ dysfunction, and the amount of time that has passed since previous treatment.[676-679] Treatment planning should at a minimum take brainstem, spinal cord and laryngeal lifetime dose limits into account so that the safest maximum dose is delivered.[676,680,681] PBT may be used for reirradiation when normal tissue constraints cannot be met by photon-based therapy.[585,682-684] Retrospective studies show that PBT used for reirradiation may be associated with good outcomes (eg, 65%–84% OS, improved locoregional control, freedom from distant metastasis) and acceptable toxicity.[252,682,683] However, in one retrospective study, three patients died (out of 60), possibly due to reirradiation-related effects.[682]

Dosing schedules that may be used for reirradiation are described in *Radiation Techniques* in the NCCN Guidelines for Head and Neck Cancers. Radiation volumes should usually include only volumes of known disease, to minimize the amount of tissue receiving high doses in previously irradiated regions. Therefore, prophylactic treatment (eg, elective nodal irradiation) is not routinely indicated.[685] There are currently knowledge gaps regarding the appropriate use of reirradiation, and patients should be encouraged to enroll in clinical trials.[585,676]

Disease That Has Progressed on or After Platinum Therapy

After progression of disease on platinum-based therapy, options are listed in the Guidelines (see *Principles of Systemic Therapy for Non-Nasopharyngeal Cancer: Recurrent, Unresectable, or Metastatic* in the NCCN Guidelines for Head and Neck Cancers). NGS genomic profiling may be considered to identify biomarkers for applicable targeted therapies.

Nivolumab was assessed in a phase III RCT including 361 patients with recurrent SCCHN whose disease had progressed within 6 months following platinum-based chemotherapy.[656] With a median follow-up of 5.1 (range, 0–16.8) months, the OS was significantly greater in patients given nivolumab, compared to patients given standard second-line single-agent systemic therapy (methotrexate, docetaxel, or cetuximab) (HR, 0.70; 97.73% CI, 0.51–0.96; P = .01). One-year survival was also greater for patients who received nivolumab, relative to patients who received standard therapy (36.0% vs. 16.6%, respectively), and response rate was higher (13.3% vs. 5.8%, respectively), but median PFS was not significantly different between the two groups (2.0 vs. 2.3 months, respectively; P = .32). In prespecified exploratory analyses, the OS benefit in patients treated with nivolumab appeared to be confined to those patients with a tumor PD-L1 expression level of ≥1% (n = 149) (8.7 vs. 4.6 months; HR, 0.55; 95% CI, 0.36–0.83). In patients with tumor PD-L1 expression level <1% (n = 111), no OS advantage was demonstrated for the nivolumab-treated patients (5.7 vs. 5.8 months; HR, 0.89; 95% CI, 0.54–1.45). Grade 3 or 4 treatment-related adverse events occurred in 13.1% of patients who received nivolumab, compared to 35.1% of patients who received standard therapy. These results indicate that nivolumab prolongs survival in patients with recurrent or metastatic

Discussion update in progress

Version 1.2026 © 2025 National Comprehensive Cancer Network© (NCCN©), All rights reserved. NCCN Guidelines® and this illustration may not be reproduced in any form without the express written permission of NCCN.

PLEASE NOTE that use of this NCCN Content is governed by the End-User License Agreement, and you MAY NOT distribute this Content or use it with any artificial intelligence model or tool.
Printed by Galya Basol Kochav on 1/4/2026 9:40:35 AM. Copyright © 2026 National Comprehensive Cancer Network, Inc. All Rights Reserved.

squamous cell H&N cancer that has progressed after platinum-based chemotherapy, relative to patients who receive standard single-agent systemic therapy. There are two FDA-approved dosing regimens for nivolumab for treatment of SCCHN: 240 mg every 2 weeks or 480 mg every 4 weeks.

Pembrolizumab was initially studied at a dose of 10 mg/kg given every 2 weeks in the SCCHN cohort of the KEYNOTE-012 trial, and clinical activity was identified.[686] A lower, fixed-dose schedule using pembrolizumab 200 mg every 3 weeks was subsequently assessed in a phase 1b expansion cohort of 132 patients with recurrent or metastatic SCCHN.[687] At 6 months, the OS rate was 59%, and the PFS was 23%, with an ORR of 18%. Observed responses appeared durable, although the follow-up was limited (median, 9 months). Pembrolizumab was also generally well-tolerated.[686] Pooled analyses after long-term follow-up of the initial and expansion cohorts (*N* = 192) showed a 1-year OS rate of 38%.[688] Among the 34 patients with a disease response, 85% of the responses lasted 6 months or longer, and 71% lasted 12 months or longer. The FDA has approved an alternate dosing regimen of pembrolizumab 400 mg every 6 weeks across all currently approved adult indications.

Based on results of the phase Ib KEYNOTE-012 trial, pembrolizumab was evaluated in the phase III KEYNOTE-040 trial.[655] Patients with recurrent or metastatic SCCHN (*N* = 495) were randomized to receive pembrolizumab or another systemic therapy (methotrexate, docetaxel, or cetuximab). Median OS was greater for the pembrolizumab arm compared to the standard-of-care arm (8.4 vs. 6.9 months; HR, 0.80; 95% CI, 0.65–0.98; *P* = .016). When analyses were stratified by PD-L1 status, the results for OS were significantly better with pembrolizumab only for patients with tumors that have PD-L1 expression. A post hoc subgroup analysis of the KEYNOTE-040 trial evaluated outcomes in patients with recurrent-only (*N* = 125), recurrent and metastatic (*N* = 204), or metastatic-only (*N* = 166) disease.[689] Median OS for pembrolizumab compared to the standard-of-care arm in the recurrent-only group was 8.7 months (95% CI, 5.6–15.2) and 7 months (95% CI, 5.1–9.6), respectively. In the recurrent and metastatic, and metastatic-only groups OS for pembrolizumab versus standard-of-care therapy was 6.7 months (95% CI, 5.2–9.2) and 5.7 months (95% CI, 4.2–7.3), and 8.9 months (95% CI, 7.1–12.1) and 7.9 months (95% CI, 6.3–9.2), respectively. No differences in PFS were reported, regardless of treatment arm or subgroup. Exploratory health-related QOL analyses showed that patients treated with pembrolizumab had stable functioning and symptoms through 15 weeks, compared to the patients treated with standard of care, for whom a decline was observed.[690] Pembrolizumab monotherapy was also evaluated for previously treated tumors with high microsatellite instability (MSI-H)/mismatch repair deficiency (dMMR) in the phase II KEYNOTE-158 basket trial, which included one patient with SCCHN.[691] The ORR for the entire sample (N = 233) was 34.3% (95% CI, 28.3%–40.8%), median PFS was 4.1 months (95% CI, 2.4–4.9), and median OS was 23.5 months (95% CI, 13.5 months–not reached).

The nonrandomized phase II KEYNOTE-055 trial studied pembrolizumab in 171 patients with SCCHN that progressed following treatment with both a platinum and cetuximab.[692] The ORR was 16% (95% CI, 11%–23%), and the mean duration of response was 8 months.

Afatinib was compared to methotrexate in patients with recurrent or metastatic H&N cancer who had progressed on or after platinum-based therapy (*N* = 483) in the phase III LUX-Head & Neck 1 RCT.[693] Patients randomized to receive afatinib had greater PFS compared to patients randomized to receive methotrexate (2.6 vs. 1.7 months; *P* = .03), but there were no significant differences for OS.[693] A randomized phase II trial comparing afatinib to cetuximab in patients with recurrent or

Discussion update in progress

Version 1.2026 © 2025 National Comprehensive Cancer Network© (NCCN©), All rights reserved. NCCN Guidelines® and this illustration may not be reproduced in any form without the express written permission of NCCN.

PLEASE NOTE that use of this NCCN Content is governed by the End-User License Agreement, and you MAY NOT distribute this Content or use it with any artificial intelligence model or tool.
Printed by Galya Basol Kochav on 1/4/2026 9:40:35 AM. Copyright © 2026 National Comprehensive Cancer Network, Inc. All Rights Reserved.

metastatic H&N cancer who had progressed on or after platinum-based therapy (*N* = 121) showed comparable response rates between the two drugs.[694]

The Panel recommends immunotherapy (nivolumab and pembrolizumab) as the category 1 preferred option for patients with recurrent or metastatic SCCHN who have progressed on or following platinum-based chemotherapy, independent of CPS, based on high-quality evidence.[655,656] Pembrolizumab is also an option for treatment of MSI-H disease.[691] Based on results from KEYNOTE-158,[574] pembrolizumab is also FDA-approved for patients with previously treated TMB-H unresectable or metastatic disease that has progressed following prior treatment with no satisfactory treatment alternatives. Even though the basket trial contained no patients with TMB-H SCCHN, the Panel has included pembrolizumab for TMB-H disease as an option for patients with recurrent or metastatic SCCHN based on the FDA approval. Despite the ambiguities of PD-L1 testing and definitions, PD-L1 expression may be associated with better outcomes from treatment with immunotherapy for recurrent or metastatic SCCHN (ie, greater likelihood of response to pembrolizumab and greater survival benefit in response to nivolumab). The Panel included fam-trastuzumab deruxtecan-nxki for HER2-positive disease (in the subsequent line setting with no satisfactory alternative treatment options) based on the 2024 FDA approval for all solid tumors. However, the DESTINY-PanTumor02 basket trial included <5 patients with non-salivary head and neck cancers.[695] Therefore, this is a category 2B option based on less Panel consensus. Erdafitinib has also been included as an option for non-nasopharyngeal tumors with *FGFR* mutations or fusions and disease progression with at least one line of prior systemic therapy and no availability of an alternative systemic therapy. This is a category 2B recommendation and is based on the single-arm phase II RAGNAR study, which evaluated the efficacy and activity of erdafitinib in 217 previously treated patients with *FGFR*-mutated solid tumors.[696] Only 15 of the 217 patients were diagnosed with SCCHN. Data showed a reduction in tumor burden for 159 (73%) participants. At a median follow-up for efficacy at 17.9 months, 30% (95% CI, 24–36) (n = 64) of participants had an objective response, of which 6 (3%) had a complete response. For all other systemic therapy options recommended by the Panel, there are no clear advantages of one agent over another in the subsequent-line setting, although response rates seem to be highest with taxanes. Afatinib has a PFS benefit, but not an OS benefit, over methotrexate[693] and is a category 2B systemic therapy option for non-nasopharyngeal persistent H&N cancer or cancer that has progressed on or after platinum-containing chemotherapy.

Occult Primary Cancer

Occult or unknown primary H&N cancer is defined as metastatic carcinoma in a cervical lymph node without an identifiable primary site after appropriate investigation. This is an uncommon disease entity, accounting for approximately 5% of patients presenting to referral centers. The most frequent histology is squamous cell carcinoma. Although patients with very small tonsil and tongue base cancers frequently present with enlarged neck nodes and are initially classified as having an unknown primary, most will eventually be diagnosed by directed biopsy and tonsillectomy. The emergence of the primary site after therapy and during follow up is rare. H&N cancer of unknown primary site is a highly curable disease. After appropriate evaluation and treatment, most patients experience low morbidity and long-term disease control.

Workup

The majority of patients >40 years of age who present with a neck mass prove to have malignant lymph node involvement. In situations where metastatic carcinoma is found in cervical lymph nodes, the primary site is almost always discovered in the course of a complete H&N examination and imaging evaluation. FNA is the preferred diagnostic procedure when a malignant cervical lymph node is suspected. FNA obtained from cystic and

Discussion update in progress

Version 1.2026 © 2025 National Comprehensive Cancer Network© (NCCN©), All rights reserved. NCCN Guidelines® and this illustration may not be reproduced in any form without the express written permission of NCCN.

PLEASE NOTE that use of this NCCN Content is governed by the End-User License Agreement, and you MAY NOT distribute this Content or use it with any artificial intelligence model or tool.
Printed by Galya Basol Kochav on 1/4/2026 9:40:35 AM. Copyright © 2026 National Comprehensive Cancer Network, Inc. All Rights Reserved.

necrotic lymph nodes may be non-diagnostic, and, in these situations, a core biopsy may be obtained. Open biopsy should not be performed unless the patient is prepared for definitive surgical management of the malignancy, which may entail a neck dissection, and patients should be counseled accordingly in the preoperative period.

Patients with a biopsy-proven carcinoma of a cervical lymph node require a thorough history with emphasis on tobacco exposure, prior cancer history, including previously resected early-stage cutaneous malignancies, and ethnic descent from endemic NPC regions. A physical examination documenting cervical lymph node levels may inform potential primary sites. These patients require dedicated imaging of the H&N. This can be accomplished through contrast-enhanced CT imaging. An FDG-PET/CT may reveal a primary site not visible on contrast-enhanced CT imaging.[697,698]

When a needle biopsy shows squamous cell carcinoma, adenocarcinoma, or anaplastic/undifferentiated epithelial cancer without a primary site, additional studies are needed (see *Occult Primary* in the NCCN Guidelines for Head and Neck Cancers). High-risk HPV and EBV testing are recommended for squamous cell or undifferentiated histology, and p16+ unknown primary disease should only be considered HPV-positive with HPV-specific testing.[566,699-703] High-risk HPV and EBV testing can be useful in workup and management of cancers of the neck of unknown primary, and patients with EBV- or HPV-related cervical adenopathy are staged according to the classification for nasopharyngeal and HPV-positive oropharyngeal cancer, respectively.[704,705]

A thorough operative examination of at-risk mucosal sites is an important component in the workup of a patient with an occult primary, especially in scenarios where CT or PET imaging do not reveal the primary site. During this procedure, directed biopsies of areas of mucosal abnormalities suspicious for the primary site are undertaken. Randomly directed biopsies of normal-appearing mucosa in potential primary sites have a low yield and seldom disclose a primary cancer. Many primary cancers are identified after tonsillectomy. However, the therapeutic benefit of this surgery is uncertain because, when patients have been treated without tonsillectomy, only a few develop a clinically significant primary tumor.

Treatment

Neck dissection is recommended for all patients with thyroglobulin-negative and calcitonin-negative adenocarcinoma (see *Occult Primary* in the NCCN Guidelines for Head and Neck Cancers). If the metastatic adenocarcinoma presents high in the neck, parotidectomy may be included with the neck dissection. After neck dissection, management depends on the findings (ie, N1 without extranodal extension, N2 or N3 without extranodal extension, or extranodal extension) (see *Occult Primary* in the NCCN Guidelines for Head and Neck Cancers).

Due to the infrequency of this disease, high-level prospective evidence to guide clinical management is lacking. Among NCCN Member Institutions, significant variation exists regarding the management of squamous cell carcinoma, poorly differentiated or nonkeratinizing squamous cell carcinoma, anaplastic cancer (not thyroid) of unknown primary site, or other uncommon histologies. The Panel members believe such patients should be treated with a neck dissection. RT is also an option for patients with N1 disease, as a retrospective single-institution study showed that IMRT in patients with cervical lymph node metastasis from an unknown primary was associated with good local control and survival outcomes.[706] Among N2–3 squamous cell carcinomas with occult primary that are not managed surgically, recommendations are based on less Panel consensus: concurrent systemic therapy/RT (category 2B) or induction chemotherapy followed by chemoradiation or RT (category 3). A neck dissection may be recommended after treatment with RT and/or systemic

Discussion update in progress

Version 1.2026 © 2025 National Comprehensive Cancer Network© (NCCN©), All rights reserved. NCCN Guidelines® and this illustration may not be reproduced in any form without the express written permission of NCCN.

PLEASE NOTE that use of this NCCN Content is governed by the End-User License Agreement, and you MAY NOT distribute this Content or use it with any artificial intelligence model or tool.
Printed by Galya Basol Kochav on 1/4/2026 9:40:35 AM. Copyright © 2026 National Comprehensive Cancer Network, Inc. All Rights Reserved.

therapy, depending on the clinical response. Since HPV-positive occult primary is likely located in the tonsil or base of tongue regions, radiation targets may be limited to these mucosal regions (see *Cancer of the Oropharynx [p16 (HPV)-positive]* in the NCCN Guidelines for Head and Neck Cancers).[433]

Postoperative therapy among patients with occult primary squamous cell carcinoma is based on the amount of nodal disease and the presence or absence of extranodal extension. For N1 disease without extranodal extension, NCCN Panel members recommend either: 1) RT that encompasses the target volume; or 2) careful observation with regular H&N examinations. Postoperative RT or consideration of concurrent chemoradiation (category 2B for chemoradiation) is recommended for N2 or N3 disease without extranodal extension (see *Occult Primary* in the NCCN Guidelines for Head and Neck Cancers). For extranodal extension, concurrent chemoradiation is a category 1 recommendation; RT alone is an option (see *Occult Primary* in the NCCN Guidelines for Head and Neck Cancers).[138,139]

Definitive and postoperative treatment of EBV-positive disease should be treated as nasopharyngeal cancer (see *Cancer of the Nasopharynx* in the NCCN Guidelines for Head and Neck Cancers).[707]

Salivary Gland Tumors

Salivary gland tumors can arise in the major salivary glands (ie, parotid, submandibular, sublingual) or in one of the minor salivary glands, which are widely spread throughout the aerodigestive tract.[708] Many minor salivary gland tumors are located on the hard palate. Approximately 20% of the parotid gland tumors are malignant; the incidence of malignancy in submandibular and minor salivary gland tumors is approximately 50% and 80%, respectively. These malignant tumors constitute a broad spectrum of histologic types, including mucoepidermoid, acinic, adenocarcinoma, adenoid cystic carcinoma, malignant myoepithelial tumors, and squamous cell carcinoma. The primary diagnosis of squamous cell carcinoma of the parotid gland is rare; however, the parotid gland is a frequent site of metastasis from skin cancer.[709] Prognosis and tendency to metastasize vary among these histologic types. Major prognostic factors are histologic grade, tumor size, and local invasion. Staging is done using the AJCC Cancer Staging Manual (8th edition).[400]

Treatment

The major therapeutic approach for salivary gland tumors is adequate and appropriate surgical resection.[710-713] Surgical intervention requires careful planning and execution, particularly in parotid tumor surgery because the facial nerve is in the gland. The gland should be preserved if the nerve is not directly involved by the tumor. Most parotid gland tumors are located in the superficial lobe. If the facial nerve is functioning preoperatively, the nerve can be preserved in most patients.[714] The facial nerve should be sacrificed if there is preoperative facial nerve involvement with facial palsy or if there is direct invasion of the tumor into the nerve where the tumor cannot be separated from the nerve. Malignant deep lobe parotid tumors are rare; however, they are generally a challenge for the surgeon because the patient may require superficial parotidectomy and identification and retraction of the facial nerve to remove the deep lobe parotid tumor.

The Panel recommends highly conformal RT techniques such as IMRT, proton, or other heavy ions for definitive radiation treatment. Results from a retrospective cohort study including 545 patients with salivary gland tumors treated between 1997 and 2010 showed better local control and survival outcomes with neutron therapy, relative to photon therapy.[715] However, risk of late effects with neutron therapy is high and tends to increase over time, with estimates as high as 20% at 9 years.[716,717] Neutron therapy is no longer routinely recommended for treatment of salivary gland cancers due to the diminishing demand, concerns regarding

Discussion update in progress

Version 1.2026 © 2025 National Comprehensive Cancer Network© (NCCN©), All rights reserved. NCCN Guidelines® and this illustration may not be reproduced in any form without the express written permission of NCCN.

PLEASE NOTE that use of this NCCN Content is governed by the End-User License Agreement, and you MAY NOT distribute this Content or use it with any artificial intelligence model or tool.
Printed by Galya Basol Kochav on 1/4/2026 9:40:35 AM. Copyright © 2026 National Comprehensive Cancer Network, Inc. All Rights Reserved.

the methodologic robustness of available randomized trial data, and closure of all but one center in the United States. The panel recognizes the potential clinical value of neutron therapy for select patients.

Most malignant deep lobe parotid tumors will require postoperative RT because of adverse pathologic features such as the limitations of surgical margins in the resection of these tumors.[710,712,718] RT is also used in an adjuvant setting for tumors with other adverse pathologic features (eg, intermediate, high-grade, T3–4 tumors, or positive lymph nodes)[711,719,720]; systemic therapy/RT (category 2B) can also be considered.[721] Efficacy data for systemic therapy/RT for patients with advanced salivary gland tumors that have been resected are limited. Extensive safety data are available and may be extrapolated from the management of SCCHN, with some NCCN Member Institutions using platinum-based regimens for these patients. With regard to unresectable salivary gland tumors, the NCCN Panel had less consensus about chemoradiation (which is reflected in the category 2B recommendations), because there are few published trials. Clinical trials are ongoing in this area (eg, NCT01220583, NCT02776163).

Systemic Therapy

Targeted systemic therapy is increasingly becoming an option for patients with distant metastatic salivary gland tumors. NGS and other biomarker tests should be used to evaluate at least the following: AR, *NTRK, FGFR*, BRAF, RET, MSI, dMMR, TMB, PD-L1, and HER2 status.[574,696,722-733] Since HER2-testing guidelines are currently not available for patients with salivary gland cancers, the Panel refers to the ASCO/CAP guidelines for HER2-testing of breast cancers (https://www.cap.org/protocols-and-guidelines/cap-guidelines/current-cap-guidelines/recommendations-for-human-epidermal-growth-factor-2-testing-in-breast-cancer).

A significant number of advanced salivary gland tumors with distant metastases are androgen receptor-positive (AR+).[724-728] Therefore, the Panel recommends that patients with tumors that are AR+ receive androgen receptor therapy (ie, leuprolide, bicalutamide, abiraterone, goserelin).[728,734-737]

Two phase I/II studies including patients with advanced *NTRK* gene fusion-positive cancer (with 22%–38% being salivary gland tumors) showed promising objective response rates of 75% to 100% with the TRK inhibitor larotrectinib.[729,730] A pooled analysis from a phase II trial and two phase I trials including 54 patients with *NTRK* gene fusion-positive cancer (13% being mammary analogue secretory carcinoma of the salivary gland) showed an objective response rate of 57.4% for entrectinib, another TRK inhibitor.[731] Finally, repotrectinib was evaluated in a phase I/II study including 88 patients with NTRK gene fusion-positive advanced solid tumors (48 previously treated with a TRK TKI, and 40 who were TRK TKI-naïve).[738] Eleven patients (12.5%) had a salivary gland tumor. The analysis showed an objective response rate of 58% for those who were TRK TKI-naïve, and 50% in those who were previously treated with a TRK TKI. The FDA approved larotrectinib, entrectinib, and repotrectinib for treatment of patients with *NTRK* gene fusion-positive tumors, and the Panel also recommends these three *NTRK* therapy options for patients with recurrent *NTRK* gene fusion-positive salivary gland tumors and distant metastases.

HER2 positivity has also been found in some advanced salivary gland tumors.[726,728,739] It is recommended that these patients receive a HER2-targeted treatment option such as trastuzumab.[728,740] Small series demonstrate that ado-trastuzumab emtansine may be active in patients with previously treated metastatic HER2-positive salivary gland cancers.[741,742] Nonrandomized phase II trials have also examined trastuzumab combined with other agents for patients with advanced HER2-positive salivary gland cancers. For example, results from an open-label, single-center, phase II Japanese study including 57 patients with recurrent or metastatic HER2-positive salivary gland cancer showed that

Discussion update in progress

Version 1.2026 © 2025 National Comprehensive Cancer Network© (NCCN©), All rights reserved. NCCN Guidelines® and this illustration may not be reproduced in any form without the express written permission of NCCN.

PLEASE NOTE that use of this NCCN Content is governed by the End-User License Agreement, and you MAY NOT distribute this Content or use it with any artificial intelligence model or tool.
Printed by Galya Basol Kochav on 1/4/2026 9:40:35 AM. Copyright © 2026 National Comprehensive Cancer Network, Inc. All Rights Reserved.

trastuzumab combined with docetaxel was associated with a 70.2% ORR (95% CI, 56.6%–81.6%).[743] Complete response was reached in 14% of patients, partial response was reached in 56.1%, and stable disease was observed in 24.6%. The median PFS was 8.9 months (95% CI, 7.8–9.9), and OS was 39.7 months (95% CI, not reached). A significant number of grade 3 or 4 adverse events were reported in this study (89%, with grade 4 adverse events being reported in 61%). The most common serious adverse events were hematologic: decreased white blood cell, neutrophil, and lymphocyte counts. Results from the ongoing open-label phase II MyPathway basket study, including 16 patients with advanced HER2-positive, -overexpressed, or -amplified salivary gland cancers, showed that pertuzumab combined with trastuzumab was associated with a 60% ORR.[744] Median duration of response for these patients was 9.2 months, and the regimen was well-tolerated (ie, only one grade 3 treatment-related adverse event). In a pooled analysis of two studies including 17 patients with HER2-positive salivary duct carcinoma, fam-trastuzumab deruxtecan-nxki was associated with an ORR of 47% (all partial responses).[745] Results are currently only available in abstract form. Fam-trastuzumab deruxtecan-nxki is also supported by a dose-expansion, phase I study that included 8 participants with salivary gland tumors.[746]

Pembrolizumab is an option for patients with previously treated TMB-H, MSI-H/dMMR recurrent, unresectable, or metastatic salivary gland cancer, based on results from the phase II KEYNOTE-158 trial, which included three patients with salivary gland cancer and TMB-H (≥10 mut/Mb) disease[574] and two patients with MSI-H/dMMR advanced salivary gland cancer.[691] Combination dabrafenib/trametinib is FDA-approved for all advanced *BRAF* V600E-mutated tumors, and a case report supports its use for widely metastatic salivary duct carcinoma that is *BRAF* V600E-mutated.[732] Similarly, selpercatinib is FDA-approved for all locally advanced or metastatic *RET* gene fusion-positive solid tumors, and its use for patients with recurrent, unresectable, or metastatic salivary gland cancer is supported by the ongoing phase I/II LIBRETTO-001 trial, which, at the time of the most recent analysis, included 4 patients with a salivary gland tumor and an ORR of 50% for these patients (independent review committee assessment).[733] Erdafitinib has also been included as an option for recurrent, unresectable, or metastatic salivary gland tumors with *FGFR* mutations or fusions (category 2B).[696] A 100% ORR and DCR were reported for the five individuals with salivary gland tumors included in the phase IIb RAGNAR study.

Other systemic therapy options may be used for palliation in advanced disease. Various combinations of chemotherapy agents (ie, cisplatin/cyclophosphamide/doxorubicin, cisplatin/vinorelbine, carboplatin/paclitaxel, carboplatin/gemcitabine) have been shown in small series to be active for some salivary gland malignant histologies, with ORRs ranging from 24% to 60%.[747-751] A small phase II trial also supports use of paclitaxel monotherapy based on an RR of 26% for patients with mucoepidermoid or adenocarcinoma histology; no responses were observed for adenoid cystic carcinoma.[752] Use of certain tyrosine kinase inhibitors such as axitinib (with or without avelumab) and sorafenib have been evaluated in nonrandomized phase II trials[753-755] and are recommended by the panel as category 2B options for patients with unresectable, metastatic, or recurrent salivary gland tumors (useful in certain circumstances). Sunitinib[756] and dovitinib[757] have also been evaluated in phase II trials, but larger trials are needed to determine the efficacy of these options. Lenvatinib as a treatment option for recurrent or metastatic adenoid cystic carcinoma has been evaluated in two phase II trials, which showed disease control rates of 88% (partial response of 11.5%–15.6%, stable disease in 75%–76.9%).[758,759] Based on these results and lack of other evidence-based options for recurrent or metastatic adenoid cystic carcinoma, lenvatinib is a category 2B option.

Discussion update in progress

Version 1.2026 © 2025 National Comprehensive Cancer Network© (NCCN©), All rights reserved. NCCN Guidelines® and this illustration may not be reproduced in any form without the express written permission of NCCN.

PLEASE NOTE that use of this NCCN Content is governed by the End-User License Agreement, and you MAY NOT distribute this Content or use it with any artificial intelligence model or tool.
Printed by Galya Basol Kochav on 1/4/2026 9:40:35 AM. Copyright © 2026 National Comprehensive Cancer Network, Inc. All Rights Reserved.

Mucosal Melanoma of the Head and Neck

MM is a rare but highly aggressive neoplasm with a poor prognosis.[760,761] It occurs throughout the upper aerodigestive tract.[762] Most MM (70%–80%) occur in the nasal cavity or paranasal sinuses, followed by the oral cavity, pharynx, and larynx.[763] The incidence of nasal cavity MM appears to be increasing.[760] Sinonasal MM is typically confined to the primary site at presentation.[764] Oral cavity MM more frequently presents with clinically apparent lymph node metastasis.[765] No etiologic risk factors are yet apparent.

Workup and Staging

The AJCC Cancer Staging Manual (8th edition) includes a staging system for MM (see Table 9).[400] The AJCC staging recognizes two key factors specific to MM: 1) the poor prognosis of MM even with a limited burden of disease from the primary tumor; and 2) there is still some gradation of survival based on the burden of disease as reflected in local, regional, and distant extent. Thus, the AJCC staging system for MM begins with T3, N0 disease as the most limited form of disease (T staging similar to anaplastic thyroid carcinoma), and the staging reflects the local burden of disease, as well as regional and distant extent. In addition, the AJCC staging system reflects the fact that MM occurs at all mucosal sites in the H&N. Therefore, rules for classifying, staging, and surgical principles should be based on the appropriate anatomic site of origin. Workup for these tumors is described in the NCCN Guidelines for Head and Neck Cancers.

Treatment

Although limited data exist on treatment options, primary treatment should be surgical for T3, N0–1 and T4a, N0–1 disease. For T4b disease, although surgery is not generally considered, a multidisciplinary team discussion is suggested to ensure appropriate care.[766] Neck dissection with postoperative radiation is recommended for clinical nodal disease.[767,768] Postoperative radiation to the primary site is typically indicated in most cases, as there is evidence that it improves local control. Postoperative RT to the neck depends on the extent of nodal involvement.[769-771] NCCN strongly encourages clinical trials for all patients with MM to better define treatment choices at all stages of the disease.

Radiation Therapy

The role of RT in MM has not been evaluated in prospective trials. However, results of a randomized trial in cutaneous melanoma are considered relevant to MM in the postoperative setting after surgery at the primary site or neck dissection (see third paragraph in this section).[772] Local recurrence is common after surgery alone in MM. After using postoperative radiation, lower rates of local and neck recurrence have been reported in historical comparison series.[771,773-776] In unresectable or medically inoperable cases, reasonable local control outcomes using RT followed by systemic therapy have been reported in small cohort series of MMs.[777-779]

Primary size or thickness is not used as a risk factor when considering RT to the primary site; all invasive primaries are considered at high risk for local recurrence. For sinonasal primary sites, target volumes may include the primary site without elective treatment of the neck (see *Mucosal Melanoma* in the NCCN Guidelines for Head and Neck Cancers). Because oral cavity primary sites are felt to be at a higher risk for failure in the neck, elective management with neck dissection and/or RT may be applied, although this is not routinely done (see *Mucosal Melanoma* in the NCCN Guidelines for Head and Neck Cancers).

RT is often recommended in the postoperative management of MMs. Indications for postoperative radiation to the neck are generally extrapolated from cutaneous melanoma. An Australian-New Zealand consortium reported on a randomized trial (250 patients) of postoperative RT versus observation in patients with palpable adenopathy from cutaneous primaries. Postoperative RT was associated with a significant

Discussion update in progress

Version 1.2026 © 2025 National Comprehensive Cancer Network© (NCCN©), All rights reserved. NCCN Guidelines® and this illustration may not be reproduced in any form without the express written permission of NCCN.

PLEASE NOTE that use of this NCCN Content is governed by the End-User License Agreement, and you MAY NOT distribute this Content or use it with any artificial intelligence model or tool.
Printed by Galya Basol Kochav on 1/4/2026 9:40:35 AM. Copyright © 2026 National Comprehensive Cancer Network, Inc. All Rights Reserved.

reduction in relapse in the nodal basin (19% vs. 31%) and a significant improvement in lymph node field control.[772] Only 20 patients relapsed who received RT, whereas 34 patients relapsed who were under observation only (P = .04). However, no significant differences in OS were reported.

Considering this trial and retrospective studies in MM, the NCCN Panel recommends postoperative RT for the following high-risk features: extranodal extension, involvement of two or more neck or intraparotid nodes, any node ≥3 cm, or recurrence in the neck or soft tissue after initial surgical resection.[780,781] Conventional fractionation is recommended (at 2 Gy per fraction to a total postoperative dose of 60–66 Gy). The Australian-New Zealand randomized trial used 48 Gy in 20 fractions (240 cGy/fraction) to the neck, axilla, or groin.[772] However, the NCCN Panel prefers conventional fractionation to somewhat higher total doses (60–66 Gy) in the neck because of concerns about late effects from larger dose per fraction, which may not be fully expressed for many years after treatment. The following schedules may also be used: 1) 48–50 Gy (2.4–3 Gy/fraction); or 2) 30–36 Gy (6 Gy/fraction).[772,773,781]

IMRT may be very useful in helping to achieve homogenous dose distributions and to spare critical organs, especially in paranasal sinus sites.[225,636,782] 3D-CRT may also be used, but IMRT is preferred. Reports suggest that the use of hypofractionation in cutaneous melanomas (which is convenient) is associated with good outcomes but no clear advantage in cancer control. Little experience is available using large dose per fraction in mucosal sites. Because of the close proximity of neural structures and risk of late effects, hypofractionation (if used) must be carefully planned and delivered.[782] RT should not be used concurrently with BRAF/MEK inhibitor therapy, as concurrent use has been found to be associated with grade ≥3 dermatologic reactions, and potentially lethal hemorrhaging in the liver, lung, and brain have all been reported.[783] For primary sites in the paranasal sinuses and nasal cavity, PBT should be considered due to the proximity of eye and other vital structures.

Systemic Therapy

Systemic therapy used for cutaneous melanoma (eg, immunotherapy) is recommended for MM (see *Systemic Therapy for Metastatic or Unresectable Disease* in the NCCN Guidelines for Melanoma: Cutaneous, available at www.NCCN.org).

There is currently no standard approach for systemic therapy treatment of resectable MM. Adjuvant systemic immunotherapy is an option for MM with nodal involvement. While the majority of patients in melanoma adjuvant trials had cutaneous primaries, some patients with MM were included. Neoadjuvant checkpoint inhibitor for MM is not well-studied. Recent data suggest, however, that neoadjuvant therapy for resectable MM is a feasible approach with signs of efficacy and an acceptable safety profile. Further investigation is needed.[784] More recently, data demonstrate improvements in event-free survival with neoadjuvant and adjuvant pembrolizumab over adjuvant pembrolizumab alone in patients with resectable stage III/IV melanoma.[785] While this study included only a small number of patients with mucosal melanoma, it is not known whether this approach is of value for this particular melanoma subtype, though it may be useful in certain situations (ie, large symptomatic disease burden).

Follow-up

Recommendations for surveillance are provided in the algorithm (see *Follow-up Recommendations* in the NCCN Guidelines for Head and Neck Cancers). Note that physical examination for MM should include endoscopic inspection for nasal cavity and paranasal sinus disease.

Discussion update in progress

Version 1.2026 © 2025 National Comprehensive Cancer Network© (NCCN©), All rights reserved. NCCN Guidelines® and this illustration may not be reproduced in any form without the express written permission of NCCN.

PLEASE NOTE that use of this NCCN Content is governed by the End-User License Agreement, and you MAY NOT distribute this Content or use it with any artificial intelligence model or tool.
Printed by Galya Basol Kochav on 1/4/2026 9:40:35 AM. Copyright © 2026 National Comprehensive Cancer Network, Inc. All Rights Reserved.

Figure 1: Anatomic Sites and Subsites of the Head and Neck

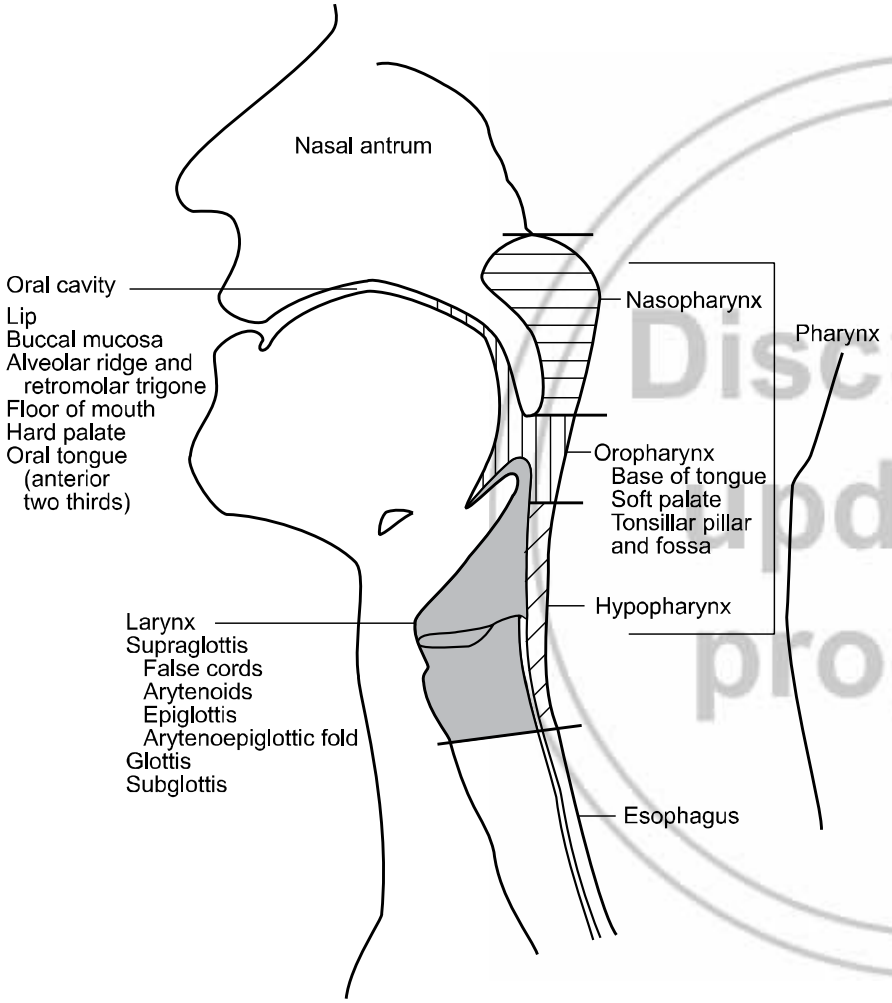

Reprinted with permission from CMP Healthcare Media. Source: Cancer Management: A Multidisciplinary Approach, 9th ed. Pazdur R, Coia L, Hoskins W, et al (eds), Chapter 4. Copyright 2005, All rights reserved.

Figure 2: Level Designation for Cervical Lymphatics in the Right Neck

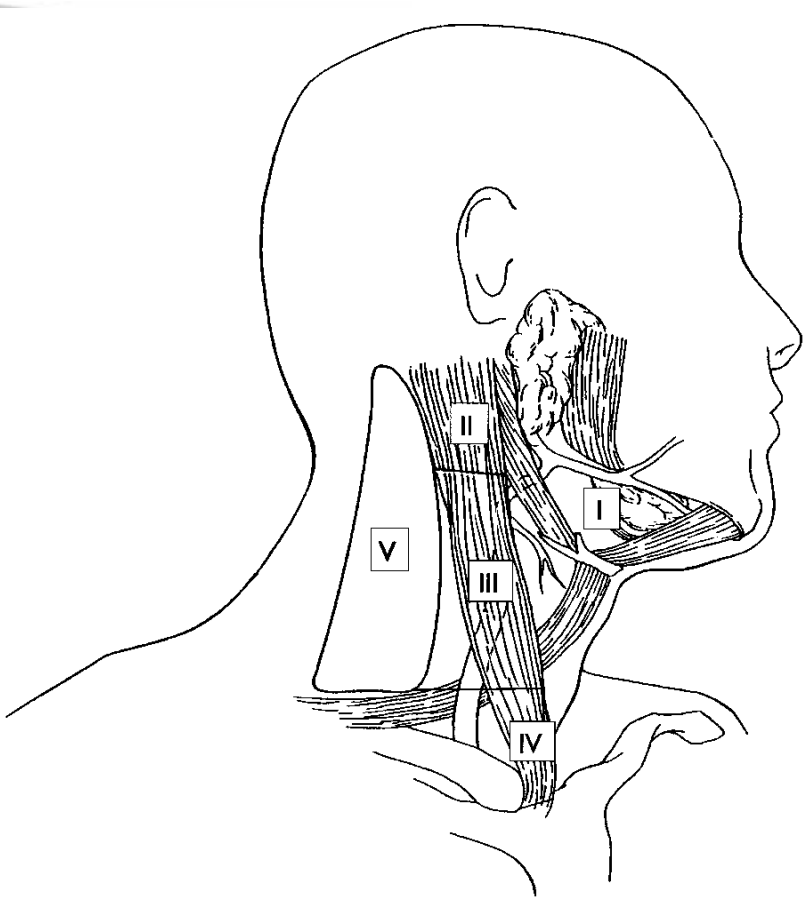

Reprinted with permission from CMP Healthcare Media. Source: Cancer Management: A Multidisciplinary Approach, 9th ed. Pazdur R, Coia L, Hoskins W, et al (eds), Chapter 4. Copyright 2005, All rights reserved.

Version 1.2026 © 2025 National Comprehensive Cancer Network© (NCCN©), All rights reserved. NCCN Guidelines® and this illustration may not be reproduced in any form without the express written permission of NCCN.

PLEASE NOTE that use of this NCCN Content is governed by the End-User License Agreement, and you MAY NOT distribute this Content or use it with any artificial intelligence model or tool.
Printed by Galya Basol Kochav on 1/4/2026 9:40:35 AM. Copyright © 2026 National Comprehensive Cancer Network, Inc. All Rights Reserved.

References

1. Siegel RL, Kratzer TB, Giaquinto AN, et al. Cancer statistics, 2025. CA Cancer J Clin 2025;75:10–45. Available at: https://www.ncbi.nlm.nih.gov/pubmed/39817679.

2. Gillison ML, Koch WM, Capone RB, et al. Evidence for a causal association between human papillomavirus and a subset of head and neck cancers. J Natl Cancer Inst 2000;92:709–720. Available at: http://www.ncbi.nlm.nih.gov/pubmed/10793107.

3. Applebaum KM, Furniss CS, Zeka A, et al. Lack of association of alcohol and tobacco with HPV16-associated head and neck cancer. J Natl Cancer Inst 2007;99:1801–1810. Available at: http://www.ncbi.nlm.nih.gov/pubmed/18042931.

4. D'Souza G, Kreimer AR, Viscidi R, et al. Case-control study of human papillomavirus and oropharyngeal cancer. N Engl J Med 2007;356:1944–1956. Available at: http://www.ncbi.nlm.nih.gov/pubmed/17494927.

5. Schlecht NF, Burk RD, Adrien L, et al. Gene expression profiles in HPV-infected head and neck cancer. J Pathol 2007;213:283–293. Available at: http://www.ncbi.nlm.nih.gov/pubmed/17893858.

6. Sturgis EM, Cinciripini PM. Trends in head and neck cancer incidence in relation to smoking prevalence: an emerging epidemic of human papillomavirus-associated cancers? Cancer 2007;110:1429–1435. Available at: http://www.ncbi.nlm.nih.gov/pubmed/17724670.

7. Adelstein DJ, Ridge JA, Gillison ML, et al. Head and neck squamous cell cancer and the human papillomavirus: summary of a National Cancer Institute State of the Science Meeting, November 9-10, 2008, Washington, D.C. Head Neck 2009;31:1393–1422. Available at: http://www.ncbi.nlm.nih.gov/pubmed/19787782.

8. Agalliu I, Gapstur S, Chen Z, et al. Associations of oral alpha-, beta-, and gamma-human papillomavirus types with risk of incident head and neck cancer. JAMA Oncol 2016;2:599–606. Available at: https://www.ncbi.nlm.nih.gov/pubmed/26794505.

9. Snow AN, Laudadio J. Human papillomavirus detection in head and neck squamous cell carcinomas. Adv Anat Pathol 2010;17:394–403. Available at: https://www.ncbi.nlm.nih.gov/pubmed/20966645.

10. Chen X, Gao L, Sturgis EM, et al. HPV16 DNA and integration in normal and malignant epithelium: implications for the etiology of laryngeal squamous cell carcinoma. Ann Oncol 2017;28:1105–1110. Available at: https://www.ncbi.nlm.nih.gov/pubmed/28327951.

11. Ren J, Yang W, Su J, et al. Human papillomavirus and p16 immunostaining, prevalence and prognosis of squamous carcinoma of unknown primary in the head and neck region. Int J Cancer 2019;145:1465–1474. Available at: https://www.ncbi.nlm.nih.gov/pubmed/30698281.

12. Liao CI, Francoeur AA, Kapp DS, et al. Trends in human papillomavirus-associated cancers, demographic characteristics, and vaccinations in the US, 2001-2017. JAMA Netw Open 2022;5:e222530. Available at: https://www.ncbi.nlm.nih.gov/pubmed/35294540.

13. Chaturvedi AK, Engels EA, Anderson WF, Gillison ML. Incidence trends for human papillomavirus-related and -unrelated oral squamous cell carcinomas in the United States. J Clin Oncol 2008;26:612–619. Available at: http://www.ncbi.nlm.nih.gov/pubmed/18235120.

14. Chaturvedi AK, Engels EA, Pfeiffer RM, et al. Human papillomavirus and rising oropharyngeal cancer incidence in the United States. J Clin Oncol 2011;29:4294–4301. Available at: http://www.ncbi.nlm.nih.gov/pubmed/21969503.

15. Gillison ML, Broutian T, Pickard RK, et al. Prevalence of oral HPV infection in the United States, 2009-2010. JAMA 2012;307:693–703. Available at: http://www.ncbi.nlm.nih.gov/pubmed/22282321.

16. Nasman A, Attner P, Hammarstedt L, et al. Incidence of human papillomavirus (HPV) positive tonsillar carcinoma in Stockholm, Sweden: an epidemic of viral-induced carcinoma? Int J Cancer 2009;125:362–366. Available at: http://www.ncbi.nlm.nih.gov/pubmed/19330833.

Discussion update in progress

Version 1.2026 © 2025 National Comprehensive Cancer Network© (NCCN©), All rights reserved. NCCN Guidelines® and this illustration may not be reproduced in any form without the express written permission of NCCN.

PLEASE NOTE that use of this NCCN Content is governed by the End-User License Agreement, and you MAY NOT distribute this Content or use it with any artificial intelligence model or tool.
Printed by Galya Basol Kochav on 1/4/2026 9:40:35 AM. Copyright © 2026 National Comprehensive Cancer Network, Inc. All Rights Reserved.

17. Mehanna H, Beech T, Nicholson T, et al. Prevalence of human papillomavirus in oropharyngeal and nonoropharyngeal head and neck cancer--systematic review and meta-analysis of trends by time and region. Head Neck 2013;35:747–755. Available at: https://www.ncbi.nlm.nih.gov/pubmed/22267298.

18. D'Souza G, Zhang HH, D'Souza WD, et al. Moderate predictive value of demographic and behavioral characteristics for a diagnosis of HPV16-positive and HPV16-negative head and neck cancer. Oral Oncol 2010;46:100–104. Available at: https://www.ncbi.nlm.nih.gov/pubmed/20036610.

19. Lu DJ, Luu M, Mita A, et al. Human papillomavirus-associated oropharyngeal cancer among patients aged 70 and older: Dramatically increased prevalence and clinical implications. Eur J Cancer 2018;103:195–204. Available at: https://www.ncbi.nlm.nih.gov/pubmed/30268920.

20. Tota JE, Best AF, Zumsteg ZS, et al. Evolution of the oropharynx cancer epidemic in the United States: moderation of increasing incidence in younger individuals and shift in the burden to older individuals. J Clin Oncol 2019;37:1538–1546. Available at: https://www.ncbi.nlm.nih.gov/pubmed/31026209.

21. Gillison ML, Alemany L, Snijders PJ, et al. Human papillomavirus and diseases of the upper airway: head and neck cancer and respiratory papillomatosis. Vaccine 2012;30 Suppl 5:F34–54. Available at: http://www.ncbi.nlm.nih.gov/pubmed/23199965.

22. Ndiaye C, Mena M, Alemany L, et al. HPV DNA, E6/E7 mRNA, and p16INK4a detection in head and neck cancers: a systematic review and meta-analysis. Lancet Oncol 2014;15:1319–1331. Available at: https://www.ncbi.nlm.nih.gov/pubmed/25439690.

23. LeConte BA, Szaniszlo P, Fennewald SM, et al. Differences in the viral genome between HPV-positive cervical and oropharyngeal cancer. PLoS One 2018;13:e0203403. Available at: https://www.ncbi.nlm.nih.gov/pubmed/30161236.

24. Steinau M, Saraiya M, Goodman MT, et al. Human papillomavirus prevalence in oropharyngeal cancer before vaccine introduction, United States. Emerg Infect Dis 2014;20:822–828. Available at: https://www.ncbi.nlm.nih.gov/pubmed/24751181.

25. da Silva RL, da Silva Batista Z, Bastos GR, et al. Role of HPV 16 variants among cervical carcinoma samples from Northeastern Brazil. BMC Womens Health 2020;20:162. Available at: https://www.ncbi.nlm.nih.gov/pubmed/32738888.

26. Gillison ML, Akagi K, Xiao W, et al. Human papillomavirus and the landscape of secondary genetic alterations in oral cancers. Genome Res 2019;29:1–17. Available at: https://www.ncbi.nlm.nih.gov/pubmed/30563911.

27. Chaturvedi AK, Graubard BI, Broutian T, et al. Effect of prophylactic human papillomavirus (HPV) vaccination on oral HPV infections among young adults in the United States. J Clin Oncol 2018;36:262–267. Available at: https://www.ncbi.nlm.nih.gov/pubmed/29182497.

28. Chaturvedi AK, Graubard BI, Broutian T, et al. Prevalence of oral HPV infection in unvaccinated men and women in the United States, 2009-2016. JAMA 2019;322:977–979. Available at: https://www.ncbi.nlm.nih.gov/pubmed/31503300.

29. Future II Study Group. Quadrivalent vaccine against human papillomavirus to prevent high-grade cervical lesions. N Engl J Med 2007;356:1915–1927. Available at: https://www.ncbi.nlm.nih.gov/pubmed/17494925.

30. Beachler DC, Kreimer AR, Schiffman M, et al. Multisite HPV16/18 vaccine efficacy against cervical, anal, and oral HPV infection. J Natl Cancer Inst 2016;108:djv302. Available at: https://www.ncbi.nlm.nih.gov/pubmed/26467666.

31. Lei J, Ploner A, Elfstrom KM, et al. HPV vaccination and the risk of invasive cervical cancer. N Engl J Med 2020;383:1340–1348. Available at: https://www.ncbi.nlm.nih.gov/pubmed/32997908.

Discussion update in progress

Version 1.2026 © 2025 National Comprehensive Cancer Network© (NCCN©), All rights reserved. NCCN Guidelines® and this illustration may not be reproduced in any form without the express written permission of NCCN.

PLEASE NOTE that use of this NCCN Content is governed by the End-User License Agreement, and you MAY NOT distribute this Content or use it with any artificial intelligence model or tool.
Printed by Galya Basol Kochav on 1/4/2026 9:40:35 AM. Copyright © 2026 National Comprehensive Cancer Network, Inc. All Rights Reserved.

32. Ang KK, Harris J, Wheeler R, et al. Human papillomavirus and survival of patients with oropharyngeal cancer. N Engl J Med 2010;363:24–35. Available at: http://www.ncbi.nlm.nih.gov/pubmed/20530316.

33. Rischin D, Young RJ, Fisher R, et al. Prognostic significance of p16INK4A and human papillomavirus in patients with oropharyngeal cancer treated on TROG 02.02 phase III trial. J Clin Oncol 2010;28:4142–4148. Available at: http://www.ncbi.nlm.nih.gov/pubmed/20697079.

34. Fakhry C, Zhang Q, Nguyen-Tan PF, et al. Human papillomavirus and overall survival after progression of oropharyngeal squamous cell carcinoma. J Clin Oncol 2014;32:3365–3373. Available at: http://www.ncbi.nlm.nih.gov/pubmed/24958820.

35. Posner MR, Lorch JH, Goloubeva O, et al. Survival and human papillomavirus in oropharynx cancer in TAX 324: a subset analysis from an international phase III trial. Ann Oncol 2011;22:1071–1077. Available at: https://www.ncbi.nlm.nih.gov/pubmed/21317223.

36. Fakhry C, Zhang Q, Nguyen-Tan PF, et al. Development and validation of nomograms predictive of overall and progression-free survival in patients with oropharyngeal cancer. J Clin Oncol 2017;35:4057–4065. Available at: https://www.ncbi.nlm.nih.gov/pubmed/28777690.

37. Fullerton ZH, Butler SS, Mahal BA, et al. Short-term mortality risks among patients with oropharynx cancer by human papillomavirus status. Cancer 2020;126:1424–1433. Available at: https://www.ncbi.nlm.nih.gov/pubmed/31930488.

38. Fakhry C, Westra WH, Li S, et al. Improved survival of patients with human papillomavirus-positive head and neck squamous cell carcinoma in a prospective clinical trial. J Natl Cancer Inst 2008;100:261–269. Available at: http://www.ncbi.nlm.nih.gov/pubmed/18270337.

39. Lassen P, Eriksen JG, Hamilton-Dutoit S, et al. Effect of HPV-associated p16INK4A expression on response to radiotherapy and survival in squamous cell carcinoma of the head and neck. J Clin Oncol 2009;27:1992–1998. Available at: http://www.ncbi.nlm.nih.gov/pubmed/19289615.

40. Mehanna H, Taberna M, von Buchwald C, et al. Prognostic implications of p16 and HPV discordance in oropharyngeal cancer (HNCIG-EPIC-OPC): a multicentre, multinational, individual patient data analysis. Lancet Oncol 2023;24:239–251. Available at: https://www.ncbi.nlm.nih.gov/pubmed/36796393.

41. Coordes A, Lenz K, Qian X, et al. Meta-analysis of survival in patients with HNSCC discriminates risk depending on combined HPV and p16 status. Eur Arch Otorhinolaryngol 2016;273:2157–2169. Available at: https://www.ncbi.nlm.nih.gov/pubmed/26227616.

42. Jordan RC, Lingen MW, Perez-Ordonez B, et al. Validation of methods for oropharyngeal cancer HPV status determination in US cooperative group trials. Am J Surg Pathol 2012;36:945–954. Available at: http://www.ncbi.nlm.nih.gov/pubmed/22743284.

43. Ramkumar SP, Simpson MC, Adjei Boakye E, et al. High-risk human papillomavirus 16/18 associated with improved survival in sinonasal squamous cell carcinoma. Cancer 2023;129:1372–1383. Available at: https://www.ncbi.nlm.nih.gov/pubmed/36808090.

44. Gillison ML, Zhang Q, Jordan R, et al. Tobacco smoking and increased risk of death and progression for patients with p16-positive and p16-negative oropharyngeal cancer. J Clin Oncol 2012;30:2102–2111. Available at: http://www.ncbi.nlm.nih.gov/pubmed/22565003.

45. Sinha P, Lewis JS, Jr., Piccirillo JF, et al. Extracapsular spread and adjuvant therapy in human papillomavirus-related, p16-positive oropharyngeal carcinoma. Cancer 2012;118:3519–3530. Available at: http://www.ncbi.nlm.nih.gov/pubmed/22086669.

46. Lassen P, Lacas B, Pignon JP, et al. Prognostic impact of HPV-associated p16-expression and smoking status on outcomes following radiotherapy for oropharyngeal cancer: The MARCH-HPV project. Radiother Oncol 2018;126:107–115. Available at: https://www.ncbi.nlm.nih.gov/pubmed/29100700.

47. Spector ME, Gallagher KK, Light E, et al. Matted nodes: poor prognostic marker in oropharyngeal squamous cell carcinoma

Discussion update in progress

Version 1.2026 © 2025 National Comprehensive Cancer Network© (NCCN©), All rights reserved. NCCN Guidelines® and this illustration may not be reproduced in any form without the express written permission of NCCN.

PLEASE NOTE that use of this NCCN Content is governed by the End-User License Agreement, and you MAY NOT distribute this Content or use it with any artificial intelligence model or tool.
Printed by Galya Basol Kochav on 1/4/2026 9:40:35 AM. Copyright © 2026 National Comprehensive Cancer Network, Inc. All Rights Reserved.

independent of HPV and EGFR status. Head Neck 2012;34:1727–1733. Available at: https://www.ncbi.nlm.nih.gov/pubmed/22247002.

48. O'Sullivan B, Huang SH, Siu LL, et al. Deintensification candidate subgroups in human papillomavirus-related oropharyngeal cancer according to minimal risk of distant metastasis. J Clin Oncol 2013;31:543–550. Available at: http://www.ncbi.nlm.nih.gov/pubmed/23295795.

49. Vainshtein JM, Spector ME, Ibrahim M, et al. Matted nodes: High distant-metastasis risk and a potential indication for intensification of systemic therapy in human papillomavirus-related oropharyngeal cancer. Head Neck 2016;38 Suppl 1:E805–814. Available at: https://www.ncbi.nlm.nih.gov/pubmed/25914344.

50. Huang SH, O'Sullivan B, Su J, et al. Prognostic importance of radiologic extranodal extension in HPV-positive oropharyngeal carcinoma and its potential role in refining TNM-8 cN-classification. Radiother Oncol 2020;144:13–22. Available at: https://www.ncbi.nlm.nih.gov/pubmed/31710939.

51. Wuthrick EJ, Zhang Q, Machtay M, et al. Institutional clinical trial accrual volume and survival of patients with head and neck cancer. J Clin Oncol 2015;33:156–164. Available at: https://www.ncbi.nlm.nih.gov/pubmed/25488965.

52. David JM, Ho AS, Luu M, et al. Treatment at high-volume facilities and academic centers is independently associated with improved survival in patients with locally advanced head and neck cancer. Cancer 2017;123:3933–3942. Available at: https://www.ncbi.nlm.nih.gov/pubmed/28640546.

53. Gourin CG, Stewart CM, Frick KD, et al. Association of hospital volume with laryngectomy outcomes in patients with larynx cancer. JAMA Otolaryngol Head Neck Surg 2019;145:62–70. Available at: https://www.ncbi.nlm.nih.gov/pubmed/30476965.

54. Nocon CC, Ajmani GS, Bhayani MK. Association of facility volume with positive margin rate in the surgical treatment of head and neck cancer. JAMA Otolaryngol Head Neck Surg 2018;144:1090–1097. Available at: https://www.ncbi.nlm.nih.gov/pubmed/30347018.

55. Lee NCJ, Kelly JR, An Y, et al. Radiation therapy treatment facility and overall survival in the adjuvant setting for locally advanced head and neck squamous cell carcinoma. Cancer 2019;125:2018–2026. Available at: https://www.ncbi.nlm.nih.gov/pubmed/30748002.

56. Trakimas DR, Mydlarz W, Mady LJ, et al. Increasing radiation therapy and lower survival for human papillomavirus-related oropharynx cancer associated with a shift to community cancer center care. J Natl Cancer Inst 2024;116:1051–1062. Available at: https://www.ncbi.nlm.nih.gov/pubmed/38167712.

57. Cohen EE, LaMonte SJ, Erb NL, et al. American Cancer Society Head and Neck Cancer Survivorship Care Guideline. CA Cancer J Clin 2016;66:203–239. Available at: https://www.ncbi.nlm.nih.gov/pubmed/27002678.

58. Jabbour J, Milross C, Sundaresan P, et al. Education and support needs in patients with head and neck cancer: A multi-institutional survey. Cancer 2017;123:1949–1957. Available at: https://www.ncbi.nlm.nih.gov/pubmed/28081302.

59. So WK, Chan RJ, Chan DN, et al. Quality-of-life among head and neck cancer survivors at one year after treatment--a systematic review. Eur J Cancer 2012;48:2391–2408. Available at: http://www.ncbi.nlm.nih.gov/pubmed/22579456.

60. Smith BG, Hutcheson KA, Little LG, et al. Lymphedema outcomes in patients with head and neck cancer. Otolaryngol Head Neck Surg 2015;152:284–291. Available at: https://www.ncbi.nlm.nih.gov/pubmed/25389318.

61. Colasanto JM, Prasad P, Nash MA, et al. Nutritional support of patients undergoing radiation therapy for head and neck cancer. Oncology (Williston Park) 2005;19:371–379. Available at: http://www.ncbi.nlm.nih.gov/pubmed/15828552.

Discussion update in progress

Version 1.2026 © 2025 National Comprehensive Cancer Network© (NCCN©), All rights reserved. NCCN Guidelines® and this illustration may not be reproduced in any form without the express written permission of NCCN.

PLEASE NOTE that use of this NCCN Content is governed by the End-User License Agreement, and you MAY NOT distribute this Content or use it with any artificial intelligence model or tool.
Printed by Galya Basol Kochav on 1/4/2026 9:40:35 AM. Copyright © 2026 National Comprehensive Cancer Network, Inc. All Rights Reserved.

62. Lin BM, Starmer HM, Gourin CG. The relationship between depressive symptoms, quality of life, and swallowing function in head and neck cancer patients 1 year after definitive therapy. Laryngoscope 2012;122:1518–1525. Available at: http://www.ncbi.nlm.nih.gov/pubmed/22467530.

63. Krebber AM, Leemans CR, de Bree R, et al. Stepped care targeting psychological distress in head and neck and lung cancer patients: a randomized clinical trial. BMC Cancer 2012;12:173. Available at: http://www.ncbi.nlm.nih.gov/pubmed/22574757.

64. Verdonck-de Leeuw IM, de Bree R, Keizer AL, et al. Computerized prospective screening for high levels of emotional distress in head and neck cancer patients and referral rate to psychosocial care. Oral Oncol 2009;45:e129–133. Available at: http://www.ncbi.nlm.nih.gov/pubmed/19362038.

65. Andersen BL, DeRubeis RJ, Berman BS, et al. Screening, assessment, and care of anxiety and depressive symptoms in adults with cancer: an American Society of Clinical Oncology guideline adaptation. J Clin Oncol 2014;32:1605–1619. Available at: http://www.ncbi.nlm.nih.gov/pubmed/24733793.

66. Cancer and tobacco use. CDC Vital Signs. Altanta: Centers for Disease Control and Prevention; 2016. Available at: https://www.cdc.gov/vitalsigns/pdf/2016-11-vitalsigns.pdf.

67. The Health Consequences of Smoking—50 Years of Progress: A Report of the Surgeon General. Atlanta, GA: U.S. Department of Health and Human Services 2014. Available at: http://www.surgeongeneral.gov/library/reports/50-years-of-progress/.

68. Marin VP, Pytynia KB, Langstein HN, et al. Serum cotinine concentration and wound complications in head and neck reconstruction. Plast Reconstr Surg 2008;121:451–457. Available at: http://www.ncbi.nlm.nih.gov/pubmed/18300961.

69. Egestad H, Emaus N. Changes in health related quality of life in women and men undergoing radiation treatment for head and neck cancer and the impact of smoking status in the radiation treatment period. Eur J Oncol Nurs 2014;18:339–346. Available at: http://www.ncbi.nlm.nih.gov/pubmed/24877857.

70. Rettig EM, D'Souza G. Epidemiology of head and neck cancer. Surg Oncol Clin N Am 2015;24:379–396. Available at: https://www.ncbi.nlm.nih.gov/pubmed/25979389.

71. Smith EM, Rubenstein LM, Haugen TH, et al. Tobacco and alcohol use increases the risk of both HPV-associated and HPV-independent head and neck cancers. Cancer Causes Control 2010;21:1369–1378. Available at: https://www.ncbi.nlm.nih.gov/pubmed/20401530.

72. Hwang JP, Feld JJ, Hammond SP, et al. Hepatitis B virus screening and management for patients with cancer prior to therapy: ASCO provisional clinical opinion update. J Clin Oncol 2020;38:3698–3715. Available at: https://www.ncbi.nlm.nih.gov/pubmed/32716741.

73. Piccirillo JF, Lacy PD, Basu A, Spitznagel EL. Development of a new head and neck cancer-specific comorbidity index. Arch Otolaryngol Head Neck Surg 2002;128:1172–1179. Available at: http://www.ncbi.nlm.nih.gov/pubmed/12365889.

74. Chen AY, Matson LK, Roberts D, Goepfert H. The significance of comorbidity in advanced laryngeal cancer. Head Neck 2001;23:566–572. Available at: http://www.ncbi.nlm.nih.gov/pubmed/11400245.

75. de Graeff A, de Leeuw JR, Ros WJ, et al. Pretreatment factors predicting quality of life after treatment for head and neck cancer. Head Neck 2000;22:398–407. Available at: http://www.ncbi.nlm.nih.gov/pubmed/10862025.

76. Funk GF, Karnell LH, Whitehead S, et al. Free tissue transfer versus pedicled flap cost in head and neck cancer. Otolaryngol Head Neck Surg 2002;127:205–212. Available at: http://www.ncbi.nlm.nih.gov/pubmed/12297811.

77. Farwell DG, Reilly DF, Weymuller EA, et al. Predictors of perioperative complications in head and neck patients. Arch Otolaryngol Head Neck

Discussion update in progress

Version 1.2026 © 2025 National Comprehensive Cancer Network© (NCCN©), All rights reserved. NCCN Guidelines® and this illustration may not be reproduced in any form without the express written permission of NCCN.

PLEASE NOTE that use of this NCCN Content is governed by the End-User License Agreement, and you MAY NOT distribute this Content or use it with any artificial intelligence model or tool.
Printed by Galya Basol Kochav on 1/4/2026 9:40:35 AM. Copyright © 2026 National Comprehensive Cancer Network, Inc. All Rights Reserved.

Surg 2002;128:505–511. Available at: http://www.ncbi.nlm.nih.gov/pubmed/12003580.

78. Piccirillo JF, Tierney RM, Costas I, et al. Prognostic importance of comorbidity in a hospital-based cancer registry. JAMA 2004;291:2441–2447. Available at: https://www.ncbi.nlm.nih.gov/pubmed/15161894.

79. Yueh B. Measuring and Reporting Quality of Life in Head and Neck Cancer. McLean, Virginia; 2002.

80. Rogers SN, Gwanne S, Lowe D, et al. The addition of mood and anxiety domains to the University of Washington quality of life scale. Head Neck 2002;24:521–529. Available at: http://www.ncbi.nlm.nih.gov/pubmed/12112548.

81. Bjordal K, Hammerlid E, Ahlner-Elmqvist M, et al. Quality of life in head and neck cancer patients: validation of the European Organization for Research and Treatment of Cancer Quality of Life Questionnaire-H&N35. J Clin Oncol 1999;17:1008–1019. Available at: http://www.ncbi.nlm.nih.gov/pubmed/10071296.

82. Cella D. Manual for the Functional Assessment of Cancer Therapy (FACT) Measurement System (version 4). Chicago: Rush Medical Center; 1997.

83. List MA, D'Antonio LL, Cella DF, et al. The Performance Status Scale for Head and Neck Cancer Patients and the Functional Assessment of Cancer Therapy-Head and Neck Scale. A study of utility and validity. Cancer 1996;77:2294–2301. Available at: http://www.ncbi.nlm.nih.gov/pubmed/8635098.

84. Epstein JB, Beaumont JL, Gwede CK, et al. Longitudinal evaluation of the oral mucositis weekly questionnaire-head and neck cancer, a patient-reported outcomes questionnaire. Cancer 2007;109:1914–1922. Available at: https://www.ncbi.nlm.nih.gov/pubmed/17377917.

85. Kim SJ, Pak K, Kim K. Diagnostic accuracy of F-18 FDG PET or PET/CT for detection of lymph node metastasis in clinically node negative head and neck cancer patients; A systematic review and meta-analysis. Am J Otolaryngol 2019;40:297–305. Available at: https://www.ncbi.nlm.nih.gov/pubmed/30473166.

86. Lowe VJ, Duan F, Subramaniam RM, et al. Multicenter trial of [(18)F]fluorodeoxyglucose positron emission tomography/computed tomography staging of head and neck cancer and negative predictive value and surgical impact in the N0 neck: results from ACRIN 6685. J Clin Oncol 2019;37:1704–1712. Available at: https://www.ncbi.nlm.nih.gov/pubmed/30768363.

87. Linz C, Brands RC, Herterich T, et al. Accuracy of 18-F fluorodeoxyglucose positron emission tomographic/computed tomographic imaging in primary staging of squamous cell carcinoma of the oral cavity. JAMA Netw Open 2021;4:e217083. Available at: https://www.ncbi.nlm.nih.gov/pubmed/33881529.

88. Hosni A, Huang SH, Chiu K, et al. Predictors of early recurrence prior to planned postoperative radiation therapy for oral cavity squamous cell carcinoma and outcomes following salvage intensified radiation therapy. Int J Radiat Oncol Biol Phys 2019;103:363–373. Available at: https://www.ncbi.nlm.nih.gov/pubmed/30244160.

89. Isles MG, McConkey C, Mehanna HM. A systematic review and meta-analysis of the role of positron emission tomography in the follow up of head and neck squamous cell carcinoma following radiotherapy or chemoradiotherapy. Clin Otolaryngol 2008;33:210–222. Available at: http://www.ncbi.nlm.nih.gov/pubmed/18559026.

90. Heineman TE, Kuan EC, St John MA. When should surveillance imaging be performed after treatment for head and neck cancer? Laryngoscope 2017;127:533–534. Available at: https://www.ncbi.nlm.nih.gov/pubmed/28185273.

91. Cheung PK, Chin RY, Eslick GD. Detecting residual/recurrent head neck squamous cell carcinomas using PET or PET/CT: systematic review and meta-analysis. Otolaryngol Head Neck Surg 2016;154:421–432. Available at: https://www.ncbi.nlm.nih.gov/pubmed/26715675.

Discussion update in progress

Version 1.2026 © 2025 National Comprehensive Cancer Network© (NCCN©), All rights reserved. NCCN Guidelines® and this illustration may not be reproduced in any form without the express written permission of NCCN.

PLEASE NOTE that use of this NCCN Content is governed by the End-User License Agreement, and you MAY NOT distribute this Content or use it with any artificial intelligence model or tool.
Printed by Galya Basol Kochav on 1/4/2026 9:40:35 AM. Copyright © 2026 National Comprehensive Cancer Network, Inc. All Rights Reserved.

92. Liauw SL, Mancuso AA, Amdur RJ, et al. Postradiotherapy neck dissection for lymph node-positive head and neck cancer: the use of computed tomography to manage the neck. J Clin Oncol 2006;24:1421–1427. Available at: http://www.ncbi.nlm.nih.gov/pubmed/16549836.

93. Porceddu SV, Jarmolowski E, Hicks RJ, et al. Utility of positron emission tomography for the detection of disease in residual neck nodes after (chemo)radiotherapy in head and neck cancer. Head Neck 2005;27:175–181. Available at: http://www.ncbi.nlm.nih.gov/pubmed/15627258.

94. Yao M, Smith RB, Hoffman HT, et al. Clinical significance of postradiotherapy [18F]-fluorodeoxyglucose positron emission tomography imaging in management of head-and-neck cancer-a long-term outcome report. Int J Radiat Oncol Biol Phys 2009;74:9–14. Available at: http://www.ncbi.nlm.nih.gov/pubmed/18930358.

95. Lango MN, Myers JN, Garden AS. Controversies in surgical management of the node-positive neck after chemoradiation. Semin Radiat Oncol 2009;19:24–28. Available at: http://www.ncbi.nlm.nih.gov/pubmed/19028342.

96. Kutler DI, Patel SG, Shah JP. The role of neck dissection following definitive chemoradiation. Oncology (Williston Park) 2004;18:993–998; discussion 999, 1003–1004, 1007. Available at: http://www.ncbi.nlm.nih.gov/pubmed/15328894.

97. Mehanna H, Wong WL, McConkey CC, et al. PET-CT surveillance versus neck dissection in advanced head and neck cancer. N Engl J Med 2016;374:1444–1454. Available at: https://www.ncbi.nlm.nih.gov/pubmed/27007578.

98. Mehanna H, McConkey CC, Rahman JK, et al. PET-NECK: a multicentre randomised phase III non-inferiority trial comparing a positron emission tomography-computerised tomography-guided watch-and-wait policy with planned neck dissection in the management of locally advanced (N2/N3) nodal metastases in patients with squamous cell head and neck cancer. Health Technol Assess 2017;21:1–122. Available at: https://www.ncbi.nlm.nih.gov/pubmed/28409743/.

99. Worthington HV, Bulsara VM, Glenny AM, et al. Interventions for the treatment of oral cavity and oropharyngeal cancers: surgical treatment. Cochrane Database Syst Rev 2023;8:CD006205. Available at: https://www.ncbi.nlm.nih.gov/pubmed/37650478.

100. Corry J, Peters L, Fisher R, et al. N2-N3 neck nodal control without planned neck dissection for clinical/radiologic complete responders-results of Trans Tasman Radiation Oncology Group Study 98.02. Head Neck 2008;30:737–742. Available at: http://www.ncbi.nlm.nih.gov/pubmed/18286488.

101. Lau H, Phan T, Mackinnon J, Matthews TW. Absence of planned neck dissection for the N2-N3 neck after chemoradiation for locally advanced squamous cell carcinoma of the head and neck. Arch Otolaryngol Head Neck Surg 2008;134:257–261. Available at: http://www.ncbi.nlm.nih.gov/pubmed/18347249.

102. Ong SC, Schoder H, Lee NY, et al. Clinical utility of 18F-FDG PET/CT in assessing the neck after concurrent chemoradiotherapy for Locoregional advanced head and neck cancer. J Nucl Med 2008;49:532–540. Available at: http://www.ncbi.nlm.nih.gov/pubmed/18344440.

103. Nayak JV, Walvekar RR, Andrade RS, et al. Deferring planned neck dissection following chemoradiation for stage IV head and neck cancer: the utility of PET-CT. Laryngoscope 2007;117:2129–2134. Available at: http://www.ncbi.nlm.nih.gov/pubmed/17921898.

104. Abgral R, Querellou S, Potard G, et al. Does 18F-FDG PET/CT improve the detection of posttreatment recurrence of head and neck squamous cell carcinoma in patients negative for disease on clinical follow-up? J Nucl Med 2009;50:24–29. Available at: http://www.ncbi.nlm.nih.gov/pubmed/19091901.

105. Porceddu SV, Pryor DI, Burmeister E, et al. Results of a prospective study of positron emission tomography-directed management of residual nodal abnormalities in node-positive head and neck cancer after definitive radiotherapy with or without systemic therapy. Head Neck 2011;33:1675–1682. Available at: http://www.ncbi.nlm.nih.gov/pubmed/22076976.

Discussion update in progress

Version 1.2026 © 2025 National Comprehensive Cancer Network© (NCCN©), All rights reserved. NCCN Guidelines® and this illustration may not be reproduced in any form without the express written permission of NCCN.

PLEASE NOTE that use of this NCCN Content is governed by the End-User License Agreement, and you MAY NOT distribute this Content or use it with any artificial intelligence model or tool.
Printed by Galya Basol Kochav on 1/4/2026 9:40:35 AM. Copyright © 2026 National Comprehensive Cancer Network, Inc. All Rights Reserved.

106. Ho AS, Tsao GJ, Chen FW, et al. Impact of positron emission tomography/computed tomography surveillance at 12 and 24 months for detecting head and neck cancer recurrence. Cancer 2013;119:1349–1356. Available at: https://www.ncbi.nlm.nih.gov/pubmed/23225544.

107. Trosman SJ, Koyfman SA, Ward MC, et al. Effect of human papillomavirus on patterns of distant metastatic failure in oropharyngeal squamous cell carcinoma treated with chemoradiotherapy. JAMA Otolaryngol Head Neck Surg 2015;141:457–462. Available at: https://www.ncbi.nlm.nih.gov/pubmed/25742025.

108. Sheikhbahaei S, Taghipour M, Ahmad R, et al. Diagnostic accuracy of follow-up FDG PET or PET/CT in patients with head and neck cancer after definitive treatment: a systematic review and meta-analysis. AJR Am J Roentgenol 2015;205:629–639. Available at: https://www.ncbi.nlm.nih.gov/pubmed/26295652.

109. National Lung Screening Trial Research T, Aberle DR, Adams AM, et al. Reduced lung-cancer mortality with low-dose computed tomographic screening. N Engl J Med 2011;365:395–409. Available at: https://www.ncbi.nlm.nih.gov/pubmed/21714641.

110. Humphrey LL, Deffebach M, Pappas M, et al. Screening for lung cancer with low-dose computed tomography: a systematic review to update the US Preventive Services Task Force recommendation. Ann Intern Med 2013;159:411–420. Available at: https://www.ncbi.nlm.nih.gov/pubmed/23897166.

111. Texakalidis P, Giannopoulos S, Tsouknidas I, et al. Prevalence of carotid stenosis following radiotherapy for head and neck cancer: a systematic review and meta-analysis. Head Neck 2020;42:1077–1088. Available at: https://www.ncbi.nlm.nih.gov/pubmed/32048781.

112. Carpenter DJ, Mowery YM, Broadwater G, et al. The risk of carotid stenosis in head and neck cancer patients after radiation therapy. Oral Oncol 2018;80:9–15. Available at: https://www.ncbi.nlm.nih.gov/pubmed/29706194.

113. van Aken ESM, van der Laan HP, Bijl HP, et al. Risk of ischaemic cerebrovascular events in head and neck cancer patients is associated with carotid artery radiation dose. Radiother Oncol 2021;157:182–187. Available at: https://www.ncbi.nlm.nih.gov/pubmed/33545259.

114. Carpenter DJ, Patel P, Niedzwiecki D, et al. Long-term risk of carotid stenosis and cerebrovascular disease after radiation therapy for head and neck cancer. Cancer 2025;131:e35089. Available at: https://www.ncbi.nlm.nih.gov/pubmed/37897711.

115. AbuRahma AF, Avgerinos ED, Chang RW, et al. Society for Vascular Surgery clinical practice guidelines for management of extracranial cerebrovascular disease. J Vasc Surg 2022;75:4S–22S. Available at: https://www.ncbi.nlm.nih.gov/pubmed/34153348.

116. Adelstein DJ, Ridge JA, Brizel DM, et al. Transoral resection of pharyngeal cancer: summary of a National Cancer Institute Head and Neck Cancer Steering Committee Clinical Trials Planning Meeting, November 6-7, 2011, Arlington, Virginia. Head Neck 2012;34:1681–1703. Available at: http://www.ncbi.nlm.nih.gov/pubmed/23015475.

117. Arens C. Transoral treatment strategies for head and neck tumors. GMS Curr Top Otorhinolaryngol Head Neck Surg 2012;11:Doc05. Available at: http://www.ncbi.nlm.nih.gov/pubmed/23320057.

118. Weinstein GS, O'Malley BW, Jr., Magnuson JS, et al. Transoral robotic surgery: a multicenter study to assess feasibility, safety, and surgical margins. Laryngoscope 2012;122:1701–1707. Available at: http://www.ncbi.nlm.nih.gov/pubmed/22752997.

119. Li RJ, Richmon JD. Transoral endoscopic surgery: new surgical techniques for oropharyngeal cancer. Otolaryngol Clin North Am 2012;45:823–844. Available at: http://www.ncbi.nlm.nih.gov/pubmed/22793855.

120. Liu H, Wang Y, Wu C, et al. Robotic compared with open operations for cancers of the head and neck: a systematic review and meta-analysis. Br J Oral Maxillofac Surg 2019;57:967–976. Available at: https://www.ncbi.nlm.nih.gov/pubmed/31522917.

Discussion update in progress

Version 1.2026 © 2025 National Comprehensive Cancer Network© (NCCN©), All rights reserved. NCCN Guidelines® and this illustration may not be reproduced in any form without the express written permission of NCCN.

PLEASE NOTE that use of this NCCN Content is governed by the End-User License Agreement, and you MAY NOT distribute this Content or use it with any artificial intelligence model or tool.
Printed by Galya Basol Kochav on 1/4/2026 9:40:35 AM. Copyright © 2026 National Comprehensive Cancer Network, Inc. All Rights Reserved.

121. Kubik M, Mandal R, Albergotti W, et al. Effect of transcervical arterial ligation on the severity of postoperative hemorrhage after transoral robotic surgery. Head Neck 2017;39:1510–1515. Available at: https://www.ncbi.nlm.nih.gov/pubmed/28570011.

122. Hay A, Migliacci J, Karassawa Zanoni D, et al. Haemorrhage following transoral robotic surgery. Clin Otolaryngol 2018;43:638–644. Available at: https://www.ncbi.nlm.nih.gov/pubmed/29194991.

123. Castellano A, Sharma A. Systematic review of validated quality of life and swallow outcomes after transoral robotic surgery. Otolaryngol Head Neck Surg 2019;161:561–567. Available at: https://www.ncbi.nlm.nih.gov/pubmed/31013186.

124. De Virgilio A, Costantino A, Mercante G, et al. Transoral robotic surgery and intensity-modulated radiotherapy in the treatment of the oropharyngeal carcinoma: a systematic review and meta-analysis. Eur Arch Otorhinolaryngol 2021;278:1321–1335. Available at: https://www.ncbi.nlm.nih.gov/pubmed/32696250.

125. Harrison L, Sessions R, Hong W. Head and Neck Cancer: A Multidisciplinary Approach, 3rd edition. Philadelphia, PA: Lippincott Williams & Wilkins; 2009.

126. DeVita Jr. V, Lawrence T, Rosenberg S, eds. Cancer: Principles & Practice of Oncology, 8th edition. Philadelphia: Lippincott Williams & Wilkins; 2008.

127. Robbins KT, Shaha AR, Medina JE, et al. Consensus statement on the classification and terminology of neck dissection. Arch Otolaryngol Head Neck Surg 2008;134:536–538. Available at: http://www.ncbi.nlm.nih.gov/pubmed/18490577.

128. Byers RM. Neck dissection: concepts, controversies, and technique. Semin Surg Oncol 1991;7:9–13. Available at: http://www.ncbi.nlm.nih.gov/pubmed/2003186.

129. Stringer SP. Current concepts in surgical management of neck metastases from head and neck cancer. Oncology (Williston Park) 1995;9:547–554. Available at: http://www.ncbi.nlm.nih.gov/pubmed/8719100.

130. Robbins KT, Clayman G, Levine PA, et al. Neck dissection classification update: revisions proposed by the American Head and Neck Society and the American Academy of Otolaryngology-Head and Neck Surgery. Arch Otolaryngol Head Neck Surg 2002;128:751–758. Available at: http://www.ncbi.nlm.nih.gov/pubmed/12117328.

131. Candela FC, Kothari K, Shah JP. Patterns of cervical node metastases from squamous carcinoma of the oropharynx and hypopharynx. Head Neck 1990;12:197–203. Available at: http://www.ncbi.nlm.nih.gov/pubmed/2358329.

132. Candela FC, Shah J, Jaques DP, Shah JP. Patterns of cervical node metastases from squamous carcinoma of the larynx. Arch Otolaryngol Head Neck Surg 1990;116:432–435. Available at: http://www.ncbi.nlm.nih.gov/pubmed/2317325.

133. Shah JP, Candela FC, Poddar AK. The patterns of cervical lymph node metastases from squamous carcinoma of the oral cavity. Cancer 1990;66:109–113. Available at: http://www.ncbi.nlm.nih.gov/pubmed/2354399.

134. Ferlito A, Rinaldo A, Silver CE, et al. Elective and therapeutic selective neck dissection. Oral Oncol 2006;42:14–25. Available at: http://www.ncbi.nlm.nih.gov/pubmed/15979381.

135. Schmitz S, Machiels JP, Weynand B, et al. Results of selective neck dissection in the primary management of head and neck squamous cell carcinoma. Eur Arch Otorhinolaryngol 2009;266:437–443. Available at: http://www.ncbi.nlm.nih.gov/pubmed/18648835.

136. Patel RS, Clark J, Wyten R, et al. Squamous cell carcinoma from an unknown head and neck primary site: a "selective treatment" approach. Arch Otolaryngol Head Neck Surg 2007;133:1282–1287. Available at: http://www.ncbi.nlm.nih.gov/pubmed/18086973.

Discussion update in progress

Version 1.2026 © 2025 National Comprehensive Cancer Network© (NCCN©), All rights reserved. NCCN Guidelines® and this illustration may not be reproduced in any form without the express written permission of NCCN.

PLEASE NOTE that use of this NCCN Content is governed by the End-User License Agreement, and you MAY NOT distribute this Content or use it with any artificial intelligence model or tool.
Printed by Galya Basol Kochav on 1/4/2026 9:40:35 AM. Copyright © 2026 National Comprehensive Cancer Network, Inc. All Rights Reserved.

137. Sivanandan R, Kaplan MJ, Lee KJ, et al. Long-term results of 100 consecutive comprehensive neck dissections: implications for selective neck dissections. Arch Otolaryngol Head Neck Surg 2004;130:1369–1373. Available at: http://www.ncbi.nlm.nih.gov/pubmed/15611394.

138. Bernier J, Domenge C, Ozsahin M, et al. Postoperative irradiation with or without concomitant chemotherapy for locally advanced head and neck cancer. N Engl J Med 2004;350:1945–1952. Available at: http://www.ncbi.nlm.nih.gov/pubmed/15128894.

139. Cooper JS, Pajak TF, Forastiere AA, et al. Postoperative concurrent radiotherapy and chemotherapy for high-risk squamous-cell carcinoma of the head and neck. N Engl J Med 2004;350:1937–1944. Available at: http://www.ncbi.nlm.nih.gov/pubmed/15128893.

140. Bernier J, Cooper JS, Pajak TF, et al. Defining risk levels in locally advanced head and neck cancers: a comparative analysis of concurrent postoperative radiation plus chemotherapy trials of the EORTC (#22931) and RTOG (# 9501). Head Neck 2005;27:843–850. Available at: http://www.ncbi.nlm.nih.gov/pubmed/16161069.

141. Cooper JS, Zhang Q, Pajak TF, et al. Long-term follow-up of the RTOG 9501/intergroup phase III trial: postoperative concurrent radiation therapy and chemotherapy in high-risk squamous cell carcinoma of the head and neck. Int J Radiat Oncol Biol Phys 2012;84:1198–1205. Available at: http://www.ncbi.nlm.nih.gov/pubmed/22749632.

142. Noronha V, Joshi A, Patil VM, et al. Once-a-week versus once-every-3-weeks cisplatin chemoradiation for locally advanced head and neck cancer: a phase III randomized noninferiority trial. J Clin Oncol 2018;36:1064–1072. Available at: https://www.ncbi.nlm.nih.gov/pubmed/29220295.

143. Bachaud JM, Cohen-Jonathan E, Alzieu C, et al. Combined postoperative radiotherapy and weekly cisplatin infusion for locally advanced head and neck carcinoma: final report of a randomized trial. Int J Radiat Oncol Biol Phys 1996;36:999–1004. Available at: http://www.ncbi.nlm.nih.gov/pubmed/8985019.

144. Patil VM, Noronha V, Menon N, et al. Results of Phase III Randomized Trial for Use of Docetaxel as a Radiosensitizer in Patients With Head and Neck Cancer, Unsuitable for Cisplatin-Based Chemoradiation. J Clin Oncol 2023;41:2350–2361. Available at: https://www.ncbi.nlm.nih.gov/pubmed/36706347.

145. Harari PM, Harris J, Kies MS, et al. Postoperative chemoradiotherapy and cetuximab for high-risk squamous cell carcinoma of the head and neck: Radiation Therapy Oncology Group RTOG-0234. J Clin Oncol 2014;32:2486–2495. Available at: https://www.ncbi.nlm.nih.gov/pubmed/25002723.

146. Hasan Z, Dwivedi RC, Gunaratne DA, et al. Systematic review and meta-analysis of the complications of salvage total laryngectomy. Eur J Surg Oncol 2017;43:42–51. Available at: https://www.ncbi.nlm.nih.gov/pubmed/27265037.

147. Cho YS, Lee E, Jin H, et al. Palliative tumor surgery for incurable head and neck cancer: indications and outcomes: A retrospective case review. Precision and Future Medicine 2022;6:146–153. Available at: https://doi.org/10.23838/pfm.2022.00037

http://www.pfmjournal.org/journal/view.php?number=123.

148. Gregoire V, Evans M, Le QT, et al. Delineation of the primary tumour clinical target volumes (CTV-P) in laryngeal, hypopharyngeal, oropharyngeal and oral cavity squamous cell carcinoma: AIRO, CACA, DAHANCA, EORTC, GEORCC, GORTEC, HKNPCSG, HNCIG, IAG-KHT, LPRHHT, NCIC CTG, NCRI, NRG Oncology, PHNS, SBRT, SOMERA, SRO, SSHNO, TROG consensus guidelines. Radiother Oncol 2018;126:3–24. Available at: https://www.ncbi.nlm.nih.gov/pubmed/29180076.

149. Lee AW, Ng WT, Pan JJ, et al. International guideline for the delineation of the clinical target volumes (CTV) for nasopharyngeal carcinoma. Radiother Oncol 2018;126:25–36. Available at: https://www.ncbi.nlm.nih.gov/pubmed/29153464.

Discussion update in progress

Version 1.2026 © 2025 National Comprehensive Cancer Network© (NCCN©), All rights reserved. NCCN Guidelines® and this illustration may not be reproduced in any form without the express written permission of NCCN.

PLEASE NOTE that use of this NCCN Content is governed by the End-User License Agreement, and you MAY NOT distribute this Content or use it with any artificial intelligence model or tool.
Printed by Galya Basol Kochav on 1/4/2026 9:40:35 AM. Copyright © 2026 National Comprehensive Cancer Network, Inc. All Rights Reserved.

150. Stevens CM, Huang SH, Fung S, et al. Retrospective study of palliative radiotherapy in newly diagnosed head and neck carcinoma. Int J Radiat Oncol Biol Phys 2011;81:958–963. Available at: http://www.ncbi.nlm.nih.gov/pubmed/20950952.

151. Porceddu SV, Rosser B, Burmeister BH, et al. Hypofractionated radiotherapy for the palliation of advanced head and neck cancer in patients unsuitable for curative treatment--"Hypo Trial". Radiother Oncol 2007;85:456–462. Available at: http://www.ncbi.nlm.nih.gov/pubmed/18036689.

152. Corry J, Peters LJ, Costa ID, et al. The 'QUAD SHOT'--a phase II study of palliative radiotherapy for incurable head and neck cancer. Radiother Oncol 2005;77:137–142. Available at: http://www.ncbi.nlm.nih.gov/pubmed/16260054.

153. Fu KK, Pajak TF, Trotti A, et al. A Radiation Therapy Oncology Group (RTOG) phase III randomized study to compare hyperfractionation and two variants of accelerated fractionation to standard fractionation radiotherapy for head and neck squamous cell carcinomas: first report of RTOG 9003. Int J Radiat Oncol Biol Phys 2000;48:7–16. Available at: http://www.ncbi.nlm.nih.gov/pubmed/10924966.

154. Beitler JJ, Zhang Q, Fu KK, et al. Final results of local-regional control and late toxicity of RTOG 9003: a randomized trial of altered fractionation radiation for locally advanced head and neck cancer. Int J Radiat Oncol Biol Phys 2014;89:13–20. Available at: http://www.ncbi.nlm.nih.gov/pubmed/24613816.

155. Overgaard J, Hansen HS, Specht L, et al. Five compared with six fractions per week of conventional radiotherapy of squamous-cell carcinoma of head and neck: DAHANCA 6 and 7 randomised controlled trial. Lancet 2003;362:933–940. Available at: http://www.ncbi.nlm.nih.gov/pubmed/14511925.

156. Sher DJ, Adelstein DJ, Bajaj GK, et al. Radiation therapy for oropharyngeal squamous cell carcinoma: Executive summary of an ASTRO Evidence-Based Clinical Practice Guideline. Pract Radiat Oncol 2017;7:246–253. Available at: https://www.ncbi.nlm.nih.gov/pubmed/28428019.

157. Barkley HT, Fletcher GH. The significance of residual disease after external irradiation of squamous-cell carcinoma of the oropharynx. Radiology 1977;124:493–495. Available at: http://www.ncbi.nlm.nih.gov/pubmed/877290.

158. ICRU Report 62. Prescribing, Recording and Reporting Photon Beam Therapy (Supplement to ICRU Report 50). Journal of the ICRU. Bethesda, MD: International Commission on Radiation Units and Measurements; 1999. Available at: https://academic.oup.com/jicru/article-abstract/os32/1/NP/2924047.

159. ICRU Report 83: Prescribing, Recording, and Reporting Intensity Modulated Photon Beam Therapy (IMRT). Journal of the ICRU 2010;10. Available at: https://pubmed.ncbi.nlm.nih.gov/22234506/.

160. Garden AS, Dong L, Morrison WH, et al. Patterns of disease recurrence following treatment of oropharyngeal cancer with intensity modulated radiation therapy. Int J Radiat Oncol Biol Phys 2013;85:941–947. Available at: http://www.ncbi.nlm.nih.gov/pubmed/22975604.

161. Daly ME, Le QT, Maxim PG, et al. Intensity-modulated radiotherapy in the treatment of oropharyngeal cancer: clinical outcomes and patterns of failure. Int J Radiat Oncol Biol Phys 2010;76:1339–1346. Available at: http://www.ncbi.nlm.nih.gov/pubmed/19540068.

162. Eisbruch A, Harris J, Garden AS, et al. Multi-institutional trial of accelerated hypofractionated intensity-modulated radiation therapy for early-stage oropharyngeal cancer (RTOG 00-22). Int J Radiat Oncol Biol Phys 2010;76:1333–1338. Available at: https://www.ncbi.nlm.nih.gov/pubmed/19540060.

163. Laursen M, Specht L, Kristensen CA, et al. An extended hypofractionated palliative radiotherapy regimen for head and neck carcinomas. Front Oncol 2018;8:206. Available at: https://www.ncbi.nlm.nih.gov/pubmed/29942791.

Discussion update in progress

Version 1.2026 © 2025 National Comprehensive Cancer Network© (NCCN©), All rights reserved. NCCN Guidelines® and this illustration may not be reproduced in any form without the express written permission of NCCN.

PLEASE NOTE that use of this NCCN Content is governed by the End-User License Agreement, and you MAY NOT distribute this Content or use it with any artificial intelligence model or tool.
Printed by Galya Basol Kochav on 1/4/2026 9:40:35 AM. Copyright © 2026 National Comprehensive Cancer Network, Inc. All Rights Reserved.

164. Thames HD, Jr., Withers HR, Peters LJ, Fletcher GH. Changes in early and late radiation responses with altered dose fractionation: implications for dose-survival relationships. Int J Radiat Oncol Biol Phys 1982;8:219–226. Available at: http://www.ncbi.nlm.nih.gov/pubmed/7085377.

165. Withers HR, Taylor JM, Maciejewski B. The hazard of accelerated tumor clonogen repopulation during radiotherapy. Acta Oncol 1988;27:131–146. Available at: http://www.ncbi.nlm.nih.gov/pubmed/3390344.

166. Schwaibold F, Scariato A, Nunno M, et al. The effect of fraction size on control of early glottic cancer. Int J Radiat Oncol Biol Phys 1988;14:451–454. Available at: http://www.ncbi.nlm.nih.gov/pubmed/3343152.

167. Kim RY, Marks ME, Salter MM. Early-stage glottic cancer: importance of dose fractionation in radiation therapy. Radiology 1992;182:273–275. Available at: http://www.ncbi.nlm.nih.gov/pubmed/1727295.

168. Parson J. Time-dose-volume relationships in radiation therapy. In: Million R, Cassisi N, eds. Management of Head and Neck Cancer: A Multidisciplinary Approach, 2nd ed. Philadelphia: Lippincott Williams & Wilkins; 1994:203–243.

169. Yamazaki H, Nishiyama K, Tanaka E, et al. Radiotherapy for early glottic carcinoma (T1N0M0): results of prospective randomized study of radiation fraction size and overall treatment time. Int J Radiat Oncol Biol Phys 2006;64:77–82. Available at: http://www.ncbi.nlm.nih.gov/pubmed/16169681.

170. Yu E, Shenouda G, Beaudet MP, Black MJ. Impact of radiation therapy fraction size on local control of early glottic carcinoma. Int J Radiat Oncol Biol Phys 1997;37:587–591. Available at: http://www.ncbi.nlm.nih.gov/pubmed/9112457.

171. Horiot JC, Le Fur R, N'Guyen T, et al. Hyperfractionation versus conventional fractionation in oropharyngeal carcinoma: final analysis of a randomized trial of the EORTC cooperative group of radiotherapy. Radiother Oncol 1992;25:231–241. Available at: http://www.ncbi.nlm.nih.gov/pubmed/1480768.

172. Horiot JC. [Controlled clinical trials of hyperfractionated and accelerated radiotherapy in otorhinolaryngologic cancers]. Bull Acad Natl Med 1998;182:1247–1260; discussion 1261. Available at: http://www.ncbi.nlm.nih.gov/pubmed/9812410.

173. Horiot JC, Bontemps P, van den Bogaert W, et al. Accelerated fractionation (AF) compared to conventional fractionation (CF) improves loco-regional control in the radiotherapy of advanced head and neck cancers: results of the EORTC 22851 randomized trial. Radiother Oncol 1997;44:111–121. Available at: http://www.ncbi.nlm.nih.gov/pubmed/9288839.

174. Konski AA, Winter K, Cole BF, et al. Quality-adjusted survival analysis of Radiation Therapy Oncology Group (RTOG) 90-03: phase III randomized study comparing altered fractionation to standard fractionation radiotherapy for locally advanced head and neck squamous cell carcinoma. Head Neck 2009;31:207–212. Available at: http://www.ncbi.nlm.nih.gov/pubmed/19107946.

175. Bourhis J, Overgaard J, Audry H, et al. Hyperfractionated or accelerated radiotherapy in head and neck cancer: a meta-analysis. Lancet 2006;368:843–854. Available at: http://www.ncbi.nlm.nih.gov/pubmed/16950362.

176. Baujat B, Bourhis J, Blanchard P, et al. Hyperfractionated or accelerated radiotherapy for head and neck cancer. Cochrane Database Syst Rev 2010;12:CD002026. Available at: http://www.ncbi.nlm.nih.gov/pubmed/21154350.

177. Lacas B, Bourhis J, Overgaard J, et al. Role of radiotherapy fractionation in head and neck cancers (MARCH): an updated meta-analysis. Lancet Oncol 2017;18:1221–1237. Available at: https://www.ncbi.nlm.nih.gov/pubmed/28757375.

Discussion update in progress

Version 1.2026 © 2025 National Comprehensive Cancer Network© (NCCN©), All rights reserved. NCCN Guidelines® and this illustration may not be reproduced in any form without the express written permission of NCCN.

PLEASE NOTE that use of this NCCN Content is governed by the End-User License Agreement, and you MAY NOT distribute this Content or use it with any artificial intelligence model or tool.
Printed by Galya Basol Kochav on 1/4/2026 9:40:35 AM. Copyright © 2026 National Comprehensive Cancer Network, Inc. All Rights Reserved.

178. Budach V, Stuschke M, Budach W, et al. Hyperfractionated accelerated chemoradiation with concurrent fluorouracil-mitomycin is more effective than dose-escalated hyperfractionated accelerated radiation therapy alone in locally advanced head and neck cancer: final results of the radiotherapy cooperative clinical trials group of the German Cancer Society 95-06 Prospective Randomized Trial. J Clin Oncol 2005;23:1125–1135. Available at: http://www.ncbi.nlm.nih.gov/pubmed/15718308.

179. Budach W, Hehr T, Budach V, et al. A meta-analysis of hyperfractionated and accelerated radiotherapy and combined chemotherapy and radiotherapy regimens in unresected locally advanced squamous cell carcinoma of the head and neck. BMC Cancer 2006;6:28. Available at: http://www.ncbi.nlm.nih.gov/pubmed/16448551.

180. Bensadoun R-J, Benezery K, Dassonville O, et al. French multicenter phase III randomized study testing concurrent twice-a-day radiotherapy and cisplatin/5-fluorouracil chemotherapy (BiRCF) in unresectable pharyngeal carcinoma: Results at 2 years (FNCLCC-GORTEC). Int J Radiat Oncol Biol Phys 2006;64:983–994. Available at: http://www.ncbi.nlm.nih.gov/pubmed/16376489.

181. Budach V, Stromberger C, Poettgen C, et al. Hyperfractionated accelerated radiation therapy (HART) of 70.6 Gy with concurrent 5-FU/Mitomycin C is superior to HART of 77.6 Gy alone in locally advanced head and neck cancer: long-term results of the ARO 95-06 randomized phase III trial. Int J Radiat Oncol Biol Phys 2015;91:916–924. Available at: https://www.ncbi.nlm.nih.gov/pubmed/25670541.

182. Bourhis J, Sire C, Graff P, et al. Concomitant chemoradiotherapy versus acceleration of radiotherapy with or without concomitant chemotherapy in locally advanced head and neck carcinoma (GORTEC 99-02): an open-label phase 3 randomised trial. Lancet Oncol 2012;13:145–153. Available at: http://www.ncbi.nlm.nih.gov/pubmed/22261362.

183. Haigentz M, Jr., Corry J, Strojan P, Ferlito A. Easing acceleration of head and neck chemoradiotherapy. Lancet Oncol 2012;13:113–115. Available at: http://www.ncbi.nlm.nih.gov/pubmed/22261361.

184. Ang K, Zhang Q, Wheeler RH, et al. A phase III trial (RTOG 0129) of two radiation-cisplatin regimens for head and neck carcinomas (HNC): Impact of radiation and cisplatin intensity on outcome [abstract]. J Clin Oncol 2010;28(Suppl 15):Abstract 5507. Available at: http://meeting.ascopubs.org/cgi/content/abstract/28/15_suppl/5507.

185. Nguyen-Tan PF, Zhang Q, Ang KK, et al. Randomized phase III trial to test accelerated versus standard fractionation in combination with concurrent cisplatin for head and neck carcinomas in the Radiation Therapy Oncology Group 0129 trial: long-term report of efficacy and toxicity. J Clin Oncol 2014;32:3858–3866. Available at: https://www.ncbi.nlm.nih.gov/pubmed/25366680.

186. Denis F, Garaud P, Bardet E, et al. Final results of the 94-01 French Head and Neck Oncology and Radiotherapy Group randomized trial comparing radiotherapy alone with concomitant radiochemotherapy in advanced-stage oropharynx carcinoma. J Clin Oncol 2004;22:69–76. Available at: http://www.ncbi.nlm.nih.gov/pubmed/14657228.

187. Denis F, Garaud P, Bardet E, et al. Late toxicity results of the GORTEC 94-01 randomized trial comparing radiotherapy with concomitant radiochemotherapy for advanced-stage oropharynx carcinoma: comparison of LENT/SOMA, RTOG/EORTC, and NCI-CTC scoring systems. Int J Radiat Oncol Biol Phys 2003;55:93–98. Available at: http://www.ncbi.nlm.nih.gov/pubmed/12504040.

188. Bourhis J, Calais G, Lapeyre M, et al. Concomitant radiochemotherapy or accelerated radiotherapy: analysis of two randomized trials of the French Head and Neck Cancer Group (GORTEC). Semin Oncol 2004;31:822–826. Available at: http://www.ncbi.nlm.nih.gov/pubmed/15599861.

189. Machtay M, Moughan J, Trotti A, et al. Factors associated with severe late toxicity after concurrent chemoradiation for locally advanced head and neck cancer: an RTOG analysis. J Clin Oncol 2008;26:3582–3589. Available at: http://www.ncbi.nlm.nih.gov/pubmed/18559875.

190. Hartford AC, Palisca MG, Eichler TJ, et al. American Society for Therapeutic Radiology and Oncology (ASTRO) and American College of

Discussion update in progress

Version 1.2026 © 2025 National Comprehensive Cancer Network© (NCCN©), All rights reserved. NCCN Guidelines® and this illustration may not be reproduced in any form without the express written permission of NCCN.

PLEASE NOTE that use of this NCCN Content is governed by the End-User License Agreement, and you MAY NOT distribute this Content or use it with any artificial intelligence model or tool.
Printed by Galya Basol Kochav on 1/4/2026 9:40:35 AM. Copyright © 2026 National Comprehensive Cancer Network, Inc. All Rights Reserved.

Radiology (ACR) Practice Guidelines for Intensity-Modulated Radiation Therapy (IMRT). Int J Radiat Oncol Biol Phys 2009;73:9–14. Available at: http://www.ncbi.nlm.nih.gov/pubmed/19100920.

191. Holmes T, Das R, Low D, et al. American Society of Radiation Oncology recommendations for documenting intensity-modulated radiation therapy treatments. Int J Radiat Oncol Biol Phys 2009;74:1311–1318. Available at: http://www.ncbi.nlm.nih.gov/pubmed/19616738.

192. Nutting CM, Morden JP, Harrington KJ, et al. Parotid-sparing intensity modulated versus conventional radiotherapy in head and neck cancer (PARSPORT): a phase 3 multicentre randomised controlled trial. Lancet Oncol 2011;12:127–136. Available at: http://www.ncbi.nlm.nih.gov/pubmed/21236730.

193. Tribius S, Bergelt C. Intensity-modulated radiotherapy versus conventional and 3D conformal radiotherapy in patients with head and neck cancer: is there a worthwhile quality of life gain? Cancer Treat Rev 2011;37:511–519. Available at: http://www.ncbi.nlm.nih.gov/pubmed/21324605.

194. Ratko TA, Douglas GW, de Souza JA, et al. Radiotherapy Treatments for Head and Neck Cancer Update. Rockville (MD); 2014.

195. Hunter KU, Schipper M, Feng FY, et al. Toxicities affecting quality of life after chemo-IMRT of oropharyngeal cancer: prospective study of patient-reported, observer-rated, and objective outcomes. Int J Radiat Oncol Biol Phys 2013;85:935–940. Available at: http://www.ncbi.nlm.nih.gov/pubmed/23040224.

196. Lohia S, Rajapurkar M, Nguyen SA, et al. A comparison of outcomes using intensity-modulated radiation therapy and 3-dimensional conformal radiation therapy in treatment of oropharyngeal cancer. JAMA Otolaryngol Head Neck Surg 2014;140:331–337. Available at: http://www.ncbi.nlm.nih.gov/pubmed/24557509.

197. Kam MKM, Leung S-F, Zee B, et al. Prospective randomized study of intensity-modulated radiotherapy on salivary gland function in early-stage nasopharyngeal carcinoma patients. J Clin Oncol 2007;25:4873–4879. Available at: http://www.ncbi.nlm.nih.gov/pubmed/17971582.

198. Baxi SS, Sher DJ, Pfister DG. Value considerations in the treatment of head and neck cancer: radiation, chemotherapy, and supportive care. Am Soc Clin Oncol Educ Book 2014:e296–303. Available at: http://www.ncbi.nlm.nih.gov/pubmed/24857116.

199. Schoenfeld JD, Sher DJ, Norris CM, Jr., et al. Salivary gland tumors treated with adjuvant intensity-modulated radiotherapy with or without concurrent chemotherapy. Int J Radiat Oncol Biol Phys 2012;82:308–314. Available at: http://www.ncbi.nlm.nih.gov/pubmed/21075557.

200. Gregoire V, Mackie TR. State of the art on dose prescription, reporting and recording in Intensity-Modulated Radiation Therapy (ICRU report No. 83). Cancer Radiother 2011;15:555–559. Available at: http://www.ncbi.nlm.nih.gov/pubmed/21802333.

201. Chao KS, Majhail N, Huang CJ, et al. Intensity-modulated radiation therapy reduces late salivary toxicity without compromising tumor control in patients with oropharyngeal carcinoma: a comparison with conventional techniques. Radiother Oncol 2001;61:275–280. Available at: http://www.ncbi.nlm.nih.gov/pubmed/11730997.

202. Dogan N, King S, Emami B, et al. Assessment of different IMRT boost delivery methods on target coverage and normal-tissue sparing. Int J Radiat Oncol Biol Phys 2003;57:1480–1491. Available at: http://www.ncbi.nlm.nih.gov/pubmed/14630288.

203. Li Y, Taylor JMG, Ten Haken RK, Eisbruch A. The impact of dose on parotid salivary recovery in head and neck cancer patients treated with radiation therapy. Int J Radiat Oncol Biol Phys 2007;67:660–669. Available at: http://www.ncbi.nlm.nih.gov/pubmed/17141973.

204. Gregoire V, Jeraj R, Lee JA, O'Sullivan B. Radiotherapy for head and neck tumours in 2012 and beyond: conformal, tailored, and adaptive? Lancet Oncol 2012;13:e292–300. Available at: http://www.ncbi.nlm.nih.gov/pubmed/22748268.

Discussion update in progress

Version 1.2026 © 2025 National Comprehensive Cancer Network© (NCCN©), All rights reserved. NCCN Guidelines® and this illustration may not be reproduced in any form without the express written permission of NCCN.

PLEASE NOTE that use of this NCCN Content is governed by the End-User License Agreement, and you MAY NOT distribute this Content or use it with any artificial intelligence model or tool.
Printed by Galya Basol Kochav on 1/4/2026 9:40:35 AM. Copyright © 2026 National Comprehensive Cancer Network, Inc. All Rights Reserved.

205. Galvin JM, De Neve W. Intensity modulating and other radiation therapy devices for dose painting. J Clin Oncol 2007;25:924–930. Available at: http://www.ncbi.nlm.nih.gov/pubmed/17350940.

206. Lauve A, Morris M, Schmidt-Ullrich R, et al. Simultaneous integrated boost intensity-modulated radiotherapy for locally advanced head-and-neck squamous cell carcinomas: II--clinical results. Int J Radiat Oncol Biol Phys 2004;60:374–387. Available at: http://www.ncbi.nlm.nih.gov/pubmed/15380569.

207. Schoenfeld GO, Amdur RJ, Morris CG, et al. Patterns of failure and toxicity after intensity-modulated radiotherapy for head and neck cancer. Int J Radiat Oncol Biol Phys 2008;71:377–385. Available at: http://www.ncbi.nlm.nih.gov/pubmed/18164838.

208. Wu Q, Mohan R, Morris M, et al. Simultaneous integrated boost intensity-modulated radiotherapy for locally advanced head-and-neck squamous cell carcinomas. I: dosimetric results. Int J Radiat Oncol Biol Phys 2003;56:573–585. Available at: http://www.ncbi.nlm.nih.gov/pubmed/12738335.

209. Jiang L, Zhang Y, Yang Z, et al. A comparison of clinical outcomes between simultaneous integrated boost (SIB) versus sequential boost (SEQ) intensity modulated radiation therapy (IMRT) for head and neck cancer: a meta-analysis. Medicine (Baltimore) 2019;98:e16942. Available at: https://www.ncbi.nlm.nih.gov/pubmed/31441887.

210. Ang KK, Chen A, Curran WJ, Jr., et al. Head and neck carcinoma in the United States: first comprehensive report of the Longitudinal Oncology Registry of Head and Neck Carcinoma (LORHAN). Cancer 2012;118:5783–5792. Available at: http://www.ncbi.nlm.nih.gov/pubmed/22569917.

211. Guadagnolo BA, Liu CC, Cormier JN, Du XL. Evaluation of trends in the use of intensity-modulated radiotherapy for head and neck cancer from 2000 through 2005: socioeconomic disparity and geographic variation in a large population-based cohort. Cancer 2010;116:3505–3512. Available at: http://www.ncbi.nlm.nih.gov/pubmed/20564123.

212. Lee NY, de Arruda FF, Puri DR, et al. A comparison of intensity-modulated radiation therapy and concomitant boost radiotherapy in the setting of concurrent chemotherapy for locally advanced oropharyngeal carcinoma. Int J Radiat Oncol Biol Phys 2006;66:966–974. Available at: https://www.ncbi.nlm.nih.gov/pubmed/17145527.

213. Hodge CW, Bentzen SM, Wong G, et al. Are we influencing outcome in oropharynx cancer with intensity-modulated radiotherapy? An inter-era comparison. Int J Radiat Oncol Biol Phys 2007;69:1032–1041. Available at: http://www.ncbi.nlm.nih.gov/pubmed/17967300.

214. Veldeman L, Madani I, Hulstaert F, et al. Evidence behind use of intensity-modulated radiotherapy: a systematic review of comparative clinical studies. Lancet Oncol 2008;9:367–375. Available at: http://www.ncbi.nlm.nih.gov/pubmed/18374290.

215. Moon SH, Cho KH, Lee CG, et al. IMRT vs. 2D-radiotherapy or 3D-conformal radiotherapy of nasopharyngeal carcinoma : Survival outcome in a Korean multi-institutional retrospective study (KROG 11-06). Strahlenther Onkol 2016;192:377–385. Available at: https://www.ncbi.nlm.nih.gov/pubmed/26972085.

216. Vergeer MR, Doornaert PA, Rietveld DH, et al. Intensity-modulated radiotherapy reduces radiation-induced morbidity and improves health-related quality of life: results of a nonrandomized prospective study using a standardized follow-up program. Int J Radiat Oncol Biol Phys 2009;74:1–8. Available at: http://www.ncbi.nlm.nih.gov/pubmed/19111400.

217. Pow EHN, Kwong DLW, McMillan AS, et al. Xerostomia and quality of life after intensity-modulated radiotherapy vs. conventional radiotherapy for early-stage nasopharyngeal carcinoma: initial report on a randomized controlled clinical trial. Int J Radiat Oncol Biol Phys 2006;66:981–991. Available at: http://www.ncbi.nlm.nih.gov/pubmed/17145528.

218. Pfister D, Cassileth B, Deng G, et al. Acupuncture for pain and dysfunction after neck dissection: Results of a randomized controlled trial. J Clin Oncol 2010;28:2565–2570. Available at: http://www.ncbi.nlm.nih.gov/pubmed/20406930.

Discussion update in progress

Version 1.2026 © 2025 National Comprehensive Cancer Network© (NCCN©), All rights reserved. NCCN Guidelines® and this illustration may not be reproduced in any form without the express written permission of NCCN.

PLEASE NOTE that use of this NCCN Content is governed by the End-User License Agreement, and you MAY NOT distribute this Content or use it with any artificial intelligence model or tool.
Printed by Galya Basol Kochav on 1/4/2026 9:40:35 AM. Copyright © 2026 National Comprehensive Cancer Network, Inc. All Rights Reserved.

219. Scarantino C, LeVeque F, Swann RS, et al. Effect of pilocarpine during radiation therapy: results of RTOG 97-09, a phase III randomized study in head and neck cancer patients. J Support Oncol 2006;4:252–258. Available at: http://www.ncbi.nlm.nih.gov/pubmed/16724649.

220. Petrone D, Condemi JJ, Fife R, et al. A double-blind, randomized, placebo-controlled study of cevimeline in Sjogren's syndrome patients with xerostomia and keratoconjunctivitis sicca. Arthritis Rheum 2002;46:748–754. Available at: http://www.ncbi.nlm.nih.gov/pubmed/11920411.

221. Tao Y, Auperin A, Blanchard P, et al. Concurrent cisplatin and dose escalation with intensity-modulated radiotherapy (IMRT) versus conventional radiotherapy for locally advanced head and neck squamous cell carcinomas (HNSCC): GORTEC 2004-01 randomized phase III trial. Radiother Oncol 2020;150:18–25. Available at: https://www.ncbi.nlm.nih.gov/pubmed/32417348.

222. Chi A, Nguyen NP, Tse W, et al. Intensity modulated radiotherapy for sinonasal malignancies with a focus on optic pathway preservation. J Hematol Oncol 2013;6:4. Available at: http://www.ncbi.nlm.nih.gov/pubmed/23294673.

223. Garden AS, Morrison WH, Wong P-F, et al. Disease-control rates following intensity-modulated radiation therapy for small primary oropharyngeal carcinoma. Int J Radiat Oncol Biol Phys 2007;67:438–444. Available at: http://www.ncbi.nlm.nih.gov/pubmed/17141972.

224. Eisbruch A, Levendag PC, Feng FY, et al. Can IMRT or brachytherapy reduce dysphagia associated with chemoradiotherapy of head and neck cancer? The Michigan and Rotterdam experiences. Int J Radiat Oncol Biol Phys 2007;69:S40–42. Available at: http://www.ncbi.nlm.nih.gov/pubmed/17848291.

225. Madani I, Bonte K, Vakaet L, et al. Intensity-modulated radiotherapy for sinonasal tumors: Ghent University Hospital update. Int J Radiat Oncol Biol Phys 2009;73:424–432. Available at: http://www.ncbi.nlm.nih.gov/pubmed/18755554.

226. Eisbruch A. Reducing xerostomia by IMRT: what may, and may not, be achieved. J Clin Oncol 2007;25:4863–4864. Available at: http://www.ncbi.nlm.nih.gov/pubmed/17971579.

227. Nutting CM, Morden JP, Beasley M, et al. Results of a multicentre randomised controlled trial of cochlear-sparing intensity-modulated radiotherapy versus conventional radiotherapy in patients with parotid cancer (COSTAR; CRUK/08/004). Eur J Cancer 2018;103:249–258. Available at: https://www.ncbi.nlm.nih.gov/pubmed/30286418.

228. Nutting C, Finneran L, Roe J, et al. Dysphagia-optimised intensity-modulated radiotherapy versus standard intensity-modulated radiotherapy in patients with head and neck cancer (DARS): a phase 3, multicentre, randomised, controlled trial. Lancet Oncol 2023;24:868–880. Available at: https://www.ncbi.nlm.nih.gov/pubmed/37423227.

229. Beadle BM, Liao KP, Giordano SH, et al. Reduced feeding tube duration with intensity-modulated radiation therapy for head and neck cancer: a Surveillance, Epidemiology, and End Results-Medicare analysis. Cancer 2017;123:283–293. Available at: https://www.ncbi.nlm.nih.gov/pubmed/27662641.

230. Rosenthal DI, Chambers MS, Fuller CD, et al. Beam path toxicities to non-target structures during intensity-modulated radiation therapy for head and neck cancer. Int J Radiat Oncol Biol Phys 2008;72:747–755. Available at: http://www.ncbi.nlm.nih.gov/pubmed/18455324.

231. Kocak-Uzel E, Gunn GB, Colen RR, et al. Beam path toxicity in candidate organs-at-risk: assessment of radiation emetogenesis for patients receiving head and neck intensity modulated radiotherapy. Radiother Oncol 2014;111:281–288. Available at: http://www.ncbi.nlm.nih.gov/pubmed/24746582.

232. Hutcheson K, Lewin J, Garden A, et al. Early experience with IMPT for the treatment of oropharyngeal tumors: Acute toxicities and swallowing-related outcomes. Int J Radiat Oncol Biol Phys 2013;87:S604. Available at: http://www.redjournal.org/article/S0360-3016(13)02267-0/abstract.

Discussion update in progress

Version 1.2026 © 2025 National Comprehensive Cancer Network© (NCCN©), All rights reserved. NCCN Guidelines® and this illustration may not be reproduced in any form without the express written permission of NCCN.

PLEASE NOTE that use of this NCCN Content is governed by the End-User License Agreement, and you MAY NOT distribute this Content or use it with any artificial intelligence model or tool.
Printed by Galya Basol Kochav on 1/4/2026 9:40:35 AM. Copyright © 2026 National Comprehensive Cancer Network, Inc. All Rights Reserved.

233. Holliday EB, Frank SJ. Proton radiation therapy for head and neck cancer: a review of the clinical experience to date. Int J Radiat Oncol Biol Phys 2014;89:292–302. Available at: http://www.ncbi.nlm.nih.gov/pubmed/24837890.

234. Frank SJ. Intensity-modulated proton beam therapy (IMPT) versus intensity-modulated photon therapy (IMRT). 2015. Available at: http://clinicaltrials.gov/show/NCT01893307.

235. Miller RC, Lodge M, Murad MH, Jones B. Controversies in clinical trials in proton radiotherapy: the present and the future. Semin Radiat Oncol 2013;23:127–133. Available at: http://www.ncbi.nlm.nih.gov/pubmed/23473690.

236. Zenda S, Kawashima M, Nishio T, et al. Proton beam therapy as a nonsurgical approach to mucosal melanoma of the head and neck: a pilot study. Int J Radiat Oncol Biol Phys 2011;81:135–139. Available at: http://www.ncbi.nlm.nih.gov/pubmed/20950948.

237. Demizu Y, Fujii O, Terashima K, et al. Particle therapy for mucosal melanoma of the head and neck. A single-institution retrospective comparison of proton and carbon ion therapy. Strahlenther Onkol 2014;190:186–191. Available at: http://www.ncbi.nlm.nih.gov/pubmed/24362502.

238. Fuji H, Yoshikawa S, Kasami M, et al. High-dose proton beam therapy for sinonasal mucosal malignant melanoma. Radiat Oncol 2014;9:162. Available at: http://www.ncbi.nlm.nih.gov/pubmed/25056641.

239. Allen AM, Pawlicki T, Dong L, et al. An evidence based review of proton beam therapy: the report of ASTRO's emerging technology committee. Radiother Oncol 2012;103:8–11. Available at: http://www.ncbi.nlm.nih.gov/pubmed/22405807.

240. Bhattasali O, Holliday E, Kies MS, et al. Definitive proton radiation therapy and concurrent cisplatin for unresectable head and neck adenoid cystic carcinoma: A series of 9 cases and a critical review of the literature. Head Neck 2016;38 Suppl 1:E1472–1480. Available at: https://www.ncbi.nlm.nih.gov/pubmed/26561041.

241. Gunn GB, Blanchard P, Garden AS, et al. Clinical outcomes and patterns of disease recurrence after intensity modulated proton therapy for oropharyngeal squamous carcinoma. Int J Radiat Oncol Biol Phys 2016;95:360–367. Available at: https://www.ncbi.nlm.nih.gov/pubmed/27084653.

242. Sio TT, Lin HK, Shi Q, et al. Intensity modulated proton therapy versus intensity modulated photon radiation therapy for oropharyngeal cancer: first comparative results of patient-reported outcomes. Int J Radiat Oncol Biol Phys 2016;95:1107–1114. Available at: https://www.ncbi.nlm.nih.gov/pubmed/27354125.

243. Holliday EB, Kocak-Uzel E, Feng L, et al. Dosimetric advantages of intensity-modulated proton therapy for oropharyngeal cancer compared with intensity-modulated radiation: A case-matched control analysis. Med Dosim 2016;41:189–194. Available at: https://www.ncbi.nlm.nih.gov/pubmed/27158021.

244. Fan M, Kang JJ, Lee A, et al. Outcomes and toxicities of definitive radiotherapy and reirradiation using 3-dimensional conformal or intensity-modulated (pencil beam) proton therapy for patients with nasal cavity and paranasal sinus malignancies. Cancer 2020;126:1905–1916. Available at: https://www.ncbi.nlm.nih.gov/pubmed/32097507.

245. Fukumitsu N, Okumura T, Mizumoto M, et al. Outcome of T4 (International Union Against Cancer Staging System, 7th edition) or recurrent nasal cavity and paranasal sinus carcinoma treated with proton beam. Int J Radiat Oncol Biol Phys 2012;83:704–711. Available at: http://www.ncbi.nlm.nih.gov/pubmed/22099036.

246. Patel S, Kostaras X, Parliament M, et al. Recommendations for the referral of patients for proton-beam therapy, an Alberta Health Services report: a model for Canada? Curr Oncol 2014;21:251–262. Available at: http://www.ncbi.nlm.nih.gov/pubmed/25302033.

247. Patel SH, Wang Z, Wong WW, et al. Charged particle therapy versus photon therapy for paranasal sinus and nasal cavity malignant diseases: a systematic review and meta-analysis. Lancet Oncol 2014;15:1027–1038. Available at: http://www.ncbi.nlm.nih.gov/pubmed/24980873.

Discussion update in progress

Version 1.2026 © 2025 National Comprehensive Cancer Network© (NCCN©), All rights reserved. NCCN Guidelines® and this illustration may not be reproduced in any form without the express written permission of NCCN.

PLEASE NOTE that use of this NCCN Content is governed by the End-User License Agreement, and you MAY NOT distribute this Content or use it with any artificial intelligence model or tool.
Printed by Galya Basol Kochav on 1/4/2026 9:40:35 AM. Copyright © 2026 National Comprehensive Cancer Network, Inc. All Rights Reserved.

248. Romesser PB, Cahlon O, Scher E, et al. Proton beam radiation therapy results in significantly reduced toxicity compared with intensity-modulated radiation therapy for head and neck tumors that require ipsilateral radiation. Radiother Oncol 2016;118:286–292. Available at: https://www.ncbi.nlm.nih.gov/pubmed/26867969.

249. Russo AL, Adams JA, Weyman EA, et al. Long-term outcomes after proton beam therapy for sinonasal squamous cell carcinoma. Int J Radiat Oncol Biol Phys 2016;95:368–376. Available at: https://www.ncbi.nlm.nih.gov/pubmed/27084654.

250. Dagan R, Bryant C, Li Z, et al. Outcomes of sinonasal cancer treated with proton therapy. Int J Radiat Oncol Biol Phys 2016;95:377–385. Available at: https://www.ncbi.nlm.nih.gov/pubmed/27084655.

251. Blanchard P, Garden AS, Gunn GB, et al. Intensity-modulated proton beam therapy (IMPT) versus intensity-modulated photon therapy (IMRT) for patients with oropharynx cancer - A case matched analysis. Radiother Oncol 2016;120:48–55. Available at: https://www.ncbi.nlm.nih.gov/pubmed/27342249.

252. Lee A, Woods R, Mahfouz A, et al. Evaluation of proton therapy reirradiation for patients with recurrent head and neck squamous cell carcinoma. JAMA Netw Open 2023;6:e2250607. Available at: https://www.ncbi.nlm.nih.gov/pubmed/36689229.

253. Zenda S, Kohno R, Kawashima M, et al. Proton beam therapy for unresectable malignancies of the nasal cavity and paranasal sinuses. Int J Radiat Oncol Biol Phys 2011;81:1473–1478. Available at: http://www.ncbi.nlm.nih.gov/pubmed/20961697.

254. Santoni R, Liebsch N, Finkelstein DM, et al. Temporal lobe (TL) damage following surgery and high-dose photon and proton irradiation in 96 patients affected by chordomas and chondrosarcomas of the base of the skull. Int J Radiat Oncol Biol Phys 1998;41:59–68. Available at: http://www.ncbi.nlm.nih.gov/pubmed/9588918.

255. Munzenrider JE, Liebsch NJ. Proton therapy for tumors of the skull base. Strahlenther Onkol 1999;175 Suppl 2:57–63. Available at: http://www.ncbi.nlm.nih.gov/pubmed/10394399.

256. Fitzek MM, Thornton AF, Varvares M, et al. Neuroendocrine tumors of the sinonasal tract. Results of a prospective study incorporating chemotherapy, surgery, and combined proton-photon radiotherapy. Cancer 2002;94:2623–2634. Available at: http://www.ncbi.nlm.nih.gov/pubmed/12173330.

257. Chiu KW, Yu TP, Kao YS. A systematic review and meta-analysis of osteoradionecrosis following proton therapy in patients with head and neck cancer. Oral Oncol 2024;148:106649. Available at: https://www.ncbi.nlm.nih.gov/pubmed/38035508.

258. Singh A, Kitpanit S, Neal B, et al. Osteoradionecrosis of the jaw following proton radiation therapy for patients with head and neck cancer. JAMA Otolaryngol Head Neck Surg 2023;149:151–159. Available at: https://www.ncbi.nlm.nih.gov/pubmed/36547968.

259. Holliday EB, Esmaeli B, Pinckard J, et al. A multidisciplinary orbit-sparing treatment approach that includes proton therapy for epithelial tumors of the orbit and ocular adnexa. Int J Radiat Oncol Biol Phys 2016;95:344–352. Available at: https://www.ncbi.nlm.nih.gov/pubmed/26454680.

260. Pigneux J, Richaud PM, Lagarde C. The place of interstitial therapy using 192 iridium in the management of carcinoma of the lip. Cancer 1979;43:1073–1077. Available at: http://www.ncbi.nlm.nih.gov/pubmed/427714.

261. Budrukkar A, Murthy V, Kashid S, et al. Intensity-modulated radiation therapy alone versus intensity-modulated radiation therapy and brachytherapy for early-stage oropharyngeal cancers: results from a randomized controlled trial. Int J Radiat Oncol Biol Phys 2024;118:1541–1551. Available at: https://www.ncbi.nlm.nih.gov/pubmed/37660737.

262. Karam I, Poon I, Lee J, et al. Stereotactic body radiotherapy for head and neck cancer: an addition to the armamentarium against head and

Discussion update in progress

Version 1.2026 © 2025 National Comprehensive Cancer Network© (NCCN©), All rights reserved. NCCN Guidelines® and this illustration may not be reproduced in any form without the express written permission of NCCN.

PLEASE NOTE that use of this NCCN Content is governed by the End-User License Agreement, and you MAY NOT distribute this Content or use it with any artificial intelligence model or tool.
Printed by Galya Basol Kochav on 1/4/2026 9:40:35 AM. Copyright © 2026 National Comprehensive Cancer Network, Inc. All Rights Reserved.

neck cancer. Future Oncol 2015;11:2937–2947. Available at: https://www.ncbi.nlm.nih.gov/pubmed/26414213.

263. Khan L, Tjong M, Raziee H, et al. Role of stereotactic body radiotherapy for symptom control in head and neck cancer patients. Support Care Cancer 2015;23:1099–1103. Available at: https://www.ncbi.nlm.nih.gov/pubmed/25294656.

264. Ling DC, Vargo JA, Heron DE. Stereotactic body radiation therapy for recurrent head and neck cancer. Cancer J 2016;22:302–306. Available at: https://www.ncbi.nlm.nih.gov/pubmed/27441751.

265. Iqbal MS, West N, Richmond N, et al. A systematic review and practical considerations of stereotactic body radiotherapy in the treatment of head and neck cancer. Br J Radiol 2021;94:20200332. Available at: https://www.ncbi.nlm.nih.gov/pubmed/32960652.

266. Thariat J, Bosset M, Falcoz A, et al. Survival without quality of life deterioration in the GORTEC 2014-04 "OMET" randomized phase 2 trial in patients with head and neck cancer with oligometastases using stereotactic ablative radiation therapy (SABR) alone or chemotherapy and SABR. Int J Radiat Oncol Biol Phys 2025;121:1194–1206. Available at: https://www.ncbi.nlm.nih.gov/pubmed/39612953.

267. Vargo JA, Moiseenko V, Grimm J, et al. Head and neck tumor control probability: radiation dose-volume effects in stereotactic body radiation therapy for locally recurrent previously-irradiated head and neck cancer: Report of the AAPM working group. Int J Radiat Oncol Biol Phys 2021;110:137–146. Available at: https://www.ncbi.nlm.nih.gov/pubmed/29477291.

268. Vargo JA, Ferris RL, Ohr J, et al. A prospective phase 2 trial of reirradiation with stereotactic body radiation therapy plus cetuximab in patients with previously irradiated recurrent squamous cell carcinoma of the head and neck. Int J Radiat Oncol Biol Phys 2015;91:480–488. Available at: https://www.ncbi.nlm.nih.gov/pubmed/25680594.

269. Echevarria MI, Yang GQ, Chen DT, et al. Phase 1 dose escalation of stereotactic body radiation therapy and concurrent cisplatin for reirradiation of unresectable, recurrent squamous cell carcinoma of the head and neck. Int J Radiat Oncol Biol Phys 2023;117:341–347. Available at: https://www.ncbi.nlm.nih.gov/pubmed/37105404.

270. Colevas AD, Read R, Thornhill J, et al. Hypothyroidism incidence after multimodality treatment for stage III and IV squamous cell carcinomas of the head and neck. Int J Radiat Oncol Biol Phys 2001;51:599–604. Available at: http://www.ncbi.nlm.nih.gov/pubmed/11597798.

271. Tell R, Lundell G, Nilsson B, et al. Long-term incidence of hypothyroidism after radiotherapy in patients with head-and-neck cancer. Int J Radiat Oncol Biol Phys 2004;60:395–400. Available at: http://www.ncbi.nlm.nih.gov/pubmed/15380571.

272. Posner MR, Ervin TJ, Miller D, et al. Incidence of hypothyroidism following multimodality treatment for advanced squamous cell cancer of the head and neck. Laryngoscope 1984;94:451–454. Available at: http://www.ncbi.nlm.nih.gov/pubmed/6708688.

273. Adelstein DJ, Li Y, Adams GL, et al. An intergroup phase III comparison of standard radiation therapy and two schedules of concurrent chemoradiotherapy in patients with unresectable squamous cell head and neck cancer. J Clin Oncol 2003;21:92–98. Available at: http://www.ncbi.nlm.nih.gov/pubmed/12506176.

274. Lo TC, Wiley AL, Jr., Ansfield FJ, et al. Combined radiation therapy and 5-fluorouracil for advanced squamous cell carcinoma of the oral cavity and oropharynx: a randomized study. AJR Am J Roentgenol 1976;126:229–235. Available at: http://www.ncbi.nlm.nih.gov/pubmed/175693.

275. Sanchiz F, Milla A, Torner J, et al. Single fraction per day versus two fractions per day versus radiochemotherapy in the treatment of head and neck cancer. Int J Radiat Oncol Biol Phys 1990;19:1347–1350. Available at: http://www.ncbi.nlm.nih.gov/pubmed/2262356.

276. Browman GP, Cripps C, Hodson DI, et al. Placebo-controlled randomized trial of infusional fluorouracil during standard radiotherapy in

Discussion update in progress

Version 1.2026 © 2025 National Comprehensive Cancer Network© (NCCN©), All rights reserved. NCCN Guidelines® and this illustration may not be reproduced in any form without the express written permission of NCCN.

PLEASE NOTE that use of this NCCN Content is governed by the End-User License Agreement, and you MAY NOT distribute this Content or use it with any artificial intelligence model or tool.
Printed by Galya Basol Kochav on 1/4/2026 9:40:35 AM. Copyright © 2026 National Comprehensive Cancer Network, Inc. All Rights Reserved.

locally advanced head and neck cancer. J Clin Oncol 1994;12:2648–2653. Available at: http://www.ncbi.nlm.nih.gov/pubmed/7989940.

277. Smid L, Lesnicar H, Zakotnik B, et al. Radiotherapy, combined with simultaneous chemotherapy with mitomycin C and bleomycin for inoperable head and neck cancer--preliminary report. Int J Radiat Oncol Biol Phys 1995;32:769–775. Available at: http://www.ncbi.nlm.nih.gov/pubmed/7540606.

278. Merlano M, Benasso M, Corvo R, et al. Five-year update of a randomized trial of alternating radiotherapy and chemotherapy compared with radiotherapy alone in treatment of unresectable squamous cell carcinoma of the head and neck. J Natl Cancer Inst 1996;88:583–589. Available at: http://www.ncbi.nlm.nih.gov/pubmed/8609658.

279. Brizel DM, Albers ME, Fisher SR, et al. Hyperfractionated irradiation with or without concurrent chemotherapy for locally advanced head and neck cancer. N Engl J Med 1998;338:1798–1804. Available at: http://www.ncbi.nlm.nih.gov/pubmed/9632446.

280. Wendt TG, Grabenbauer GG, Rodel CM, et al. Simultaneous radiochemotherapy versus radiotherapy alone in advanced head and neck cancer: a randomized multicenter study. J Clin Oncol 1998;16:1318–1324. Available at: http://www.ncbi.nlm.nih.gov/pubmed/9552032.

281. Jeremic B, Shibamoto Y, Milicic B, et al. Hyperfractionated radiation therapy with or without concurrent low-dose daily cisplatin in locally advanced squamous cell carcinoma of the head and neck: a prospective randomized trial. J Clin Oncol 2000;18:1458–1464. Available at: http://www.ncbi.nlm.nih.gov/pubmed/10735893.

282. Munro AJ. An overview of randomised controlled trials of adjuvant chemotherapy in head and neck cancer. Br J Cancer 1995;71:83–91. Available at: http://www.ncbi.nlm.nih.gov/pubmed/7819055.

283. El-Sayed S, Nelson N. Adjuvant and adjunctive chemotherapy in the management of squamous cell carcinoma of the head and neck region. A meta-analysis of prospective and randomized trials. J Clin Oncol 1996;14:838–847. Available at: http://www.ncbi.nlm.nih.gov/pubmed/8622032.

284. Pignon JP, Bourhis J, Domenge C, Designe L. Chemotherapy added to locoregional treatment for head and neck squamous-cell carcinoma: three meta-analyses of updated individual data. MACH-NC Collaborative Group. Meta-Analysis of Chemotherapy on Head and Neck Cancer. Lancet 2000;355:949–955. Available at: http://www.ncbi.nlm.nih.gov/pubmed/10768432.

285. Bourhis J, Amand C, Pignon J-P. Update of MACH-NC (Meta-Analysis of Chemotherapy in Head & Neck Cancer) database focused on concomitant chemoradiotherapy [abstract]. J Clin Oncol 2004;22(Suppl 14):Abstract 5505. Available at: http://meeting.ascopubs.org/cgi/content/abstract/22/14_suppl/5505.

286. Pignon JP, le Maitre A, Bourhis J. Meta-analyses of chemotherapy in head and neck cancer (MACH-NC): an update. Int J Radiat Oncol Biol Phys 2007;69:S112–114. Available at: http://www.ncbi.nlm.nih.gov/pubmed/17848275.

287. De Felice F, Belgioia L, Alterio D, et al. Survival and toxicity of weekly cisplatin chemoradiotherapy versus three-weekly cisplatin chemoradiotherapy for head and neck cancer: a systematic review and meta-analysis endorsed by the Italian Association of Radiotherapy and Clinical Oncology (AIRO). Crit Rev Oncol Hematol 2021;162:103345. Available at: https://www.ncbi.nlm.nih.gov/pubmed/33933569.

288. Rubin Grandis J, Melhem MF, Gooding WE, et al. Levels of TGF-alpha and EGFR protein in head and neck squamous cell carcinoma and patient survival. J Natl Cancer Inst 1998;90:824–832. Available at: https://www.ncbi.nlm.nih.gov/pubmed/9625170.

289. Zhu X, Zhang F, Zhang W, et al. Prognostic role of epidermal growth factor receptor in head and neck cancer: a meta-analysis. J Surg Oncol 2013;108:387–397. Available at: https://www.ncbi.nlm.nih.gov/pubmed/24038070.

Discussion update in progress

Version 1.2026 © 2025 National Comprehensive Cancer Network© (NCCN©), All rights reserved. NCCN Guidelines® and this illustration may not be reproduced in any form without the express written permission of NCCN.

PLEASE NOTE that use of this NCCN Content is governed by the End-User License Agreement, and you MAY NOT distribute this Content or use it with any artificial intelligence model or tool.
Printed by Galya Basol Kochav on 1/4/2026 9:40:35 AM. Copyright © 2026 National Comprehensive Cancer Network, Inc. All Rights Reserved.

290. Bonner JA, Harari PM, Giralt J, et al. Radiotherapy plus cetuximab for squamous-cell carcinoma of the head and neck. N Engl J Med 2006;354:567–578. Available at: http://www.ncbi.nlm.nih.gov/pubmed/16467544.

291. Bonner JA, Harari PM, Giralt J, et al. Radiotherapy plus cetuximab for locoregionally advanced head and neck cancer: 5-year survival data from a phase 3 randomised trial, and relation between cetuximab-induced rash and survival. Lancet Oncol 2010;11:21–28. Available at: http://www.ncbi.nlm.nih.gov/pubmed/19897418.

292. Ang KK, Zhang Q, Rosenthal DI, et al. Randomized phase III trial of concurrent accelerated radiation plus cisplatin with or without cetuximab for stage III to IV head and neck carcinoma: RTOG 0522. J Clin Oncol 2014;32:2940–2950. Available at: https://www.ncbi.nlm.nih.gov/pubmed/25154822.

293. Caudell JJ, Torres-Saavedra PA, Rosenthal DI, et al. Long-Term Update of NRG/RTOG 0522: A Randomized Phase 3 Trial of Concurrent Radiation and Cisplatin With or Without Cetuximab in Locoregionally Advanced Head and Neck Cancer. Int J Radiat Oncol Biol Phys 2023;116:533–543. Available at: https://www.ncbi.nlm.nih.gov/pubmed/36549347.

294. Tao Y, Auperin A, Sire C, et al. Improved outcome by adding concurrent chemotherapy to cetuximab and radiotherapy for locally advanced head and neck carcinomas: results of the GORTEC 2007-01 phase III randomized trial. J Clin Oncol 2018:JCO2017762518. Available at: https://www.ncbi.nlm.nih.gov/pubmed/29878867.

295. Gillison ML, Trotti AM, Harris J, et al. Radiotherapy plus cetuximab or cisplatin in human papillomavirus-positive oropharyngeal cancer (NRG Oncology RTOG 1016): a randomised, multicentre, non-inferiority trial. Lancet 2019;393:40–50. Available at: https://www.ncbi.nlm.nih.gov/pubmed/30449625.

296. Mehanna H, Robinson M, Hartley A, et al. Radiotherapy plus cisplatin or cetuximab in low-risk human papillomavirus-positive oropharyngeal cancer (De-ESCALaTE HPV): an open-label randomised controlled phase 3 trial. Lancet 2019;393:51–60. Available at: https://www.ncbi.nlm.nih.gov/pubmed/30449623.

297. Rischin D, King M, Kenny L, et al. Randomized trial of radiation therapy with weekly cisplatin or cetuximab in low-risk HPV-associated oropharyngeal cancer (TROG 12.01) - a Trans-Tasman Radiation Oncology Group Study. Int J Radiat Oncol Biol Phys 2021;111:876–886. Available at: https://www.ncbi.nlm.nih.gov/pubmed/34098030.

298. Forastiere AA, Zhang Q, Weber RS, et al. Long-term results of RTOG 91-11: a comparison of three nonsurgical treatment strategies to preserve the larynx in patients with locally advanced larynx cancer. J Clin Oncol 2013;31:845–852. Available at: http://www.ncbi.nlm.nih.gov/pubmed/23182993.

299. Ko EC, Genden EM, Misiukiewicz K, et al. Toxicity profile and clinical outcomes in locally advanced head and neck cancer patients treated with induction chemotherapy prior to concurrent chemoradiation. Oncol Rep 2012;27:467–474. Available at: http://www.ncbi.nlm.nih.gov/pubmed/22020564.

300. Lefebvre JL, Chevalier D, Luboinski B, et al. Larynx preservation in pyriform sinus cancer: preliminary results of a European Organization for Research and Treatment of Cancer phase III trial. EORTC Head and Neck Cancer Cooperative Group. J Natl Cancer Inst 1996;88:890–899. Available at: http://www.ncbi.nlm.nih.gov/pubmed/8656441.

301. Induction chemotherapy plus radiation compared with surgery plus radiation in patients with advanced laryngeal cancer. The Department of Veterans Affairs Laryngeal Cancer Study Group. N Engl J Med 1991;324:1685–1690. Available at: http://www.ncbi.nlm.nih.gov/pubmed/2034244.

302. McNeil BJ, Weichselbaum R, Pauker SG. Speech and survival: tradeoffs between quality and quantity of life in laryngeal cancer. N Engl J Med 1981;305:982–987. Available at: http://www.ncbi.nlm.nih.gov/pubmed/7278922.

Discussion update in progress

Version 1.2026 © 2025 National Comprehensive Cancer Network© (NCCN©), All rights reserved. NCCN Guidelines® and this illustration may not be reproduced in any form without the express written permission of NCCN.

PLEASE NOTE that use of this NCCN Content is governed by the End-User License Agreement, and you MAY NOT distribute this Content or use it with any artificial intelligence model or tool.
Printed by Galya Basol Kochav on 1/4/2026 9:40:35 AM. Copyright © 2026 National Comprehensive Cancer Network, Inc. All Rights Reserved.

303. Pignon J-P, le Maitre A, Maillard E, Bourhis J. Meta-analysis of chemotherapy in head and neck cancer (MACH-NC): an update on 93 randomised trials and 17,346 patients. Radiother Oncol 2009;92:4–14. Available at: http://www.ncbi.nlm.nih.gov/pubmed/19446902.

304. Forastiere AA, Goepfert H, Maor M, et al. Concurrent chemotherapy and radiotherapy for organ preservation in advanced laryngeal cancer. N Engl J Med 2003;349:2091–2098. Available at: http://www.ncbi.nlm.nih.gov/pubmed/14645636.

305. Hanna GJ, Haddad RI, Lorch JH. Induction chemotherapy for locoregionally advanced head and neck cancer: past, present, future? Oncologist 2013;18:288–293. Available at: http://www.ncbi.nlm.nih.gov/pubmed/23442306.

306. Argiris A, Haraf DJ, Kies MS, Vokes EE. Intensive concurrent chemoradiotherapy for head and neck cancer with 5-Fluorouracil- and hydroxyurea-based regimens: reversing a pattern of failure. Oncologist 2003;8:350–360. Available at: http://www.ncbi.nlm.nih.gov/pubmed/12897332.

307. Machtay M, Moughan J, Farach A, et al. Hypopharyngeal dose is associated with severe late toxicity in locally advanced head-and-neck cancer: an RTOG analysis. Int J Radiat Oncol Biol Phys 2012;84:983–989. Available at: http://www.ncbi.nlm.nih.gov/pubmed/23078898.

308. Lorch JH, Goloubeva O, Haddad RI, et al. Induction chemotherapy with cisplatin and fluorouracil alone or in combination with docetaxel in locally advanced squamous-cell cancer of the head and neck: long-term results of the TAX 324 randomised phase 3 trial. Lancet Oncol 2011;12:153–159. Available at: http://www.ncbi.nlm.nih.gov/pubmed/21233014.

309. Hitt R, Lopez-Pousa A, Martinez-Trufero J, et al. Phase III study comparing cisplatin plus fluorouracil to paclitaxel, cisplatin, and fluorouracil induction chemotherapy followed by chemoradiotherapy in locally advanced head and neck cancer. J Clin Oncol 2005;23:8636–8645. Available at: http://www.ncbi.nlm.nih.gov/pubmed/16275937.

310. Posner MR, Hershock DM, Blajman CR, et al. Cisplatin and fluorouracil alone or with docetaxel in head and neck cancer. N Engl J Med 2007;357:1705–1715. Available at: http://www.ncbi.nlm.nih.gov/pubmed/17960013.

311. Vermorken JB, Remenar E, van Herpen C, et al. Cisplatin, fluorouracil, and docetaxel in unresectable head and neck cancer. N Engl J Med 2007;357:1695–1704. Available at: http://www.ncbi.nlm.nih.gov/pubmed/17960012.

312. Janoray G, Pointreau Y, Garaud P, et al. Long-term results of a multicenter randomized phase III trial of induction chemotherapy with cisplatin, 5-fluorouracil, +/- docetaxel for larynx preservation. J Natl Cancer Inst 2016;108:djv368. Available at: https://www.ncbi.nlm.nih.gov/pubmed/26681800.

313. Pointreau Y, Garaud P, Chapet S, et al. Randomized trial of induction chemotherapy with cisplatin and 5-fluorouracil with or without docetaxel for larynx preservation. J Natl Cancer Inst 2009;101:498–506. Available at: http://www.ncbi.nlm.nih.gov/pubmed/19318632.

314. Blanchard P, Bourhis J, Lacas B, et al. Taxane-cisplatin-fluorouracil as induction chemotherapy in locally advanced head and neck cancers: an individual patient data meta-analysis of the meta-analysis of chemotherapy in head and neck cancer group. J Clin Oncol 2013;31:2854–2860. Available at: https://www.ncbi.nlm.nih.gov/pubmed/23835714.

315. Hitt R, Grau JJ, Lopez-Pousa A, et al. A randomized phase III trial comparing induction chemotherapy followed by chemoradiotherapy versus chemoradiotherapy alone as treatment of unresectable head and neck cancer. Ann Oncol 2014;25:216–225. Available at: http://www.ncbi.nlm.nih.gov/pubmed/24256848.

316. Haddad R, O'Neill A, Rabinowits G, et al. Induction chemotherapy followed by concurrent chemoradiotherapy (sequential chemoradiotherapy) versus concurrent chemoradiotherapy alone in locally advanced head and neck cancer (PARADIGM): a randomised phase 3

Discussion update in progress

Version 1.2026 © 2025 National Comprehensive Cancer Network© (NCCN©), All rights reserved. NCCN Guidelines® and this illustration may not be reproduced in any form without the express written permission of NCCN.

PLEASE NOTE that use of this NCCN Content is governed by the End-User License Agreement, and you MAY NOT distribute this Content or use it with any artificial intelligence model or tool.
Printed by Galya Basol Kochav on 1/4/2026 9:40:35 AM. Copyright © 2026 National Comprehensive Cancer Network, Inc. All Rights Reserved.

trial. Lancet Oncol 2013;14:257–264. Available at: http://www.ncbi.nlm.nih.gov/pubmed/23414589.

317. Cohen EE, Karrison TG, Kocherginsky M, et al. Phase III randomized trial of induction chemotherapy in patients with N2 or N3 locally advanced head and neck cancer. J Clin Oncol 2014;32:2735–2743. Available at: https://www.ncbi.nlm.nih.gov/pubmed/25049329.

318. Paccagnella A, Ghi MG, Loreggian L, et al. Concomitant chemoradiotherapy versus induction docetaxel, cisplatin and 5 fluorouracil (TPF) followed by concomitant chemoradiotherapy in locally advanced head and neck cancer: a phase II randomized study. Ann Oncol 2010;21:1515–1522. Available at: http://www.ncbi.nlm.nih.gov/pubmed/20032123.

319. Ghi MG, Paccagnella A, Ferrari D, et al. Induction TPF followed by concomitant treatment versus concomitant treatment alone in locally advanced head and neck cancer. A phase II-III trial. Ann Oncol 2017;28:2206–2212. Available at: https://www.ncbi.nlm.nih.gov/pubmed/28911070.

320. Wanebo HJ, Lee J, Burtness BA, et al. Induction cetuximab, paclitaxel, and carboplatin followed by chemoradiation with cetuximab, paclitaxel, and carboplatin for stage III/IV head and neck squamous cancer: a phase II ECOG-ACRIN trial (E2303). Ann Oncol 2014;25:2036–2041. Available at: https://www.ncbi.nlm.nih.gov/pubmed/25009013.

321. Dietz A, Wichmann G, Kuhnt T, et al. Induction chemotherapy (IC) followed by radiotherapy (RT) versus cetuximab plus IC and RT in advanced laryngeal/hypopharyngeal cancer resectable only by total laryngectomy-final results of the larynx organ preservation trial DeLOS-II. Ann Oncol 2018;29:2105–2114. Available at: https://www.ncbi.nlm.nih.gov/pubmed/30412221.

322. Specenier PM, Remenar E, Buter J, et al. TPF plus cetuximab induction chemotherapy followed by biochemoradiation with weekly cetuximab plus weekly cisplatin or carboplatin: a randomized phase II EORTC trial. Ann Oncol 2017;28:2219–2224. Available at: https://www.ncbi.nlm.nih.gov/pubmed/28911062.

323. Haddad RI, Posner M, Hitt R, et al. Induction chemotherapy in locally advanced squamous cell carcinoma of the head and neck: role, controversy, and future directions. Ann Oncol 2018;29:1130–1140. Available at: https://www.ncbi.nlm.nih.gov/pubmed/29635316.

324. Lefebvre JL, Pointreau Y, Rolland F, et al. Induction chemotherapy followed by either chemoradiotherapy or bioradiotherapy for larynx preservation: the TREMPLIN randomized phase II study. J Clin Oncol 2013;31:853–859. Available at: http://www.ncbi.nlm.nih.gov/pubmed/23341517.

325. Janoray G, Pointreau Y, Alfonsi M, et al. Induction chemotherapy followed by cisplatin or cetuximab concomitant to radiotherapy for laryngeal/hypopharyngeal cancer: Long-term results of the TREMPLIN randomised GORTEC trial. Eur J Cancer 2020;133:86–93. Available at: https://www.ncbi.nlm.nih.gov/pubmed/32454417.

326. Hitt R, Mesia R, Lozano A, et al. Randomized phase 3 noninferiority trial of radiotherapy and cisplatin vs radiotherapy and cetuximab after docetaxel-cisplatin-fluorouracil induction chemotherapy in patients with locally advanced unresectable head and neck cancer. Oral Oncol 2022;134:106087. Available at: https://www.ncbi.nlm.nih.gov/pubmed/36126605.

327. Geoffrois L, Martin L, De Raucourt D, et al. Induction chemotherapy followed by cetuximab radiotherapy is not superior to concurrent chemoradiotherapy for head and neck carcinomas: results of the GORTEC 2007-02 phase III randomized trial. J Clin Oncol 2018;36:3077–3083. Available at: https://www.ncbi.nlm.nih.gov/pubmed/30016178.

328. Al-Sarraf M, LeBlanc M, Giri PG, et al. Chemoradiotherapy versus radiotherapy in patients with advanced nasopharyngeal cancer: phase III randomized Intergroup study 0099. J Clin Oncol 1998;16:1310–1317. Available at: http://www.ncbi.nlm.nih.gov/pubmed/9552031.

329. Kies MS, Holsinger FC, Lee JJ, et al. Induction chemotherapy and cetuximab for locally advanced squamous cell carcinoma of the head and neck: results from a phase II prospective trial. J Clin Oncol 2010;28:8–14. Available at: http://www.ncbi.nlm.nih.gov/pubmed/19917840.

Discussion update in progress

Version 1.2026 © 2025 National Comprehensive Cancer Network© (NCCN©), All rights reserved. NCCN Guidelines® and this illustration may not be reproduced in any form without the express written permission of NCCN.

PLEASE NOTE that use of this NCCN Content is governed by the End-User License Agreement, and you MAY NOT distribute this Content or use it with any artificial intelligence model or tool.
Printed by Galya Basol Kochav on 1/4/2026 9:40:35 AM. Copyright © 2026 National Comprehensive Cancer Network, Inc. All Rights Reserved.

330. Ready NE, Rathore R, Johnson TT, et al. Weekly paclitaxel and carboplatin induction chemotherapy followed by concurrent chemoradiotherapy in locally advanced squamous cell carcinoma of the head and neck. Am J Clin Oncol 2012;35:6–12. Available at: https://www.ncbi.nlm.nih.gov/pubmed/21293244.

331. Vokes EE, Stenson K, Rosen FR, et al. Weekly carboplatin and paclitaxel followed by concomitant paclitaxel, fluorouracil, and hydroxyurea chemoradiotherapy: curative and organ-preserving therapy for advanced head and neck cancer. J Clin Oncol 2003;21:320–326. Available at: http://www.ncbi.nlm.nih.gov/pubmed/12525525.

332. Cousins N, MacAulay F, Lang H, et al. A systematic review of interventions for eating and drinking problems following treatment for head and neck cancer suggests a need to look beyond swallowing and trismus. Oral Oncol 2013;49:387–400. Available at: http://www.ncbi.nlm.nih.gov/pubmed/23291294.

333. Locher JL, Bonner JA, Carroll WR, et al. Prophylactic percutaneous endoscopic gastrostomy tube placement in treatment of head and neck cancer: a comprehensive review and call for evidence-based medicine. JPEN J Parenter Enteral Nutr 2011;35:365–374. Available at: http://www.ncbi.nlm.nih.gov/pubmed/21527598.

334. Langius JA, van Dijk AM, Doornaert P, et al. More than 10% weight loss in head and neck cancer patients during radiotherapy is independently associated with deterioration in quality of life. Nutr Cancer 2013;65:76–83. Available at: http://www.ncbi.nlm.nih.gov/pubmed/23368916.

335. August DA, Huhmann MB, American Society for P, Enteral Nutrition Board of D. A.S.P.E.N. clinical guidelines: nutrition support therapy during adult anticancer treatment and in hematopoietic cell transplantation. JPEN J Parenter Enteral Nutr 2009;33:472–500. Available at: http://www.ncbi.nlm.nih.gov/pubmed/19713551.

336. Garg S, Yoo J, Winquist E. Nutritional support for head and neck cancer patients receiving radiotherapy: a systematic review. Support Care Cancer 2010;18:667–677. Available at: http://www.ncbi.nlm.nih.gov/pubmed/19582484.

337. Alshadwi A, Nadershah M, Carlson ER, et al. Nutritional considerations for head and neck cancer patients: a review of the literature. J Oral Maxillofac Surg 2013;71:1853–1860. Available at: https://www.ncbi.nlm.nih.gov/pubmed/23845698.

338. Deng J, Murphy BA, Dietrich MS, et al. Differences of symptoms in head and neck cancer patients with and without lymphedema. Support Care Cancer 2016;24:1305–1316. Available at: https://www.ncbi.nlm.nih.gov/pubmed/26314703.

339. Doersam JK, Dietrich MS, Adair MA, et al. A comparison of symptoms among patients with head and neck or truncal lymphedema and normal controls. Lymphat Res Biol 2019;17:661–670. Available at: https://www.ncbi.nlm.nih.gov/pubmed/31381475.

340. Jackson LK, Ridner SH, Deng J, et al. Internal lymphedema correlates with subjective and objective measures of dysphagia in head and neck cancer patients. J Palliat Med 2016;19:949–956. Available at: https://www.ncbi.nlm.nih.gov/pubmed/27227341.

341. Ridner SH, Dietrich MS, Niermann K, et al. A prospective study of the lymphedema and fibrosis continuum in patients with head and neck cancer. Lymphat Res Biol 2016;14:198–205. Available at: https://www.ncbi.nlm.nih.gov/pubmed/27305456.

342. Dysphagia Section OCSGMAoSCiCISoOO, Raber-Durlacher JE, Brennan MT, et al. Swallowing dysfunction in cancer patients. Support Care Cancer 2012;20:433–443. Available at: http://www.ncbi.nlm.nih.gov/pubmed/22205548.

343. Wilson JA, Carding PN, Patterson JM. Dysphagia after nonsurgical head and neck cancer treatment: patients' perspectives. Otolaryngol Head Neck Surg 2011;145:767–771. Available at: http://www.ncbi.nlm.nih.gov/pubmed/21746839.

Discussion update in progress

Version 1.2026 © 2025 National Comprehensive Cancer Network© (NCCN©), All rights reserved. NCCN Guidelines® and this illustration may not be reproduced in any form without the express written permission of NCCN.

PLEASE NOTE that use of this NCCN Content is governed by the End-User License Agreement, and you MAY NOT distribute this Content or use it with any artificial intelligence model or tool.
Printed by Galya Basol Kochav on 1/4/2026 9:40:35 AM. Copyright © 2026 National Comprehensive Cancer Network, Inc. All Rights Reserved.

344. Tschiesner U. Preservation of organ function in head and neck cancer. GMS Curr Top Otorhinolaryngol Head Neck Surg 2012;11:Doc07. Available at: http://www.ncbi.nlm.nih.gov/pubmed/23320059.

345. Bressan V, Bagnasco A, Aleo G, et al. The life experience of nutrition impact symptoms during treatment for head and neck cancer patients: a systematic review and meta-synthesis. Support Care Cancer 2017;25:1699–1712. Available at: https://www.ncbi.nlm.nih.gov/pubmed/28204992.

346. Roe JW, Carding PN, Rhys-Evans PH, et al. Assessment and management of dysphagia in patients with head and neck cancer who receive radiotherapy in the United Kingdom - a web-based survey. Oral Oncol 2012;48:343–348. Available at: http://www.ncbi.nlm.nih.gov/pubmed/22130454.

347. Russi EG, Corvo R, Merlotti A, et al. Swallowing dysfunction in head and neck cancer patients treated by radiotherapy: review and recommendations of the supportive task group of the Italian Association of Radiation Oncology. Cancer Treat Rev 2012;38:1033–1049. Available at: http://www.ncbi.nlm.nih.gov/pubmed/22542950.

348. Cnossen IC, de Bree R, Rinkel RN, et al. Computerized monitoring of patient-reported speech and swallowing problems in head and neck cancer patients in clinical practice. Support Care Cancer 2012;20:2925–2931. Available at: http://www.ncbi.nlm.nih.gov/pubmed/22395211.

349. Epstein JB, Thariat J, Bensadoun RJ, et al. Oral complications of cancer and cancer therapy: from cancer treatment to survivorship. CA Cancer J Clin 2012;62:400–422. Available at: http://www.ncbi.nlm.nih.gov/pubmed/22972543.

350. Vera-Llonch M, Oster G, Hagiwara M, Sonis S. Oral mucositis in patients undergoing radiation treatment for head and neck carcinoma. Cancer 2006;106:329–336. Available at: https://www.ncbi.nlm.nih.gov/pubmed/16342066.

351. Trotti A, Bellm LA, Epstein JB, et al. Mucositis incidence, severity and associated outcomes in patients with head and neck cancer receiving radiotherapy with or without chemotherapy: a systematic literature review. Radiother Oncol 2003;66:253–262. Available at: https://www.ncbi.nlm.nih.gov/pubmed/12742264.

352. Bar Ad V, Weinstein G, Dutta PR, et al. Gabapentin for the treatment of pain syndrome related to radiation-induced mucositis in patients with head and neck cancer treated with concurrent chemoradiotherapy. Cancer 2010;116:4206–4213. Available at: https://www.ncbi.nlm.nih.gov/pubmed/20564146.

353. Sroussi HY, Epstein JB, Bensadoun RJ, et al. Common oral complications of head and neck cancer radiation therapy: mucositis, infections, saliva change, fibrosis, sensory dysfunctions, dental caries, periodontal disease, and osteoradionecrosis. Cancer Med 2017;6:2918–2931. Available at: https://www.ncbi.nlm.nih.gov/pubmed/29071801.

354. Iovoli AJ, Turecki L, Qiu ML, et al. Severe oral mucositis after intensity-modulated radiation therapy for head and neck cancer. JAMA Netw Open 2023;6:e2337265. Available at: https://www.ncbi.nlm.nih.gov/pubmed/37819659.

355. Al-Ansari S, Zecha JA, Barasch A, et al. Oral mucositis induced by anticancer therapies. Curr Oral Health Rep 2015;2:202–211. Available at: https://www.ncbi.nlm.nih.gov/pubmed/26523246.

356. Feng M, Eisbruch A. Future issues in highly conformal radiotherapy for head and neck cancer. J Clin Oncol 2007;25:1009–1013. Available at: https://www.ncbi.nlm.nih.gov/pubmed/17350951.

357. Elting LS, Cooksley CD, Chambers MS, Garden AS. Risk, outcomes, and costs of radiation-induced oral mucositis among patients with head-and-neck malignancies. Int J Radiat Oncol Biol Phys 2007;68:1110–1120. Available at: https://www.ncbi.nlm.nih.gov/pubmed/17398022.

358. Hong CHL, Gueiros LA, Fulton JS, et al. Systematic review of basic oral care for the management of oral mucositis in cancer patients and clinical practice guidelines. Support Care Cancer 2019;27:3949–3967. Available at: https://www.ncbi.nlm.nih.gov/pubmed/31286232.

Discussion update in progress

Version 1.2026 © 2025 National Comprehensive Cancer Network© (NCCN©), All rights reserved. NCCN Guidelines® and this illustration may not be reproduced in any form without the express written permission of NCCN.

PLEASE NOTE that use of this NCCN Content is governed by the End-User License Agreement, and you MAY NOT distribute this Content or use it with any artificial intelligence model or tool.
Printed by Galya Basol Kochav on 1/4/2026 9:40:35 AM. Copyright © 2026 National Comprehensive Cancer Network, Inc. All Rights Reserved.

359. Saunders DP, Rouleau T, Cheng K, et al. Systematic review of antimicrobials, mucosal coating agents, anesthetics, and analgesics for the management of oral mucositis in cancer patients and clinical practice guidelines. Support Care Cancer 2020;28:2473–2484. Available at: https://www.ncbi.nlm.nih.gov/pubmed/32052137.

360. Sio TT, Le-Rademacher JG, Leenstra JL, et al. Effect of doxepin mouthwash or diphenhydramine-lidocaine-antacid mouthwash vs placebo on radiotherapy-related oral mucositis pain: the Alliance A221304 randomized clinical trial. JAMA 2019;321:1481–1490. Available at: https://www.ncbi.nlm.nih.gov/pubmed/30990550.

361. Smith DK, Cmelak A, Niermann K, et al. Preventive use of gabapentin to decrease pain and systemic symptoms in patients with head and neck cancer undergoing chemoradiation. Head Neck 2020;42:3497–3505. Available at: https://www.ncbi.nlm.nih.gov/pubmed/32770612.

362. Hermann GM, Iovoli AJ, Platek AJ, et al. A single-institution, randomized, pilot study evaluating the efficacy of gabapentin and methadone for patients undergoing chemoradiation for head and neck squamous cell cancer. Cancer 2020;126:1480–1491. Available at: https://www.ncbi.nlm.nih.gov/pubmed/31869451.

363. Ma SJ, Wang K, Iovoli AJ, et al. Association of gabapentin use with pain control and feeding tube placement among patients with head and neck cancer receiving chemoradiotherapy. JAMA Netw Open 2022;5:e2212900. Available at: https://www.ncbi.nlm.nih.gov/pubmed/35583872.

364. Jiang J, Li Y, Shen Q, et al. Effect of pregabalin on radiotherapy-related neuropathic pain in patients with head and neck cancer: a randomized controlled trial. J Clin Oncol 2019;37:135–143. Available at: https://www.ncbi.nlm.nih.gov/pubmed/30457920.

365. Bossola M. Nutritional interventions in head and neck cancer patients undergoing chemoradiotherapy: a narrative review. Nutrients 2015;7:265–276. Available at: https://www.ncbi.nlm.nih.gov/pubmed/25569622.

366. Talwar B, Donnelly R, Skelly R, Donaldson M. Nutritional management in head and neck cancer: United Kingdom National Multidisciplinary Guidelines. J Laryngol Otol 2016;130:S32–S40. Available at: https://www.ncbi.nlm.nih.gov/pubmed/27841109.

367. Sachdev S, Refaat T, Bacchus ID, et al. Age most significant predictor of requiring enteral feeding in head-and-neck cancer patients. Radiat Oncol 2015;10:93. Available at: https://www.ncbi.nlm.nih.gov/pubmed/25896830.

368. Koyfman SA, Adelstein DJ. Enteral feeding tubes in patients undergoing definitive chemoradiation therapy for head-and-neck cancer: a critical review. Int J Radiat Oncol Biol Phys 2012;84:581–589. Available at: https://www.ncbi.nlm.nih.gov/pubmed/22857885.

369. Walker MP, Wichman B, Cheng AL, et al. Impact of radiotherapy dose on dentition breakdown in head and neck cancer patients. Pract Radiat Oncol 2011;1:142–148. Available at: http://www.ncbi.nlm.nih.gov/pubmed/21857887.

370. Jensen SB, Pedersen AM, Vissink A, et al. A systematic review of salivary gland hypofunction and xerostomia induced by cancer therapies: prevalence, severity and impact on quality of life. Support Care Cancer 2010;18:1039–1060. Available at: http://www.ncbi.nlm.nih.gov/pubmed/20237805.

371. Deng J, Jackson L, Epstein JB, et al. Dental demineralization and caries in patients with head and neck cancer. Oral Oncol 2015;51:824–831. Available at: https://www.ncbi.nlm.nih.gov/pubmed/26198979.

372. Lalla RV, Treister N, Sollecito T, et al. Oral complications at 6 months after radiation therapy for head and neck cancer. Oral Dis 2017;23:1134–1143. Available at: https://www.ncbi.nlm.nih.gov/pubmed/28675770.

373. Epstein JB, Barasch A. Oral and dental health in head and neck cancer patients. Cancer Treat Res 2018;174:43–57. Available at: https://www.ncbi.nlm.nih.gov/pubmed/29435836.

Discussion update in progress

Version 1.2026 © 2025 National Comprehensive Cancer Network© (NCCN©), All rights reserved. NCCN Guidelines® and this illustration may not be reproduced in any form without the express written permission of NCCN.

PLEASE NOTE that use of this NCCN Content is governed by the End-User License Agreement, and you MAY NOT distribute this Content or use it with any artificial intelligence model or tool.
Printed by Galya Basol Kochav on 1/4/2026 9:40:35 AM. Copyright © 2026 National Comprehensive Cancer Network, Inc. All Rights Reserved.

374. Duarte VM, Liu YF, Rafizadeh S, et al. Comparison of dental health of patients with head and neck cancer receiving IMRT vs conventional radiation. Otolaryngol Head Neck Surg 2014;150:81–86. Available at: http://www.ncbi.nlm.nih.gov/pubmed/24145147.

375. Murdoch-Kinch CA, Kim HM, Vineberg KA, et al. Dose-effect relationships for the submandibular salivary glands and implications for their sparing by intensity modulated radiotherapy. Int J Radiat Oncol Biol Phys 2008;72:373–382. Available at: http://www.ncbi.nlm.nih.gov/pubmed/18337023.

376. Little M, Schipper M, Feng FY, et al. Reducing xerostomia after chemo-IMRT for head-and-neck cancer: beyond sparing the parotid glands. Int J Radiat Oncol Biol Phys 2012;83:1007–1014. Available at: http://www.ncbi.nlm.nih.gov/pubmed/22056067.

377. Chao KS. Protection of salivary function by intensity-modulated radiation therapy in patients with head and neck cancer. Semin Radiat Oncol 2002;12:20–25. Available at: http://www.ncbi.nlm.nih.gov/pubmed/11917280.

378. Murdoch-Kinch CA, Zwetchkenbaum S. Dental management of the head and neck cancer patient treated with radiation therapy. J Mich Dent Assoc 2011;93:28–37. Available at: http://www.ncbi.nlm.nih.gov/pubmed/21888251.

379. Studer G, Glanzmann C, Studer SP, et al. Risk-adapted dental care prior to intensity-modulated radiotherapy (IMRT). Schweiz Monatsschr Zahnmed 2011;121:216–229. Available at: http://www.ncbi.nlm.nih.gov/pubmed/21534021.

380. Ben-David MA, Diamante M, Radawski JD, et al. Lack of osteoradionecrosis of the mandible after intensity-modulated radiotherapy for head and neck cancer: likely contributions of both dental care and improved dose distributions. Int J Radiat Oncol Biol Phys 2007;68:396–402. Available at: http://www.ncbi.nlm.nih.gov/pubmed/17321069.

381. Thariat J, Ramus L, Darcourt V, et al. Compliance with fluoride custom trays in irradiated head and neck cancer patients. Support Care Cancer 2012;20:1811–1814. Available at: http://www.ncbi.nlm.nih.gov/pubmed/21947441.

382. Chang DT, Sandow PR, Morris CG, et al. Do pre-irradiation dental extractions reduce the risk of osteoradionecrosis of the mandible? Head Neck 2007;29:528–536. Available at: http://www.ncbi.nlm.nih.gov/pubmed/17230555.

383. Gevorgyan A, Wong K, Poon I, et al. Osteoradionecrosis of the mandible: a case series at a single institution. J Otolaryngol Head Neck Surg 2013;42:46. Available at: https://www.ncbi.nlm.nih.gov/pubmed/24025531.

384. Gomez DR, Estilo CL, Wolden SL, et al. Correlation of osteoradionecrosis and dental events with dosimetric parameters in intensity-modulated radiation therapy for head-and-neck cancer. Int J Radiat Oncol Biol Phys 2011;81:e207–213. Available at: http://www.ncbi.nlm.nih.gov/pubmed/21570202.

385. Jacobson AS, Buchbinder D, Hu K, Urken ML. Paradigm shifts in the management of osteoradionecrosis of the mandible. Oral Oncol 2010;46:795–801. Available at: https://www.ncbi.nlm.nih.gov/pubmed/20843728.

386. Lee IJ, Koom WS, Lee CG, et al. Risk factors and dose-effect relationship for mandibular osteoradionecrosis in oral and oropharyngeal cancer patients. Int J Radiat Oncol Biol Phys 2009;75:1084–1091. Available at: https://www.ncbi.nlm.nih.gov/pubmed/19327914.

387. O'Dell K, Sinha U. Osteoradionecrosis. Oral Maxillofac Surg Clin North Am 2011;23:455–464. Available at: https://www.ncbi.nlm.nih.gov/pubmed/21798443.

388. Oh HK, Chambers MS, Martin JW, et al. Osteoradionecrosis of the mandible: treatment outcomes and factors influencing the progress of osteoradionecrosis. J Oral Maxillofac Surg 2009;67:1378–1386. Available at: https://www.ncbi.nlm.nih.gov/pubmed/19531406.

Discussion update in progress

Version 1.2026 © 2025 National Comprehensive Cancer Network© (NCCN©), All rights reserved. NCCN Guidelines® and this illustration may not be reproduced in any form without the express written permission of NCCN.

PLEASE NOTE that use of this NCCN Content is governed by the End-User License Agreement, and you MAY NOT distribute this Content or use it with any artificial intelligence model or tool.
Printed by Galya Basol Kochav on 1/4/2026 9:40:35 AM. Copyright © 2026 National Comprehensive Cancer Network, Inc. All Rights Reserved.

389. Sohn HO, Park EY, Jung YS, et al. Effects of professional oral hygiene care in patients with head-and-neck cancer during radiotherapy: a randomized clinical trial. Indian J Dent Res 2018;29:700–704. Available at: https://www.ncbi.nlm.nih.gov/pubmed/30588994.

390. Schiodt M, Hermund NU. Management of oral disease prior to radiation therapy. Support Care Cancer 2002;10:40–43. Available at: http://www.ncbi.nlm.nih.gov/pubmed/11777187.

391. Rhodus NL, Bereuter J. Clinical evaluation of a commercially available oral moisturizer in relieving signs and symptoms of xerostomia in postirradiation head and neck cancer patients and patients with Sjogren's syndrome. J Otolaryngol 2000;29:28–34. Available at: http://www.ncbi.nlm.nih.gov/pubmed/10709169.

392. Singh ML, Papas AS. Long-term clinical observation of dental caries in salivary hypofunction patients using a supersaturated calcium-phosphate remineralizing rinse. J Clin Dent 2009;20:87–92. Available at: https://www.ncbi.nlm.nih.gov/pubmed/19711609.

393. Gorsky M, Epstein JB, Parry J, et al. The efficacy of pilocarpine and bethanechol upon saliva production in cancer patients with hyposalivation following radiation therapy. Oral Surg Oral Med Oral Pathol Oral Radiol Endod 2004;97:190–195. Available at: http://www.ncbi.nlm.nih.gov/pubmed/14970777.

394. Dholam KP, Somani PP, Prabhu SD, Ambre SR. Effectiveness of fluoride varnish application as cariostatic and desensitizing agent in irradiated head and neck cancer patients. Int J Dent 2013;2013:824982. Available at: http://www.ncbi.nlm.nih.gov/pubmed/23843793.

395. Shulman DH, Shipman B, Willis FB. Treating trismus with dynamic splinting: a case report. J Oral Sci 2009;51:141–144. Available at: http://www.ncbi.nlm.nih.gov/pubmed/19325212.

396. Teguh DN, Levendag PC, Voet P, et al. Trismus in patients with oropharyngeal cancer: relationship with dose in structures of mastication apparatus. Head Neck 2008;30:622–630. Available at: http://www.ncbi.nlm.nih.gov/pubmed/18213726.

397. Papas A, Russell D, Singh M, et al. Caries clinical trial of a remineralising toothpaste in radiation patients. Gerodontology 2008;25:76–88. Available at: http://www.ncbi.nlm.nih.gov/pubmed/18485139.

398. Wu F, Weng S, Li C, et al. Submandibular gland transfer for the prevention of postradiation xerostomia in patients with head and neck cancer: a systematic review and meta-analysis. ORL J Otorhinolaryngol Relat Spec 2015;77:70–86. Available at: https://www.ncbi.nlm.nih.gov/pubmed/25823449.

399. Edge SB, Byrd DR, Compton CC, et al., eds. AJCC Cancer Staging Manual (ed 7th). New York: Springer; 2010.

400. Amin M, Edge S, Greene F, et al. AJCC Cancer Staging Manual, 8th ed. New York: Springer; 2017.

401. Hosni A, Chiu K, Huang SH, et al. Non-operative management for oral cavity carcinoma: definitive radiation therapy as a potential alternative treatment approach. Radiother Oncol 2020;154:70–75. Available at: https://www.ncbi.nlm.nih.gov/pubmed/32861702.

402. Altuwaijri AA, Aldrees TM, Alessa MA. Prevalence of metastasis and involvement of level IV and V in oral squamous cell carcinoma: a systematic review. Cureus 2021;13:e20255. Available at: https://www.ncbi.nlm.nih.gov/pubmed/35018258.

403. van Lanschot CGF, Klazen YP, de Ridder MAJ, et al. Depth of invasion in early stage oral cavity squamous cell carcinoma: the optimal cut-off value for elective neck dissection. Oral Oncol 2020;111:104940. Available at: https://www.ncbi.nlm.nih.gov/pubmed/32769035.

404. Massey C, Dharmarajan A, Bannuru RR, Rebeiz E. Management of N0 neck in early oral squamous cell carcinoma: a systematic review and meta-analysis. Laryngoscope 2019;129:E284–E298. Available at: https://www.ncbi.nlm.nih.gov/pubmed/30570760.

405. Wermker K, Belok F, Schipmann S, et al. Prediction model for lymph node metastasis and recommendations for elective neck dissection in lip

Discussion update in progress

Version 1.2026 © 2025 National Comprehensive Cancer Network© (NCCN©), All rights reserved. NCCN Guidelines® and this illustration may not be reproduced in any form without the express written permission of NCCN.

PLEASE NOTE that use of this NCCN Content is governed by the End-User License Agreement, and you MAY NOT distribute this Content or use it with any artificial intelligence model or tool.
Printed by Galya Basol Kochav on 1/4/2026 9:40:35 AM. Copyright © 2026 National Comprehensive Cancer Network, Inc. All Rights Reserved.

cancer. J Craniomaxillofac Surg 2015;43:545–552. Available at: https://www.ncbi.nlm.nih.gov/pubmed/25753473.

406. Alkureishi LW, Ross GL, Shoaib T, et al. Sentinel node biopsy in head and neck squamous cell cancer: 5-year follow-up of a European multicenter trial. Ann Surg Oncol 2010;17:2459–2464. Available at: http://www.ncbi.nlm.nih.gov/pubmed/20552410.

407. Civantos FJ, Zitsch RP, Schuller DE, et al. Sentinel lymph node biopsy accurately stages the regional lymph nodes for T1-T2 oral squamous cell carcinomas: results of a prospective multi-institutional trial. J Clin Oncol 2010;28:1395–1400. Available at: http://www.ncbi.nlm.nih.gov/pubmed/20142602.

408. Govers TM, Hannink G, Merkx MA, et al. Sentinel node biopsy for squamous cell carcinoma of the oral cavity and oropharynx: a diagnostic meta-analysis. Oral Oncol 2013;49:726–732. Available at: http://www.ncbi.nlm.nih.gov/pubmed/23680537.

409. Samant S. Sentinel node biopsy as an alternative to elective neck dissection for staging of early oral carcinoma. Head Neck 2014;36:241–246. Available at: http://www.ncbi.nlm.nih.gov/pubmed/23729239.

410. Broglie MA, Haerle SK, Huber GF, et al. Occult metastases detected by sentinel node biopsy in patients with early oral and oropharyngeal squamous cell carcinomas: impact on survival. Head Neck 2013;35:660–666. Available at: http://www.ncbi.nlm.nih.gov/pubmed/22605675.

411. Kovacs AF, Stefenelli U, Seitz O, et al. Positive sentinel lymph nodes are a negative prognostic factor for survival in T1-2 oral/oropharyngeal cancer-a long-term study on 103 patients. Ann Surg Oncol 2009;16:233–239. Available at: http://www.ncbi.nlm.nih.gov/pubmed/18825461.

412. Pezier T, Nixon IJ, Gurney B, et al. Sentinel lymph node biopsy for T1/T2 oral cavity squamous cell carcinoma--a prospective case series. Ann Surg Oncol 2012;19:3528–3533. Available at: http://www.ncbi.nlm.nih.gov/pubmed/22411202.

413. Chone CT, Magalhes RS, Etchehebere E, et al. Predictive value of sentinel node biopsy in head and neck cancer. Acta Otolaryngol 2008;128:920–924. Available at: https://www.ncbi.nlm.nih.gov/pubmed/18607941.

414. Hokkam E, Gomaa A, Rifaat M, et al. The role of sentinel lymph-node biopsy in managing lip squamous cell carcinoma patients without clinical evidence of nodal metastasis. Gulf J Oncolog 2013;1:57–62. Available at: https://www.ncbi.nlm.nih.gov/pubmed/23996868.

415. Sollamo EM, Ilmonen SK, Virolainen MS, Suominen SH. Sentinel lymph node biopsy in cN0 squamous cell carcinoma of the lip: A retrospective study. Head Neck 2016;38 Suppl 1:E1375–1380. Available at: https://www.ncbi.nlm.nih.gov/pubmed/26514547.

416. Kim DH, Kim Y, Kim SW, Hwang SH. Usefulness of sentinel lymph node biopsy for oral cancer: a systematic review and meta-analysis. Laryngoscope 2021;131:E459–E465. Available at: https://www.ncbi.nlm.nih.gov/pubmed/32401367.

417. Garrel R, Poissonnet G, Moya Plana A, et al. Equivalence randomized trial to compare treatment on the basis of sentinel node biopsy versus neck node dissection in operable T1-T2N0 oral and oropharyngeal cancer. J Clin Oncol 2020;38:4010–4018. Available at: https://www.ncbi.nlm.nih.gov/pubmed/33052754.

418. Al-Moraissi EA, Marwan H, Elayah SA, et al. Sentinel lymph node biopsy versus elective neck dissection in management of the clinically negative (cN0) neck in patients with oral squamous cell carcinoma: A systematic review and meta-analysis. J Craniomaxillofac Surg 2024;52:141–150. Available at: https://www.ncbi.nlm.nih.gov/pubmed/38195297.

419. Agrawal A, Civantos FJ, Brumund KT, et al. [(99m)Tc]Tilmanocept accurately detects sentinel lymph nodes and predicts node pathology status in patients with oral squamous cell carcinoma of the head and neck: results of a phase III multi-institutional trial. Ann Surg Oncol 2015;22:3708–3715. Available at: https://www.ncbi.nlm.nih.gov/pubmed/25670018.

Discussion update in progress

Version 1.2026 © 2025 National Comprehensive Cancer Network© (NCCN©), All rights reserved. NCCN Guidelines® and this illustration may not be reproduced in any form without the express written permission of NCCN.

PLEASE NOTE that use of this NCCN Content is governed by the End-User License Agreement, and you MAY NOT distribute this Content or use it with any artificial intelligence model or tool.
Printed by Galya Basol Kochav on 1/4/2026 9:40:35 AM. Copyright © 2026 National Comprehensive Cancer Network, Inc. All Rights Reserved.

420. Marcinow AM, Hall N, Byrum E, et al. Use of a novel receptor-targeted (CD206) radiotracer, 99mTc-tilmanocept, and SPECT/CT for sentinel lymph node detection in oral cavity squamous cell carcinoma: initial institutional report in an ongoing phase 3 study. JAMA Otolaryngol Head Neck Surg 2013;139:895–902. Available at: https://www.ncbi.nlm.nih.gov/pubmed/24051744.

421. Nag S, Cano ER, Demanes DJ, et al. The American Brachytherapy Society recommendations for high-dose-rate brachytherapy for head-and-neck carcinoma. Int J Radiat Oncol Biol Phys 2001;50:1190–1198. Available at: http://www.ncbi.nlm.nih.gov/pubmed/11483328.

422. Mazeron JJ, Ardiet JM, Haie-Meder C, et al. GEC-ESTRO recommendations for brachytherapy for head and neck squamous cell carcinomas. Radiother Oncol 2009;91:150–156. Available at: http://www.ncbi.nlm.nih.gov/pubmed/19329209.

423. Branstetter BF, Blodgett TM, Zimmer LA, et al. Head and neck malignancy: is PET/CT more accurate than PET or CT alone? Radiology 2005;235:580–586. Available at: http://www.ncbi.nlm.nih.gov/pubmed/15858097.

424. Cantley RL, Gabrielli E, Montebelli F, et al. Ancillary studies in determining human papillomavirus status of squamous cell carcinoma of the oropharynx: a review. Patholog Res Int 2011;2011:138469. Available at: https://www.ncbi.nlm.nih.gov/pubmed/21772959.

425. Lang Kuhs KA, Wood CB, Wiggleton J, et al. Transcervical sonography and human papillomavirus 16 E6 antibodies are sensitive for the detection of oropharyngeal cancer. Cancer 2020;126:2658–2665. Available at: https://www.ncbi.nlm.nih.gov/pubmed/32129894.

426. Weinberger PM, Yu Z, Haffty BG, et al. Molecular classification identifies a subset of human papillomavirus--associated oropharyngeal cancers with favorable prognosis. J Clin Oncol 2006;24:736–747. Available at: https://www.ncbi.nlm.nih.gov/pubmed/16401683.

427. Prigge ES, Arbyn M, von Knebel Doeberitz M, Reuschenbach M. Diagnostic accuracy of p16INK4a immunohistochemistry in oropharyngeal squamous cell carcinomas: A systematic review and meta-analysis. Int J Cancer 2017;140:1186–1198. Available at: https://www.ncbi.nlm.nih.gov/pubmed/27859245.

428. Paolini F, Campo F, Iocca O, et al. It is time to improve the diagnostic workup of oropharyngeal cancer with circulating tumor HPV DNA: systematic review and meta-analysis. Head Neck 2023;45:2945–2954. Available at: https://www.ncbi.nlm.nih.gov/pubmed/37715656.

429. Ferrandino RM, Chen S, Kappauf C, et al. Performance of liquid biopsy for diagnosis and surveillance of human papillomavirus-associated oropharyngeal cancer. JAMA Otolaryngol Head Neck Surg 2023;149:971–977. Available at: https://www.ncbi.nlm.nih.gov/pubmed/37422913.

430. Berger BM, Hanna GJ, Posner MR, et al. Detection of occult recurrence using circulating tumor tissue modified viral HPV DNA among patients treated for HPV-driven oropharyngeal carcinoma. Clin Cancer Res 2022;28:4292–4301. Available at: https://www.ncbi.nlm.nih.gov/pubmed/35576437.

431. Singhi AD, Westra WH. Comparison of human papillomavirus in situ hybridization and p16 immunohistochemistry in the detection of human papillomavirus-associated head and neck cancer based on a prospective clinical experience. Cancer 2010;116:2166–2173. Available at: https://www.ncbi.nlm.nih.gov/pubmed/20186832.

432. Thavaraj S, Stokes A, Guerra E, et al. Evaluation of human papillomavirus testing for squamous cell carcinoma of the tonsil in clinical practice. J Clin Pathol 2011;64:308–312. Available at: https://www.ncbi.nlm.nih.gov/pubmed/21345874.

433. Begum S, Gillison ML, Nicol TL, Westra WH. Detection of human papillomavirus-16 in fine-needle aspirates to determine tumor origin in patients with metastatic squamous cell carcinoma of the head and neck. Clin Cancer Res 2007;13:1186–1191. Available at: http://www.ncbi.nlm.nih.gov/pubmed/17317828.

434. Lewis JS, Jr., Beadle B, Bishop JA, et al. Human papillomavirus testing in head and neck carcinomas: guideline from the College of

Discussion update in progress

Version 1.2026 © 2025 National Comprehensive Cancer Network© (NCCN©), All rights reserved. NCCN Guidelines® and this illustration may not be reproduced in any form without the express written permission of NCCN.

PLEASE NOTE that use of this NCCN Content is governed by the End-User License Agreement, and you MAY NOT distribute this Content or use it with any artificial intelligence model or tool.
Printed by Galya Basol Kochav on 1/4/2026 9:40:35 AM. Copyright © 2026 National Comprehensive Cancer Network, Inc. All Rights Reserved.

American Pathologists. Arch Pathol Lab Med 2018;142:559–597. Available at: https://www.ncbi.nlm.nih.gov/pubmed/29251996.

435. Prabhu RS, Magliocca KR, Hanasoge S, et al. Accuracy of computed tomography for predicting pathologic nodal extracapsular extension in patients with head-and-neck cancer undergoing initial surgical resection. Int J Radiat Oncol Biol Phys 2014;88:122–129. Available at: https://www.ncbi.nlm.nih.gov/pubmed/24331658.

436. O'Sullivan B, Huang SH, Su J, et al. Development and validation of a staging system for HPV-related oropharyngeal cancer by the International Collaboration on Oropharyngeal cancer Network for Staging (ICON-S): a multicentre cohort study. Lancet Oncol 2016;17:440–451. Available at: https://www.ncbi.nlm.nih.gov/pubmed/26936027.

437. Haughey BH, Sinha P, Kallogjeri D, et al. Pathology-based staging for HPV-positive squamous carcinoma of the oropharynx. Oral Oncol 2016;62:11–19. Available at: https://www.ncbi.nlm.nih.gov/pubmed/27865363.

438. Kaczmar JM, Tan KS, Heitjan DF, et al. HPV-related oropharyngeal cancer: Risk factors for treatment failure in patients managed with primary transoral robotic surgery. Head Neck 2016;38:59–65. Available at: https://www.ncbi.nlm.nih.gov/pubmed/25197014.

439. Dahlstrom KR, Garden AS, William WN, Jr., et al. Proposed staging system for patients with HPV-related oropharyngeal cancer based on nasopharyngeal cancer N categories. J Clin Oncol 2016;34:1848–1854. Available at: http://www.ncbi.nlm.nih.gov/pubmed/26884553.

440. Gillison ML. Human papillomavirus and oropharyngeal cancer stage. J Clin Oncol 2016;34:1833–1835. Available at: https://www.ncbi.nlm.nih.gov/pubmed/27114590.

441. Mehra R, Ang KK, Burtness B. Management of human papillomavirus-positive and human papillomavirus-negative head and neck cancer. Semin Radiat Oncol 2012;22:194–197. Available at: http://www.ncbi.nlm.nih.gov/pubmed/22687943.

442. Psyrri A, Rampias T, Vermorken JB. The current and future impact of human papillomavirus on treatment of squamous cell carcinoma of the head and neck. Ann Oncol 2014;25:2101–2115. Available at: http://www.ncbi.nlm.nih.gov/pubmed/25057165.

443. Mehanna H. Update on de-intensification and intensification studies in HPV. Recent Results Cancer Res 2017;206:251–256. Available at: https://www.ncbi.nlm.nih.gov/pubmed/27699545.

444. Mehanna H, Rischin D, Wong SJ, et al. De-escalation after DE-ESCALATE and RTOG 1016: a Head and Neck Cancer InterGroup Framework for future de-escalation studies. J Clin Oncol 2020;38:2552–2557. Available at: https://www.ncbi.nlm.nih.gov/pubmed/32496903.

445. Quon H, Forastiere AA. Controversies in treatment deintensification of human papillomavirus-associated oropharyngeal carcinomas: should we, how should we, and for whom? J Clin Oncol 2013;31:520–522. Available at: http://www.ncbi.nlm.nih.gov/pubmed/23295808.

446. Masterson L, Moualed D, Masood A, et al. De-escalation treatment protocols for human papillomavirus-associated oropharyngeal squamous cell carcinoma. Cochrane Database Syst Rev 2014;2:CD010271. Available at: http://www.ncbi.nlm.nih.gov/pubmed/24532092.

447. Kofler B, Laban S, Busch CJ, et al. New treatment strategies for HPV-positive head and neck cancer. Eur Arch Otorhinolaryngol 2014;271:1861–1867. Available at: https://www.ncbi.nlm.nih.gov/pubmed/23934317.

448. Lee NY, Sherman EJ, Schoder H, et al. Hypoxia-directed treatment of human papillomavirus-related oropharyngeal carcinoma. J Clin Oncol 2024;42:940–950. Available at: https://www.ncbi.nlm.nih.gov/pubmed/38241600.

449. Hinni ML, Zarka MA, Hoxworth JM. Margin mapping in transoral surgery for head and neck cancer. Laryngoscope 2013;123:1190–1198. Available at: http://www.ncbi.nlm.nih.gov/pubmed/23382042.

Discussion update in progress

Version 1.2026 © 2025 National Comprehensive Cancer Network© (NCCN©), All rights reserved. NCCN Guidelines® and this illustration may not be reproduced in any form without the express written permission of NCCN.

PLEASE NOTE that use of this NCCN Content is governed by the End-User License Agreement, and you MAY NOT distribute this Content or use it with any artificial intelligence model or tool.
Printed by Galya Basol Kochav on 1/4/2026 9:40:35 AM. Copyright © 2026 National Comprehensive Cancer Network, Inc. All Rights Reserved.

450. Cracchiolo JR, Baxi SS, Morris LG, et al. Increase in primary surgical treatment of T1 and T2 oropharyngeal squamous cell carcinoma and rates of adverse pathologic features: National Cancer Data Base. Cancer 2016;122:1523–1532. Available at: http://www.ncbi.nlm.nih.gov/pubmed/26970050.

451. Nichols AC, Theurer J, Prisman E, et al. Radiotherapy versus transoral robotic surgery and neck dissection for oropharyngeal squamous cell carcinoma (ORATOR): an open-label, phase 2, randomised trial. Lancet Oncol 2019;20:1349–1359. Available at: https://www.ncbi.nlm.nih.gov/pubmed/31416685.

452. Nichols AC, Theurer J, Prisman E, et al. Randomized trial of radiotherapy versus transoral robotic surgery for oropharyngeal squamous cell carcinoma: long-term results of the ORATOR trial. J Clin Oncol 2022;40:866–875. Available at: https://www.ncbi.nlm.nih.gov/pubmed/34995124.

453. Palma DA, Prisman E, Berthelet E, et al. Assessment of toxic effects and survival in treatment deescalation with radiotherapy vs transoral surgery for HPV-associated oropharyngeal squamous cell carcinoma: the ORATOR2 phase 2 randomized clinical trial. JAMA Oncol 2022;8:1–7. Available at: https://www.ncbi.nlm.nih.gov/pubmed/35482348.

454. Palma DA, Prisman E, Berthelet E, et al. Radiation vs. trans-oral surgery for treatment de-escalation in HPV-related oropharyngeal cancers: primary analysis of the ORATOR2 randomized trial. Eur J Cancer 2025;220:115343. Available at: https://www.ncbi.nlm.nih.gov/pubmed/40121836.

455. Marur S, Li S, Cmelak AJ, et al. E1308: phase II trial of induction chemotherapy followed by reduced-dose radiation and weekly cetuximab in patients with HPV-associated resectable squamous cell carcinoma of the oropharynx- ECOG-ACRIN Cancer Research Group. J Clin Oncol 2017;35:490–497. Available at: https://www.ncbi.nlm.nih.gov/pubmed/28029303.

456. Chen AM, Felix C, Wang PC, et al. Reduced-dose radiotherapy for human papillomavirus-associated squamous-cell carcinoma of the oropharynx: a single-arm, phase 2 study. Lancet Oncol 2017;18:803–811. Available at: https://www.ncbi.nlm.nih.gov/pubmed/28434660.

457. Chera BS, Amdur RJ, Tepper JE, et al. Mature results of a prospective study of deintensified chemoradiotherapy for low-risk human papillomavirus-associated oropharyngeal squamous cell carcinoma. Cancer 2018;124:2347–2354. Available at: https://www.ncbi.nlm.nih.gov/pubmed/29579339.

458. Chera BS, Amdur RJ, Green R, et al. Phase II trial of de-intensified chemoradiotherapy for human papillomavirus-associated oropharyngeal squamous cell carcinoma. J Clin Oncol 2019;37:2661–2669. Available at: https://www.ncbi.nlm.nih.gov/pubmed/31411949.

459. Ma DJ, Price KA, Moore EJ, et al. Phase II evaluation of aggressive dose de-escalation for adjuvant chemoradiotherapy in human papillomavirus-associated oropharynx squamous cell carcinoma. J Clin Oncol 2019;37:1909–1918. Available at: https://www.ncbi.nlm.nih.gov/pubmed/31163012.

460. Yom SS, Torres-Saavedra P, Caudell JJ, et al. Reduced-dose radiation therapy for HPV-associated oropharyngeal carcinoma (NRG Oncology HN002). J Clin Oncol 2021;39:956–965. Available at: https://www.ncbi.nlm.nih.gov/pubmed/33507809.

461. Yom SS, Harris J, Caudell JJ, et al. Interim futility results of NRG-HN005, a randomized, phase II/III non-inferiority trial for non-smoking p16+ oropharyngeal cancer patients. International Journal of Radiation Oncology, Biology, Physics 2024;120:S2–S3. Available at: https://doi.org/10.1016/j.ijrobp.2024.08.014.

462. Ferris RL, Flamand Y, Weinstein GS, et al. Phase II randomized trial of transoral surgery and low-dose intensity modulated radiation therapy in resectable p16+ locally advanced oropharynx cancer: an ECOG-ACRIN Cancer Research Group Trial (E3311). J Clin Oncol 2022;40:138–149. Available at: https://www.ncbi.nlm.nih.gov/pubmed/34699271.

463. Iyer NG, Dogan S, Palmer F, et al. Detailed analysis of clinicopathologic factors demonstrate distinct difference in outcome and

Discussion update in progress

Version 1.2026 © 2025 National Comprehensive Cancer Network© (NCCN©), All rights reserved. NCCN Guidelines® and this illustration may not be reproduced in any form without the express written permission of NCCN.

PLEASE NOTE that use of this NCCN Content is governed by the End-User License Agreement, and you MAY NOT distribute this Content or use it with any artificial intelligence model or tool.
Printed by Galya Basol Kochav on 1/4/2026 9:40:35 AM. Copyright © 2026 National Comprehensive Cancer Network, Inc. All Rights Reserved.

prognostic factors between surgically treated HPV-positive and negative oropharyngeal cancer. Ann Surg Oncol 2015;22:4411–4421. Available at: https://www.ncbi.nlm.nih.gov/pubmed/25801358.

464. Maxwell JH, Ferris RL, Gooding W, et al. Extracapsular spread in head and neck carcinoma: impact of site and human papillomavirus status. Cancer 2013;119:3302–3308. Available at: https://www.ncbi.nlm.nih.gov/pubmed/23797868.

465. Sinha P, Kallogjeri D, Gay H, et al. High metastatic node number, not extracapsular spread or N-classification is a node-related prognosticator in transorally-resected, neck-dissected p16-positive oropharynx cancer. Oral Oncol 2015;51:514–520. Available at: https://www.ncbi.nlm.nih.gov/pubmed/25771076.

466. An Y, Park HS, Kelly JR, et al. The prognostic value of extranodal extension in human papillomavirus-associated oropharyngeal squamous cell carcinoma. Cancer 2017;123:2762–2772. Available at: https://www.ncbi.nlm.nih.gov/pubmed/28323338.

467. Haughey BH, Sinha P. Prognostic factors and survival unique to surgically treated p16+ oropharyngeal cancer. Laryngoscope 2012;122 Suppl 2:S13–33. Available at: https://www.ncbi.nlm.nih.gov/pubmed/22926949.

468. Freitag J, Wald T, Kuhnt T, et al. Extracapsular extension of neck nodes and absence of human papillomavirus 16-DNA are predictors of impaired survival in p16-positive oropharyngeal squamous cell carcinoma. Cancer 2020;126:1856–1872. Available at: https://www.ncbi.nlm.nih.gov/pubmed/32032442.

469. Zumsteg ZS, Kim S, David JM, et al. Impact of concomitant chemoradiation on survival for patients with T1-2N1 head and neck cancer. Cancer 2017;123:1555–1565. Available at: https://www.ncbi.nlm.nih.gov/pubmed/28001302.

470. Yoshida EJ, Luu M, Mallen-St Clair J, et al. Stage I HPV-positive oropharyngeal cancer: should all patients receive similar treatments? Cancer 2020;126:58–66. Available at: https://www.ncbi.nlm.nih.gov/pubmed/31536144.

471. Haughey BH, Hinni ML, Salassa JR, et al. Transoral laser microsurgery as primary treatment for advanced-stage oropharyngeal cancer: a United States multicenter study. Head Neck 2011;33:1683–1694. Available at: http://www.ncbi.nlm.nih.gov/pubmed/21284056.

472. Garden AS, Kies MS, Morrison WH, et al. Outcomes and patterns of care of patients with locally advanced oropharyngeal carcinoma treated in the early 21st century. Radiat Oncol 2013;8:21. Available at: http://www.ncbi.nlm.nih.gov/pubmed/23360540.

473. Al-Mamgani A, Van Rooij P, Tans L, et al. Toxicity and outcome of intensity-modulated radiotherapy versus 3-dimensional conformal radiotherapy for oropharyngeal cancer: a matched-pair analysis. Technol Cancer Res Treat 2013;12:123–130. Available at: http://www.ncbi.nlm.nih.gov/pubmed/23098281.

474. Deschuymer S, Nevens D, Duprez F, et al. Randomized clinical trial on reduction of radiotherapy dose to the elective neck in head and neck squamous cell carcinoma; update of the long-term tumor outcome. Radiother Oncol 2020;143:24–29. Available at: https://www.ncbi.nlm.nih.gov/pubmed/32044165.

475. Hegde JV, Shaverdian N, Daly ME, et al. Patient-reported quality-of-life outcomes after de-escalated chemoradiation for human papillomavirus-positive oropharyngeal carcinoma: findings from a phase 2 trial. Cancer 2018;124:521–529. Available at: https://www.ncbi.nlm.nih.gov/pubmed/29044458.

476. Lefebvre JL, Rolland F, Tesselaar M, et al. Phase 3 randomized trial on larynx preservation comparing sequential vs alternating chemotherapy and radiotherapy. J Natl Cancer Inst 2009;101:142–152. Available at: http://www.ncbi.nlm.nih.gov/pubmed/19176454.

477. Henriques De Figueiredo B, Fortpied C, Menis J, et al. Long-term update of the 24954 EORTC phase III trial on larynx preservation. Eur J

Discussion update in progress

Version 1.2026 © 2025 National Comprehensive Cancer Network© (NCCN©), All rights reserved. NCCN Guidelines® and this illustration may not be reproduced in any form without the express written permission of NCCN.

PLEASE NOTE that use of this NCCN Content is governed by the End-User License Agreement, and you MAY NOT distribute this Content or use it with any artificial intelligence model or tool.
Printed by Galya Basol Kochav on 1/4/2026 9:40:35 AM. Copyright © 2026 National Comprehensive Cancer Network, Inc. All Rights Reserved.

Cancer 2016;65:109–112. Available at: https://www.ncbi.nlm.nih.gov/pubmed/27494036/.

478. Ferlay J, Ervik M, Lam F, et al. Global Cancer Observatory: Cancer Today. International Agency for Research on Cancer 2024. Available at: https://gco.iarc.who.int/media/globocan/factsheets/cancers/4-nasopharynx-fact-sheet.pdf.

479. Chen W, Zheng R, Baade PD, et al. Cancer statistics in China, 2015. CA Cancer J Clin 2016;66:115–132. Available at: https://www.ncbi.nlm.nih.gov/pubmed/26808342.

480. Chua MLK, Wee JTS, Hui EP, Chan ATC. Nasopharyngeal carcinoma. Lancet 2016;387:1012–1024. Available at: https://www.ncbi.nlm.nih.gov/pubmed/26321262.

481. Pathmanathan R, Prasad U, Sadler R, et al. Clonal proliferations of cells infected with Epstein-Barr virus in preinvasive lesions related to nasopharyngeal carcinoma. N Engl J Med 1995;333:693–698. Available at: https://www.ncbi.nlm.nih.gov/pubmed/7637746.

482. Chen YP, Chan ATC, Le QT, et al. Nasopharyngeal carcinoma. Lancet 2019;394:64–80. Available at: https://www.ncbi.nlm.nih.gov/pubmed/31178151.

483. Lee AW, Ma BB, Ng WT, Chan AT. Management of nasopharyngeal carcinoma: current practice and future perspective. J Clin Oncol 2015;33:3356–3364. Available at: https://www.ncbi.nlm.nih.gov/pubmed/26351355.

484. Dogan S, Hedberg ML, Ferris RL, et al. Human papillomavirus and Epstein-Barr virus in nasopharyngeal carcinoma in a low-incidence population. Head Neck 2014;36:511–516. Available at: https://www.ncbi.nlm.nih.gov/pubmed/23780921.

485. Robinson M, Suh YE, Paleri V, et al. Oncogenic human papillomavirus-associated nasopharyngeal carcinoma: an observational study of correlation with ethnicity, histological subtype and outcome in a UK population. Infect Agent Cancer 2013;8:30. Available at: https://www.ncbi.nlm.nih.gov/pubmed/23938045.

486. Stenmark MH, McHugh JB, Schipper M, et al. Nonendemic HPV-positive nasopharyngeal carcinoma: association with poor prognosis. Int J Radiat Oncol Biol Phys 2014;88:580–588. Available at: https://www.ncbi.nlm.nih.gov/pubmed/24521676.

487. Lewis JS, Jr., Chernock RD. Human papillomavirus and Epstein Barr virus in head and neck carcinomas: suggestions for the new WHO classification. Head Neck Pathol 2014;8:50–58. Available at: https://www.ncbi.nlm.nih.gov/pubmed/24595417.

488. Banko AV, Lazarevic IB, Folic MM, et al. Characterization of the variability of Epstein-Barr virus genes in nasopharyngeal biopsies: potential predictors for carcinoma progression. PLoS One 2016;11:e0153498. Available at: https://www.ncbi.nlm.nih.gov/pubmed/27071030.

489. Gulley ML, Tang W. Laboratory assays for Epstein-Barr virus-related disease. J Mol Diagn 2008;10:279–292. Available at: https://www.ncbi.nlm.nih.gov/pubmed/18556771.

490. Zeng Z, Fan S, Zhang X, et al. Epstein-Barr virus-encoded small RNA 1 (EBER-1) could predict good prognosis in nasopharyngeal carcinoma. Clin Transl Oncol 2016;18:206–211. Available at: https://www.ncbi.nlm.nih.gov/pubmed/26260913.

491. Jeon YK, Lee BY, Kim JE, et al. Molecular characterization of Epstein-Barr virus and oncoprotein expression in nasopharyngeal carcinoma in Korea. Head Neck 2004;26:573–583. Available at: https://www.ncbi.nlm.nih.gov/pubmed/15229899.

492. Gulley ML. Molecular diagnosis of Epstein-Barr virus-related diseases. J Mol Diagn 2001;3:1–10. Available at: https://www.ncbi.nlm.nih.gov/pubmed/11227065.

493. Lam WKJ, King AD, Miller JA, et al. Recommendations for Epstein-Barr virus-based screening for nasopharyngeal cancer in high- and

Discussion update in progress

Version 1.2026 © 2025 National Comprehensive Cancer Network© (NCCN©), All rights reserved. NCCN Guidelines® and this illustration may not be reproduced in any form without the express written permission of NCCN.

PLEASE NOTE that use of this NCCN Content is governed by the End-User License Agreement, and you MAY NOT distribute this Content or use it with any artificial intelligence model or tool.
Printed by Galya Basol Kochav on 1/4/2026 9:40:35 AM. Copyright © 2026 National Comprehensive Cancer Network, Inc. All Rights Reserved.

intermediate-risk regions. J Natl Cancer Inst 2023;115:355–364. Available at: https://www.ncbi.nlm.nih.gov/pubmed/36723440.

494. Fung SY, Lam JW, Chan KC. Clinical utility of circulating Epstein-Barr virus DNA analysis for the management of nasopharyngeal carcinoma. Chin Clin Oncol 2016;5:18. Available at: https://www.ncbi.nlm.nih.gov/pubmed/27121878.

495. Alami IE, Gihbid A, Charoute H, et al. Prognostic value of Epstein-Barr virus DNA load in nasopharyngeal carcinoma: a meta-analysis. Pan Afr Med J 2022;41:6. Available at: https://www.ncbi.nlm.nih.gov/pubmed/35145598.

496. Chan DCT, Lam WKJ, Hui EP, et al. Improved risk stratification of nasopharyngeal cancer by targeted sequencing of Epstein-Barr virus DNA in post-treatment plasma. Ann Oncol 2022;33:794–803. Available at: https://www.ncbi.nlm.nih.gov/pubmed/35491007.

497. Lv J, Wu C, Li J, et al. Improving on-treatment risk stratification of cancer patients with refined response classification and integration of circulating tumor DNA kinetics. BMC Med 2022;20:268. Available at: https://www.ncbi.nlm.nih.gov/pubmed/35996151.

498. Zong J, Ji P, Lin C, et al. Plasma Epstein-Barr viral DNA load after completion of two cycles of induction chemotherapy predicts outcomes for patients with advanced-stage nasopharyngeal carcinoma. Oral Oncol 2022;131:105972. Available at: https://www.ncbi.nlm.nih.gov/pubmed/35728415.

499. Lin JC, Wang WY, Chen KY, et al. Quantification of plasma Epstein-Barr virus DNA in patients with advanced nasopharyngeal carcinoma. N Engl J Med 2004;350:2461–2470. Available at: https://www.ncbi.nlm.nih.gov/pubmed/15190138.

500. Lin JC, Wang WY, Liang WM, et al. Long-term prognostic effects of plasma epstein-barr virus DNA by minor groove binder-probe real-time quantitative PCR on nasopharyngeal carcinoma patients receiving concurrent chemoradiotherapy. Int J Radiat Oncol Biol Phys 2007;68:1342–1348. Available at: https://www.ncbi.nlm.nih.gov/pubmed/17449194.

501. Prayongrat A, Chakkabat C, Kannarunimit D, et al. Prevalence and significance of plasma Epstein-Barr Virus DNA level in nasopharyngeal carcinoma. J Radiat Res 2017;58:509–516. Available at: https://www.ncbi.nlm.nih.gov/pubmed/28204596.

502. Jin YN, Yao JJ, Zhang F, et al. Is pretreatment Epstein-Barr virus DNA still associated with 6-year survival outcomes in locoregionally advanced nasopharyngeal carcinoma? J Cancer 2017;8:976–982. Available at: https://www.ncbi.nlm.nih.gov/pubmed/28529609.

503. Leung SF, Chan AT, Zee B, et al. Pretherapy quantitative measurement of circulating Epstein-Barr virus DNA is predictive of posttherapy distant failure in patients with early-stage nasopharyngeal carcinoma of undifferentiated type. Cancer 2003;98:288–291. Available at: https://www.ncbi.nlm.nih.gov/pubmed/12872347.

504. Leung SF, Chan KC, Ma BB, et al. Plasma Epstein-Barr viral DNA load at midpoint of radiotherapy course predicts outcome in advanced-stage nasopharyngeal carcinoma. Ann Oncol 2014;25:1204–1208. Available at: https://www.ncbi.nlm.nih.gov/pubmed/24638904.

505. Zhang W, Chen Y, Chen L, et al. The clinical utility of plasma Epstein-Barr virus DNA assays in nasopharyngeal carcinoma: the dawn of a new era?: a systematic review and meta-analysis of 7836 cases. Medicine (Baltimore) 2015;94:e845. Available at: https://www.ncbi.nlm.nih.gov/pubmed/25997061.

506. Liu LT, Tang LQ, Chen QY, et al. The prognostic value of plasma Epstein-Barr viral DNA and tumor response to neoadjuvant chemotherapy in advanced-stage nasopharyngeal carcinoma. Int J Radiat Oncol Biol Phys 2015;93:862–869. Available at: https://www.ncbi.nlm.nih.gov/pubmed/26530755.

507. Chan ATC, Hui EP, Ngan RKC, et al. Analysis of plasma Epstein-Barr virus DNA in nasopharyngeal cancer after chemoradiation to identify high-risk patients for adjuvant chemotherapy: a randomized controlled

Discussion update in progress

Version 1.2026 © 2025 National Comprehensive Cancer Network© (NCCN©), All rights reserved. NCCN Guidelines® and this illustration may not be reproduced in any form without the express written permission of NCCN.

PLEASE NOTE that use of this NCCN Content is governed by the End-User License Agreement, and you MAY NOT distribute this Content or use it with any artificial intelligence model or tool.
Printed by Galya Basol Kochav on 1/4/2026 9:40:35 AM. Copyright © 2026 National Comprehensive Cancer Network, Inc. All Rights Reserved.

trial. J Clin Oncol 2018:JCO2018777847. Available at: https://www.ncbi.nlm.nih.gov/pubmed/29989858.

508. Liang Y, Li J, Li Q, et al. Plasma protein-based signature predicts distant metastasis and induction chemotherapy benefit in nasopharyngeal carcinoma. Theranostics 2020;10:9767–9778. Available at: https://www.ncbi.nlm.nih.gov/pubmed/32863958.

509. Wang WY, Twu CW, Chen HH, et al. Plasma EBV DNA clearance rate as a novel prognostic marker for metastatic/recurrent nasopharyngeal carcinoma. Clin Cancer Res 2010;16:1016–1024. Available at: https://www.ncbi.nlm.nih.gov/pubmed/20103659.

510. Xu JY, Wei XL, Ren C, et al. Association of plasma Epstein-Barr virus DNA with outcomes for patients with recurrent or metastatic nasopharyngeal carcinoma receiving anti-programmed cell death 1 immunotherapy. JAMA Netw Open 2022;5:e220587. Available at: https://www.ncbi.nlm.nih.gov/pubmed/35230439.

511. al-Sarraf M, Pajak TF, Cooper JS, et al. Chemo-radiotherapy in patients with locally advanced nasopharyngeal carcinoma: a radiation therapy oncology group study. J Clin Oncol 1990;8:1342–1351. Available at: https://www.ncbi.nlm.nih.gov/pubmed/2199621.

512. Chan AT, Leung SF, Ngan RK, et al. Overall survival after concurrent cisplatin-radiotherapy compared with radiotherapy alone in locoregionally advanced nasopharyngeal carcinoma. J Natl Cancer Inst 2005;97:536–539. Available at: http://www.ncbi.nlm.nih.gov/pubmed/15812080.

513. Lin JC, Jan JS, Hsu CY, et al. Phase III study of concurrent chemoradiotherapy versus radiotherapy alone for advanced nasopharyngeal carcinoma: positive effect on overall and progression-free survival. J Clin Oncol 2003;21:631–637. Available at: https://www.ncbi.nlm.nih.gov/pubmed/12586799.

514. Wee J, Tan EH, Tai BC, et al. Randomized trial of radiotherapy versus concurrent chemoradiotherapy followed by adjuvant chemotherapy in patients with American Joint Committee on Cancer/International Union against cancer stage III and IV nasopharyngeal cancer of the endemic variety. J Clin Oncol 2005;23:6730–6738. Available at: http://www.ncbi.nlm.nih.gov/pubmed/16170180.

515. Lee AWM, Tung SY, Ng WT, et al. A multicenter, phase 3, randomized trial of concurrent chemoradiotherapy plus adjuvant chemotherapy versus radiotherapy alone in patients with regionally advanced nasopharyngeal carcinoma: 10-year outcomes for efficacy and toxicity. Cancer 2017;123:4147–4157. Available at: https://www.ncbi.nlm.nih.gov/pubmed/28662313.

516. Chen L, Hu CS, Chen XZ, et al. Concurrent chemoradiotherapy plus adjuvant chemotherapy versus concurrent chemoradiotherapy alone in patients with locoregionally advanced nasopharyngeal carcinoma: a phase 3 multicentre randomised controlled trial. Lancet Oncol 2012;13:163–171. Available at: http://www.ncbi.nlm.nih.gov/pubmed/22154591.

517. Wang S, Li S, Shen L. Combined chemoradiation vs radiation therapy alone in stage-II nasopharyngeal carcinoma: A meta-analysis of the published literature. Curr Probl Cancer 2018;42:302–318. Available at: https://www.ncbi.nlm.nih.gov/pubmed/29759802.

518. Liu F, Jin T, Liu L, et al. The role of concurrent chemotherapy for stage II nasopharyngeal carcinoma in the intensity-modulated radiotherapy era: a systematic review and meta-analysis. PLoS One 2018;13:e0194733. Available at: https://www.ncbi.nlm.nih.gov/pubmed/29566078.

519. Xu C, Zhang LH, Chen YP, et al. Chemoradiotherapy versus radiotherapy alone in stage II nasopharyngeal carcinoma: a systemic review and meta-analysis of 2138 patients. J Cancer 2017;8:287–297. Available at: https://www.ncbi.nlm.nih.gov/pubmed/28243333.

520. Huang X, Chen X, Zhao C, et al. Adding concurrent chemotherapy to intensity-modulated radiotherapy does not improve treatment outcomes for stage II nasopharyngeal carcinoma: a phase 2 multicenter clinical trial. Front Oncol 2020;10:1314. Available at: https://www.ncbi.nlm.nih.gov/pubmed/32850414.

Discussion update in progress

Version 1.2026 © 2025 National Comprehensive Cancer Network© (NCCN©), All rights reserved. NCCN Guidelines® and this illustration may not be reproduced in any form without the express written permission of NCCN.

PLEASE NOTE that use of this NCCN Content is governed by the End-User License Agreement, and you MAY NOT distribute this Content or use it with any artificial intelligence model or tool.
Printed by Galya Basol Kochav on 1/4/2026 9:40:35 AM. Copyright © 2026 National Comprehensive Cancer Network, Inc. All Rights Reserved.

521. Tang LL, Guo R, Zhang N, et al. Effect of radiotherapy alone vs radiotherapy with concurrent chemoradiotherapy on survival without disease relapse in patients with low-risk nasopharyngeal carcinoma: a randomized clinical trial. JAMA 2022;328:728–736. Available at: https://www.ncbi.nlm.nih.gov/pubmed/35997729.

522. Blanchard P, Lee A, Marguet S, et al. Chemotherapy and radiotherapy in nasopharyngeal carcinoma: an update of the MAC-NPC meta-analysis. Lancet Oncol 2015;16:645–655. Available at: https://www.ncbi.nlm.nih.gov/pubmed/25957714.

523. Yang Q, Cao SM, Guo L, et al. Induction chemotherapy followed by concurrent chemoradiotherapy versus concurrent chemoradiotherapy alone in locoregionally advanced nasopharyngeal carcinoma: long-term results of a phase III multicentre randomised controlled trial. Eur J Cancer 2019;119:87–96. Available at: https://www.ncbi.nlm.nih.gov/pubmed/31425966.

524. Zhang Y, Chen L, Hu GQ, et al. Gemcitabine and cisplatin induction chemotherapy in nasopharyngeal carcinoma. N Engl J Med 2019;381:1124–1135. Available at: https://www.ncbi.nlm.nih.gov/pubmed/31150573.

525. Ribassin-Majed L, Marguet S, Lee AWM, et al. What is the best treatment of locally advanced nasopharyngeal carcinoma? An individual patient data network meta-analysis. J Clin Oncol 2017;35:498–505. Available at: https://www.ncbi.nlm.nih.gov/pubmed/27918720.

526. Chen YP, Tang LL, Yang Q, et al. Induction chemotherapy plus concurrent chemoradiotherapy in endemic nasopharyngeal carcinoma: individual patient data pooled analysis of four randomized trials. Clin Cancer Res 2018;24:1824–1833. Available at: https://www.ncbi.nlm.nih.gov/pubmed/29431618.

527. Tan TH, Soon YY, Cheo T, et al. Induction chemotherapy for locally advanced nasopharyngeal carcinoma treated with concurrent chemoradiation: A systematic review and meta-analysis. Radiother Oncol 2018;129:10–17. Available at: https://www.ncbi.nlm.nih.gov/pubmed/29555182.

528. Wang P, Zhang M, Ke C, Cai C. The efficacy and toxicity of induction chemotherapy plus concurrent chemoradiotherapy in locoregionally advanced nasopharyngeal carcinoma: a meta-analysis of randomized controlled trials. Medicine (Baltimore) 2020;99:e19360. Available at: https://www.ncbi.nlm.nih.gov/pubmed/32150078.

529. Chen YP, Ismaila N, Chua MLK, et al. Chemotherapy in combination with radiotherapy for definitive-intent treatment of stage II-IVA nasopharyngeal carcinoma: CSCO and ASCO Guideline. J Clin Oncol 2021;39:840–859. Available at: https://www.ncbi.nlm.nih.gov/pubmed/33405943.

530. Petit C, Lee A, Ma J, et al. Role of chemotherapy in patients with nasopharynx carcinoma treated with radiotherapy (MAC-NPC): an updated individual patient data network meta-analysis. Lancet Oncol 2023;24:611–623. Available at: https://www.ncbi.nlm.nih.gov/pubmed/37269842.

531. You R, Cao YS, Huang PY, et al. The changing therapeutic role of chemo-radiotherapy for loco-regionally advanced nasopharyngeal carcinoma from two/three-dimensional radiotherapy to intensity-modulated radiotherapy: a network meta-analysis. Theranostics 2017;7:4825–4835. Available at: https://www.ncbi.nlm.nih.gov/pubmed/29187906.

532. Lee AWM, Ngan RKC, Ng WT, et al. NPC-0501 trial on the value of changing chemoradiotherapy sequence, replacing 5-fluorouracil with capecitabine, and altering fractionation for patients with advanced nasopharyngeal carcinoma. Cancer 2020;126:3674–3688. Available at: https://www.ncbi.nlm.nih.gov/pubmed/32497261.

533. Dai J, Zhang B, Su Y, et al. Induction chemotherapy followed by radiotherapy vs chemoradiotherapy in nasopharyngeal carcinoma: a randomized clinical trial. JAMA Oncol 2024;10:456–463. Available at: https://www.ncbi.nlm.nih.gov/pubmed/38329737.

534. Miao J, Wang L, Tan SH, et al. Adjuvant capecitabine following concurrent chemoradiotherapy in locoregionally advanced nasopharyngeal carcinoma: a randomized clinical trial. JAMA Oncol 2022;8:1776–1785. Available at: https://www.ncbi.nlm.nih.gov/pubmed/36227615.

Discussion update in progress

Version 1.2026 © 2025 National Comprehensive Cancer Network© (NCCN©), All rights reserved. NCCN Guidelines® and this illustration may not be reproduced in any form without the express written permission of NCCN.

PLEASE NOTE that use of this NCCN Content is governed by the End-User License Agreement, and you MAY NOT distribute this Content or use it with any artificial intelligence model or tool.
Printed by Galya Basol Kochav on 1/4/2026 9:40:35 AM. Copyright © 2026 National Comprehensive Cancer Network, Inc. All Rights Reserved.

535. Liu GY, Li WZ, Wang DS, et al. Effect of capecitabine maintenance therapy plus best supportive care vs best supportive care alone on progression-free survival among patients with newly diagnosed metastatic nasopharyngeal carcinoma who had received induction chemotherapy: a phase 3 randomized clinical trial. JAMA Oncol 2022;8:553–561. Available at: https://www.ncbi.nlm.nih.gov/pubmed/35175316.

536. Chen YP, Liu X, Zhou Q, et al. Metronomic capecitabine as adjuvant therapy in locoregionally advanced nasopharyngeal carcinoma: a multicentre, open-label, parallel-group, randomised, controlled, phase 3 trial. Lancet 2021;398:303–313. Available at: https://www.ncbi.nlm.nih.gov/pubmed/34111416.

537. Yang Y, Pan J, Wang H, et al. Tislelizumab plus chemotherapy as first-line treatment for recurrent or metastatic nasopharyngeal cancer: a multicenter phase 3 trial (RATIONALE-309). Cancer Cell 2023;41:1061–1072 e1064. Available at: https://www.ncbi.nlm.nih.gov/pubmed/37207654.

538. Liu X, Zhang Y, Yang KY, et al. Induction-concurrent chemoradiotherapy with or without sintilimab in patients with locoregionally advanced nasopharyngeal carcinoma in China (CONTINUUM): a multicentre, open-label, parallel-group, randomised, controlled, phase 3 trial. Lancet 2024;403:2720–2731. Available at: https://www.ncbi.nlm.nih.gov/pubmed/38824941.

539. Tang LL, Chen YP, Mao YP, et al. Validation of the 8th edition of the UICC/AJCC staging system for nasopharyngeal carcinoma from endemic areas in the intensity-modulated radiotherapy era. J Natl Compr Canc Netw 2017;15:913–919. Available at: https://www.ncbi.nlm.nih.gov/pubmed/28687579.

540. Guo R, Tang LL, Mao YP, et al. Proposed modifications and incorporation of plasma Epstein-Barr virus DNA improve the TNM staging system for Epstein-Barr virus-related nasopharyngeal carcinoma. Cancer 2019;125:79–89. Available at: https://www.ncbi.nlm.nih.gov/pubmed/30351466.

541. Sun Y, Li WF, Chen NY, et al. Induction chemotherapy plus concurrent chemoradiotherapy versus concurrent chemoradiotherapy alone in locoregionally advanced nasopharyngeal carcinoma: a phase 3, multicentre, randomised controlled trial. Lancet Oncol 2016;17:1509–1520. Available at: https://www.ncbi.nlm.nih.gov/pubmed/27686945.

542. Zhang Y, Chen L, Hu GQ, et al. Final overall survival analysis of gemcitabine and cisplatin induction chemotherapy in nasopharyngeal carcinoma: a multicenter, randomized phase III trial. J Clin Oncol 2022;40:2420–2425. Available at: https://www.ncbi.nlm.nih.gov/pubmed/35709465.

543. Dechaphunkul T, Pruegsanusak K, Sangthawan D, Sunpaweravong P. Concurrent chemoradiotherapy with carboplatin followed by carboplatin and 5-fluorouracil in locally advanced nasopharyngeal carcinoma. Head Neck Oncol 2011;3:30. Available at: http://www.ncbi.nlm.nih.gov/pubmed/21639934.

544. Songthong A, Chakkabat C, Kannarunimit D, Lertbutsayanukul C. Efficacy of intensity-modulated radiotherapy with concurrent carboplatin in nasopharyngeal carcinoma. Radiol Oncol 2015;49:155–162. Available at: https://www.ncbi.nlm.nih.gov/pubmed/26029027.

545. Chitapanarux I, Lorvidhaya V, Kamnerdsupaphon P, et al. Chemoradiation comparing cisplatin versus carboplatin in locally advanced nasopharyngeal cancer: randomised, non-inferiority, open trial. Eur J Cancer 2007;43:1399–1406. Available at: http://www.ncbi.nlm.nih.gov/pubmed/17467265.

546. Rusthoven CG, Lanning RM, Jones BL, et al. Metastatic nasopharyngeal carcinoma: Patterns of care and survival for patients receiving chemotherapy with and without local radiotherapy. Radiother Oncol 2017;124:139–146. Available at: https://www.ncbi.nlm.nih.gov/pubmed/28433411.

547. Chua GWY, Chua ET. Long-term disease-free survival of a patient with oligometastatic nasopharyngeal carcinoma treated with radiotherapy alone. Case Rep Oncol 2018;11:392–398. Available at: https://www.ncbi.nlm.nih.gov/pubmed/30022942.

Discussion update in progress

Version 1.2026 © 2025 National Comprehensive Cancer Network© (NCCN©), All rights reserved. NCCN Guidelines® and this illustration may not be reproduced in any form without the express written permission of NCCN.

PLEASE NOTE that use of this NCCN Content is governed by the End-User License Agreement, and you MAY NOT distribute this Content or use it with any artificial intelligence model or tool.
Printed by Galya Basol Kochav on 1/4/2026 9:40:35 AM. Copyright © 2026 National Comprehensive Cancer Network, Inc. All Rights Reserved.

548. Ma J, Wen ZS, Lin P, et al. The results and prognosis of different treatment modalities for solitary metastatic lung tumor from nasopharyngeal carcinoma: a retrospective study of 105 cases. Chin J Cancer 2010;29:787–795. Available at: https://www.ncbi.nlm.nih.gov/pubmed/20800020.

549. You R, Liu YP, Huang PY, et al. Efficacy and safety of locoregional radiotherapy with chemotherapy vs chemotherapy alone in de novo metastatic nasopharyngeal carcinoma: a multicenter phase 3 randomized clinical trial. JAMA Oncol 2020;6:1345–1352. Available at: https://www.ncbi.nlm.nih.gov/pubmed/32701129.

550. Zhang L, Huang Y, Hong S, et al. Gemcitabine plus cisplatin versus fluorouracil plus cisplatin in recurrent or metastatic nasopharyngeal carcinoma: a multicentre, randomised, open-label, phase 3 trial. Lancet 2016;388:1883–1892. Available at: https://www.ncbi.nlm.nih.gov/pubmed/27567279.

551. Hong S, Zhang Y, Yu G, et al. Gemcitabine plus cisplatin versus fluorouracil plus cisplatin as first-line therapy for recurrent or metastatic nasopharyngeal carcinoma: final overall survival analysis of GEM20110714 phase III study. J Clin Oncol 2021;39:3273–3282. Available at: https://www.ncbi.nlm.nih.gov/pubmed/34379443.

552. Samlowski WE, Moon J, Kuebler JP, et al. Evaluation of the combination of docetaxel/carboplatin in patients with metastatic or recurrent squamous cell carcinoma of the head and neck (SCCHN): a Southwest Oncology Group Phase II study. Cancer Invest 2007;25:182–188. Available at: http://www.ncbi.nlm.nih.gov/pubmed/17530488.

553. Gibson MK, Li Y, Murphy B, et al. Randomized phase III evaluation of cisplatin plus fluorouracil versus cisplatin plus paclitaxel in advanced head and neck cancer (E1395): an intergroup trial of the Eastern Cooperative Oncology Group. J Clin Oncol 2005;23:3562–3567. Available at: http://www.ncbi.nlm.nih.gov/pubmed/15908667.

554. Forastiere AA, Metch B, Schuller DE, et al. Randomized comparison of cisplatin plus fluorouracil and carboplatin plus fluorouracil versus methotrexate in advanced squamous-cell carcinoma of the head and neck: a Southwest Oncology Group study. J Clin Oncol 1992;10:1245–1251. Available at: http://www.ncbi.nlm.nih.gov/pubmed/1634913.

555. Chan ATC, Hsu M-M, Goh BC, et al. Multicenter, phase II study of cetuximab in combination with carboplatin in patients with recurrent or metastatic nasopharyngeal carcinoma. J Clin Oncol 2005;23:3568–3576. Available at: http://www.ncbi.nlm.nih.gov/pubmed/15809453.

556. Jin Y, Cai XY, Shi YX, et al. Comparison of five cisplatin-based regimens frequently used as the first-line protocols in metastatic nasopharyngeal carcinoma. J Cancer Res Clin Oncol 2012;138:1717–1725. Available at: http://www.ncbi.nlm.nih.gov/pubmed/22684794.

557. Jacobs C, Lyman G, Velez-Garcia E, et al. A phase III randomized study comparing cisplatin and fluorouracil as single agents and in combination for advanced squamous cell carcinoma of the head and neck. J Clin Oncol 1992;10:257–263. Available at: http://www.ncbi.nlm.nih.gov/pubmed/1732427.

558. Burtness B, Goldwasser MA, Flood W, et al. Phase III randomized trial of cisplatin plus placebo compared with cisplatin plus cetuximab in metastatic/recurrent head and neck cancer: an Eastern Cooperative Oncology Group study. J Clin Oncol 2005;23:8646–8654. Available at: http://www.ncbi.nlm.nih.gov/pubmed/16314626.

559. Grau JJ, Caballero M, Verger E, et al. Weekly paclitaxel for platin-resistant stage IV head and neck cancer patients. Acta Otolaryngol 2009;129:1294–1299. Available at: http://www.ncbi.nlm.nih.gov/pubmed/19863327.

560. Guardiola E, Peyrade F, Chaigneau L, et al. Results of a randomised phase II study comparing docetaxel with methotrexate in patients with recurrent head and neck cancer. Eur J Cancer 2004;40:2071–2076. Available at: http://www.ncbi.nlm.nih.gov/pubmed/15341981.

561. Catimel G, Verweij J, Mattijssen V, et al. Docetaxel (Taxotere): an active drug for the treatment of patients with advanced squamous cell carcinoma of the head and neck. EORTC Early Clinical Trials Group. Ann

Discussion update in progress

Version 1.2026 © 2025 National Comprehensive Cancer Network© (NCCN©), All rights reserved. NCCN Guidelines® and this illustration may not be reproduced in any form without the express written permission of NCCN.

PLEASE NOTE that use of this NCCN Content is governed by the End-User License Agreement, and you MAY NOT distribute this Content or use it with any artificial intelligence model or tool.
Printed by Galya Basol Kochav on 1/4/2026 9:40:35 AM. Copyright © 2026 National Comprehensive Cancer Network, Inc. All Rights Reserved.

Oncol 1994;5:533–537. Available at: http://www.ncbi.nlm.nih.gov/pubmed/7918125.

562. Stewart JS, Cohen EE, Licitra L, et al. Phase III study of gefitinib compared with intravenous methotrexate for recurrent squamous cell carcinoma of the head and neck [corrected]. J Clin Oncol 2009;27:1864–1871. Available at: http://www.ncbi.nlm.nih.gov/pubmed/19289630.

563. Fury MG, Pfister DG. Current recommendations for systemic therapy of recurrent and/or metastatic head and neck squamous cell cancer. J Natl Compr Canc Netw 2011;9:681–689. Available at: http://www.ncbi.nlm.nih.gov/pubmed/21636539.

564. Price KA, Cohen EE. Current treatment options for metastatic head and neck cancer. Curr Treat Options Oncol 2012;13:35–46. Available at: http://www.ncbi.nlm.nih.gov/pubmed/22252884.

565. Martinez-Trufero J, Isla D, Adansa JC, et al. Phase II study of capecitabine as palliative treatment for patients with recurrent and metastatic squamous head and neck cancer after previous platinum-based treatment. Br J Cancer 2010;102:1687–1691. Available at: http://www.ncbi.nlm.nih.gov/pubmed/20485287.

566. Zhang L, Zhang Y, Huang P-Y, et al. Phase II clinical study of gemcitabine in the treatment of patients with advanced nasopharyngeal carcinoma after the failure of platinum-based chemotherapy. Cancer Chemother Pharmacol 2008;61:33–38. Available at: http://www.ncbi.nlm.nih.gov/pubmed/17909810.

567. Colevas AD. Chemotherapy options for patients with metastatic or recurrent squamous cell carcinoma of the head and neck. J Clin Oncol 2006;24:2644–2652. Available at: http://www.ncbi.nlm.nih.gov/pubmed/16763278.

568. Forastiere AA, Shank D, Neuberg D, et al. Final report of a phase II evaluation of paclitaxel in patients with advanced squamous cell carcinoma of the head and neck: an Eastern Cooperative Oncology Group trial (PA390). Cancer 1998;82:2270–2274. Available at: http://www.ncbi.nlm.nih.gov/pubmed/9610709.

569. Mai HQ, Chen QY, Chen D, et al. Toripalimab plus chemotherapy for recurrent or metastatic nasopharyngeal carcinoma: the JUPITER-02 randomized clinical trial. JAMA 2023;330:1961–1970. Available at: https://www.ncbi.nlm.nih.gov/pubmed/38015220.

570. Wang FH, Wei XL, Feng J, et al. Efficacy, safety, and correlative biomarkers of toripalimab in previously treated recurrent or metastatic nasopharyngeal carcinoma: a phase II clinical trial (POLARIS-02). J Clin Oncol 2021;39:704–712. Available at: https://www.ncbi.nlm.nih.gov/pubmed/33492986.

571. Shen L, Guo J, Zhang Q, et al. Tislelizumab in Chinese patients with advanced solid tumors: an open-label, non-comparative, phase 1/2 study. J Immunother Cancer 2020;8. Available at: https://www.ncbi.nlm.nih.gov/pubmed/32561638.

572. Yang Y, Qu S, Li J, et al. Camrelizumab versus placebo in combination with gemcitabine and cisplatin as first-line treatment for recurrent or metastatic nasopharyngeal carcinoma (CAPTAIN-1st): a multicentre, randomised, double-blind, phase 3 trial. Lancet Oncol 2021;22:1162–1174. Available at: https://www.ncbi.nlm.nih.gov/pubmed/34174189.

573. Hsu C, Lee SH, Ejadi S, et al. Safety and antitumor activity of pembrolizumab in patients with programmed death-ligand 1-positive nasopharyngeal carcinoma: results of the KEYNOTE-028 study. J Clin Oncol 2017;35:4050–4056. Available at: https://www.ncbi.nlm.nih.gov/pubmed/28837405.

574. Marabelle A, Fakih M, Lopez J, et al. Association of tumour mutational burden with outcomes in patients with advanced solid tumours treated with pembrolizumab: prospective biomarker analysis of the multicohort, open-label, phase 2 KEYNOTE-158 study. Lancet Oncol 2020;21:1353–1365. Available at: https://www.ncbi.nlm.nih.gov/pubmed/32919526.

575. Delord JP, Hollebecque A, de Boer JP, et al. An open-label, multicohort, phase I/II study to evaluate nivolumab in patients with virus-associated tumors (CheckMate 358): Efficacy and safety in recurrent or

Discussion update in progress

Version 1.2026 © 2025 National Comprehensive Cancer Network© (NCCN©), All rights reserved. NCCN Guidelines® and this illustration may not be reproduced in any form without the express written permission of NCCN.

PLEASE NOTE that use of this NCCN Content is governed by the End-User License Agreement, and you MAY NOT distribute this Content or use it with any artificial intelligence model or tool.
Printed by Galya Basol Kochav on 1/4/2026 9:40:35 AM. Copyright © 2026 National Comprehensive Cancer Network, Inc. All Rights Reserved.

metastatic (R/M) nasopharyngeal carcinoma (NPC). [abstract]. Presented at the ASCO Annual Meeting. 6025.

576. Sato H, Fushimi C, Okada T, et al. Investigation of the efficacy and safety of nivolumab in recurrent and metastatic nasopharyngeal carcinoma. In Vivo 2020;34:2967–2972. Available at: https://www.ncbi.nlm.nih.gov/pubmed/32871839.

577. Ma BBY, Lim WT, Goh BC, et al. Antitumor activity of nivolumab in recurrent and metastatic nasopharyngeal carcinoma: an international, multicenter study of the Mayo Clinic Phase 2 Consortium (NCI-9742). J Clin Oncol 2018;36:1412–1418. Available at: https://www.ncbi.nlm.nih.gov/pubmed/29584545.

578. Lee NY, Zhang Q, Pfister DG, et al. Addition of bevacizumab to standard chemoradiation for locoregionally advanced nasopharyngeal carcinoma (RTOG 0615): a phase 2 multi-institutional trial. Lancet Oncol 2012;13:172–180. Available at: http://www.ncbi.nlm.nih.gov/pubmed/22178121.

579. Huang CL, Zhang N, Jiang W, et al. Reduced-volume irradiation of uninvolved neck in patients with nasopharyngeal cancer: updated results from an open-label, noninferiority, multicenter, randomized phase III trial. J Clin Oncol 2024;42:2021–2025. Available at: https://www.ncbi.nlm.nih.gov/pubmed/38507662.

580. Tang LL, Huang CL, Zhang N, et al. Elective upper-neck versus whole-neck irradiation of the uninvolved neck in patients with nasopharyngeal carcinoma: an open-label, non-inferiority, multicentre, randomised phase 3 trial. Lancet Oncol 2022;23:479–490. Available at: https://www.ncbi.nlm.nih.gov/pubmed/35240053.

581. Salama JK, Haddad RI, Kies MS, et al. Clinical practice guidance for radiotherapy planning after induction chemotherapy in locoregionally advanced head-and-neck cancer. Int J Radiat Oncol Biol Phys 2009;75:725–733. Available at: http://www.ncbi.nlm.nih.gov/pubmed/19362781.

582. Liu YP, Wen YH, Tang J, et al. Endoscopic surgery compared with intensity-modulated radiotherapy in resectable locally recurrent nasopharyngeal carcinoma: a multicentre, open-label, randomised, controlled, phase 3 trial. Lancet Oncol 2021;22:381–390. Available at: https://www.ncbi.nlm.nih.gov/pubmed/33600761.

583. You R, Liu YP, Xie YL, et al. Hyperfractionation compared with standard fractionation in intensity-modulated radiotherapy for patients with locally advanced recurrent nasopharyngeal carcinoma: a multicentre, randomised, open-label, phase 3 trial. Lancet 2023;401:917–927. Available at: https://www.ncbi.nlm.nih.gov/pubmed/36842439.

584. Ng WT, Soong YL, Ahn YC, et al. International recommendations on reirradiation by intensity modulated radiation therapy for locally recurrent nasopharyngeal carcinoma. Int J Radiat Oncol Biol Phys 2021;110:682–695. Available at: https://www.ncbi.nlm.nih.gov/pubmed/33571626.

585. Takiar V, Garden AS, Ma D, et al. Reirradiation of head and neck cancers with intensity modulated radiation therapy: outcomes and analyses. Int J Radiat Oncol Biol Phys 2016;95:1117–1131. Available at: https://www.ncbi.nlm.nih.gov/pubmed/27354127.

586. Yamazaki H, Ogita M, Himei K, et al. Reirradiation using robotic image-guided stereotactic radiotherapy of recurrent head and neck cancer. J Radiat Res 2016;57:288–293. Available at: https://www.ncbi.nlm.nih.gov/pubmed/26983982.

587. Koutcher L, Lee N, Zelefsky M, et al. Reirradiation of locally recurrent nasopharynx cancer with external beam radiotherapy with or without brachytherapy. Int J Radiat Oncol Biol Phys 2010;76:130–137. Available at: https://www.ncbi.nlm.nih.gov/pubmed/19467802.

588. Rodel RM, Steiner W, Muller RM, et al. Endoscopic laser surgery of early glottic cancer: involvement of the anterior commissure. Head Neck 2009;31:583–592. Available at: http://www.ncbi.nlm.nih.gov/pubmed/19132720.

589. Zouhair A, Azria D, Coucke P, et al. Decreased local control following radiation therapy alone in early-stage glottic carcinoma with anterior

Discussion update in progress

Version 1.2026 © 2025 National Comprehensive Cancer Network© (NCCN©), All rights reserved. NCCN Guidelines® and this illustration may not be reproduced in any form without the express written permission of NCCN.

PLEASE NOTE that use of this NCCN Content is governed by the End-User License Agreement, and you MAY NOT distribute this Content or use it with any artificial intelligence model or tool.
Printed by Galya Basol Kochav on 1/4/2026 9:40:35 AM. Copyright © 2026 National Comprehensive Cancer Network, Inc. All Rights Reserved.

commissure extension. Strahlenther Onkol 2004;180:84–90. Available at: http://www.ncbi.nlm.nih.gov/pubmed/14762660.

590. Silver CE, Beitler JJ, Shaha AR, et al. Current trends in initial management of laryngeal cancer: the declining use of open surgery. Eur Arch Otorhinolaryngol 2009;266:1333–1352. Available at: http://www.ncbi.nlm.nih.gov/pubmed/19597837.

591. Warner L, Chudasama J, Kelly CG, et al. Radiotherapy versus open surgery versus endolaryngeal surgery (with or without laser) for early laryngeal squamous cell cancer. Cochrane Database Syst Rev 2014;2014:CD002027. Available at: https://www.ncbi.nlm.nih.gov/pubmed/25503538.

592. Warner L, Lee K, Homer JJ. Transoral laser microsurgery versus radiotherapy for T2 glottic squamous cell carcinoma: a systematic review of local control outcomes. Clin Otolaryngol 2017;42:629–636. Available at: https://www.ncbi.nlm.nih.gov/pubmed/27863075.

593. Mo HL, Li J, Yang X, et al. Transoral laser microsurgery versus radiotherapy for T1 glottic carcinoma: a systematic review and meta-analysis. Lasers Med Sci 2017;32:461–467. Available at: https://www.ncbi.nlm.nih.gov/pubmed/27966051.

594. Yoo J, Lacchetti C, Hammond JA, Gilbert RW. Role of endolaryngeal surgery (with or without laser) versus radiotherapy in the management of early (T1) glottic cancer: a systematic review. Head Neck 2014;36:1807–1819. Available at: https://www.ncbi.nlm.nih.gov/pubmed/24115131.

595. Fang R, Peng L, Chen L, et al. The survival benefit of lymph node dissection in resected T1-2, cN0 supraglottic cancer: a population-based propensity score matching analysis. Head Neck 2021;43:1300–1310. Available at: https://www.ncbi.nlm.nih.gov/pubmed/33372331.

596. Semrau S, Schmidt D, Lell M, et al. Results of chemoselection with short induction chemotherapy followed by chemoradiation or surgery in the treatment of functionally inoperable carcinomas of the pharynx and larynx. Oral Oncol 2013;49:454–460. Available at: https://www.ncbi.nlm.nih.gov/pubmed/23321550.

597. Stokes WA, Jones BL, Bhatia S, et al. A comparison of overall survival for patients with T4 larynx cancer treated with surgical versus organ-preservation approaches: A National Cancer Data Base analysis. Cancer 2017;123:600–608. Available at: https://www.ncbi.nlm.nih.gov/pubmed/27727461.

598. Gowda RV, Henk JM, Mais KL, et al. Three weeks radiotherapy for T1 glottic cancer: the Christie and Royal Marsden Hospital Experience. Radiother Oncol 2003;68:105–111. Available at: https://www.ncbi.nlm.nih.gov/pubmed/12972304.

599. Kodaira T, Kagami Y, Machida R, et al. Long-Term Follow-up of a Randomized Controlled Trial on Accelerated Radiation Therapy Versus Standard Fractionated Radiation Therapy for Early Glottic Cancer (JCOG0701A3). Int J Radiat Oncol Biol Phys 2023;117:1118–1124. Available at: https://www.ncbi.nlm.nih.gov/pubmed/37414261.

600. Katz TS, Mendenhall WM, Morris CG, et al. Malignant tumors of the nasal cavity and paranasal sinuses. Head Neck 2002;24:821–829. Available at: http://www.ncbi.nlm.nih.gov/pubmed/12211046.

601. Cohen ZR, Marmor E, Fuller GN, DeMonte F. Misdiagnosis of olfactory neuroblastoma. Neurosurg Focus 2002;12:e3. Available at: http://www.ncbi.nlm.nih.gov/pubmed/16119901.

602. Ejaz A, Wenig BM. Sinonasal undifferentiated carcinoma: clinical and pathologic features and a discussion on classification, cellular differentiation, and differential diagnosis. Adv Anat Pathol 2005;12:134–143. Available at: http://www.ncbi.nlm.nih.gov/pubmed/15900114.

603. Iezzoni JC, Mills SE. "Undifferentiated" small round cell tumors of the sinonasal tract: differential diagnosis update. Am J Clin Pathol 2005;124 Suppl:110–121. Available at: http://www.ncbi.nlm.nih.gov/pubmed/16468421.

604. French CA. NUT midline carcinoma. Cancer Genet Cytogenet 2010;203:16–20. Available at: https://www.ncbi.nlm.nih.gov/pubmed/20951314.

Discussion update in progress

Version 1.2026 © 2025 National Comprehensive Cancer Network© (NCCN©), All rights reserved. NCCN Guidelines® and this illustration may not be reproduced in any form without the express written permission of NCCN.

PLEASE NOTE that use of this NCCN Content is governed by the End-User License Agreement, and you MAY NOT distribute this Content or use it with any artificial intelligence model or tool.
Printed by Galya Basol Kochav on 1/4/2026 9:40:35 AM. Copyright © 2026 National Comprehensive Cancer Network, Inc. All Rights Reserved.

605. Soldatova L, Campbell RG, Carrau RL, et al. Sinonasal carcinomas with neuroendocrine features: histopathological differentiation and treatment outcomes. J Neurol Surg B Skull Base 2016;77:456–465. Available at: https://www.ncbi.nlm.nih.gov/pubmed/27857871.

606. Dulguerov P, Jacobsen MS, Allal AS, et al. Nasal and paranasal sinus carcinoma: are we making progress? A series of 220 patients and a systematic review. Cancer 2001;92:3012–3029. Available at: http://www.ncbi.nlm.nih.gov/pubmed/11753979.

607. Munoz J, Kuriakose P. Antibiotic-refractory sinusitis. JAMA 2012;308:2399–2400. Available at: http://www.ncbi.nlm.nih.gov/pubmed/23232896.

608. Oprea C, Cainap C, Azoulay R, et al. Primary diffuse large B-cell non-Hodgkin lymphoma of the paranasal sinuses: a report of 14 cases. Br J Haematol 2005;131:468–471. Available at: http://www.ncbi.nlm.nih.gov/pubmed/16281936.

609. Cantu G, Bimbi G, Miceli R, et al. Lymph node metastases in malignant tumors of the paranasal sinuses: prognostic value and treatment. Arch Otolaryngol Head Neck Surg 2008;134:170–177. Available at: https://www.ncbi.nlm.nih.gov/pubmed/18283160.

610. Rawal RB, Farzal Z, Federspiel JJ, et al. Endoscopic resection of sinonasal malignancy: a systematic review and meta-analysis. Otolaryngol Head Neck Surg 2016;155:376–386. Available at: https://www.ncbi.nlm.nih.gov/pubmed/27165676/.

611. Chen NX, Chen L, Wang JL, et al. A clinical study of multimodal treatment for orbital organ preservation in locally advanced squamous cell carcinoma of the nasal cavity and paranasal sinus. Jpn J Clin Oncol 2016;46:727–734. Available at: https://www.ncbi.nlm.nih.gov/pubmed/27207888.

612. Ock CY, Keam B, Kim TM, et al. Induction chemotherapy in head and neck squamous cell carcinoma of the paranasal sinus and nasal cavity: a role in organ preservation. Korean J Intern Med 2016;31:570–578. Available at: https://www.ncbi.nlm.nih.gov/pubmed/26976150.

613. Abdelmeguid AS, Teeramatwanich W, Roberts DB, et al. Neoadjuvant chemotherapy for locoregionally advanced squamous cell carcinoma of the paranasal sinuses. Cancer 2021;127:1788–1795. Available at: https://www.ncbi.nlm.nih.gov/pubmed/33567468.

614. Al-Mamgani A, van Rooij P, Mehilal R, et al. Combined-modality treatment improved outcome in sinonasal undifferentiated carcinoma: single-institutional experience of 21 patients and review of the literature. Eur Arch Otorhinolaryngol 2013;270:293–299. Available at: http://www.ncbi.nlm.nih.gov/pubmed/22476411.

615. Mourad WF, Hauerstock D, Shourbaji RA, et al. Trimodality management of sinonasal undifferentiated carcinoma and review of the literature. Am J Clin Oncol 2013;36:584–588. Available at: http://www.ncbi.nlm.nih.gov/pubmed/22992621.

616. Lin EM, Sparano A, Spalding A, et al. Sinonasal undifferentiated carcinoma: a 13-year experience at a single institution. Skull Base 2010;20:61–67. Available at: http://www.ncbi.nlm.nih.gov/pubmed/20808529.

617. Babin E, Rouleau V, Vedrine PO, et al. Small cell neuroendocrine carcinoma of the nasal cavity and paranasal sinuses. J Laryngol Otol 2006;120:289–297. Available at: http://www.ncbi.nlm.nih.gov/pubmed/16526967.

618. Chen AM, Daly ME, El-Sayed I, et al. Patterns of failure after combined-modality approaches incorporating radiotherapy for sinonasal undifferentiated carcinoma of the head and neck. Int J Radiat Oncol Biol Phys 2008;70:338–343. Available at: http://www.ncbi.nlm.nih.gov/pubmed/18207030.

619. Mendenhall WM, Mendenhall CM, Riggs CE, Jr., et al. Sinonasal undifferentiated carcinoma. Am J Clin Oncol 2006;29:27–31. Available at: http://www.ncbi.nlm.nih.gov/pubmed/16462499.

620. Kim BS, Vongtama R, Juillard G. Sinonasal undifferentiated carcinoma: case series and literature review. Am J Otolaryngol

Discussion update in progress

Version 1.2026 © 2025 National Comprehensive Cancer Network© (NCCN©), All rights reserved. NCCN Guidelines® and this illustration may not be reproduced in any form without the express written permission of NCCN.

PLEASE NOTE that use of this NCCN Content is governed by the End-User License Agreement, and you MAY NOT distribute this Content or use it with any artificial intelligence model or tool.
Printed by Galya Basol Kochav on 1/4/2026 9:40:35 AM. Copyright © 2026 National Comprehensive Cancer Network, Inc. All Rights Reserved.

2004;25:162–166. Available at: http://www.ncbi.nlm.nih.gov/pubmed/15124164.

621. Smith SR, Som P, Fahmy A, et al. A clinicopathological study of sinonasal neuroendocrine carcinoma and sinonasal undifferentiated carcinoma. Laryngoscope 2000;110:1617–1622. Available at: http://www.ncbi.nlm.nih.gov/pubmed/11037813.

622. Diaz EM, Johnigan RH, Pero C, et al. Olfactory neuroblastoma: the 22-year experience at one comprehensive cancer center. Head Neck 2005;27:138–149. Available at: http://www.ncbi.nlm.nih.gov/pubmed/15654688.

623. McLean JN, Nunley SR, Klass C, et al. Combined modality therapy of esthesioneuroblastoma. Otolaryngol Head Neck Surg 2007;136:998–1002. Available at: http://www.ncbi.nlm.nih.gov/pubmed/17547995.

624. de Gabory L, Abdulkhaleq HM, Darrouzet V, et al. Long-term results of 28 esthesioneuroblastomas managed over 35 years. Head Neck 2011;33:82–86. Available at: http://www.ncbi.nlm.nih.gov/pubmed/20848423.

625. Bachar G, Goldstein DP, Shah M, et al. Esthesioneuroblastoma: The Princess Margaret Hospital experience. Head Neck 2008;30:1607–1614. Available at: http://www.ncbi.nlm.nih.gov/pubmed/18798301.

626. Amit M, Abdelmeguid AS, Watcherporn T, et al. Induction chemotherapy response as a guide for treatment optimization in sinonasal undifferentiated carcinoma. J Clin Oncol 2019;37:504–512. Available at: https://www.ncbi.nlm.nih.gov/pubmed/30615549.

627. Patil VM, Joshi A, Noronha V, et al. Neoadjuvant chemotherapy in locally advanced and borderline resectable nonsquamous sinonasal tumors (esthesioneuroblastoma and sinonasal tumor with neuroendocrine differentiation). Int J Surg Oncol 2016;2016:6923730. Available at: https://www.ncbi.nlm.nih.gov/pubmed/26955484.

628. Resto VA, Eisele DW, Forastiere A, et al. Esthesioneuroblastoma: the Johns Hopkins experience. Head Neck 2000;22:550–558. Available at: https://www.ncbi.nlm.nih.gov/pubmed/10941155.

629. Urbanelli A, Nitro L, Pipolo C, et al. Therapeutic approaches to sinonasal NUT carcinoma: a systematic review. Eur Arch Otorhinolaryngol 2024;281:3361–3369. Available at: https://www.ncbi.nlm.nih.gov/pubmed/38329527.

630. Bauer N, Balourdas DI, Schneider JR, et al. Development of potent dual BET/HDAC inhibitors via pharmacophore merging and structure-guided optimization. ACS Chem Biol 2024;19:266–279. Available at: https://www.ncbi.nlm.nih.gov/pubmed/38291964.

631. Dirix P, Nuyts S, Geussens Y, et al. Malignancies of the nasal cavity and paranasal sinuses: long-term outcome with conventional or three-dimensional conformal radiotherapy. Int J Radiat Oncol Biol Phys 2007;69:1042–1050. Available at: http://www.ncbi.nlm.nih.gov/pubmed/17570610.

632. Hoppe BS, Stegman LD, Zelefsky MJ, et al. Treatment of nasal cavity and paranasal sinus cancer with modern radiotherapy techniques in the postoperative setting--the MSKCC experience. Int J Radiat Oncol Biol Phys 2007;67:691–702. Available at: http://www.ncbi.nlm.nih.gov/pubmed/17161557.

633. Chen AM, Daly ME, Bucci MK, et al. Carcinomas of the paranasal sinuses and nasal cavity treated with radiotherapy at a single institution over five decades: are we making improvement? Int J Radiat Oncol Biol Phys 2007;69:141–147. Available at: http://www.ncbi.nlm.nih.gov/pubmed/17459609.

634. Porceddu S, Martin J, Shanker G, et al. Paranasal sinus tumors: Peter MacCallum Cancer Institute experience. Head Neck 2004;26:322–330. Available at: http://www.ncbi.nlm.nih.gov/pubmed/15054735.

635. Al-Mamgani A, Monserez D, Rooij P, et al. Highly-conformal intensity-modulated radiotherapy reduced toxicity without jeopardizing outcome in patients with paranasal sinus cancer treated by surgery and radiotherapy

Discussion update in progress

Version 1.2026 © 2025 National Comprehensive Cancer Network© (NCCN©), All rights reserved. NCCN Guidelines® and this illustration may not be reproduced in any form without the express written permission of NCCN.

PLEASE NOTE that use of this NCCN Content is governed by the End-User License Agreement, and you MAY NOT distribute this Content or use it with any artificial intelligence model or tool.
Printed by Galya Basol Kochav on 1/4/2026 9:40:35 AM. Copyright © 2026 National Comprehensive Cancer Network, Inc. All Rights Reserved.

or (chemo)radiation. Oral Oncol 2012;48:905–911. Available at: http://www.ncbi.nlm.nih.gov/pubmed/22584070.

636. Dirix P, Vanstraelen B, Jorissen M, et al. Intensity-modulated radiotherapy for sinonasal cancer: improved outcome compared to conventional radiotherapy. Int J Radiat Oncol Biol Phys 2010;78:998–1004. Available at: http://www.ncbi.nlm.nih.gov/pubmed/20338694.

637. Hoppe BS, Nelson CJ, Gomez DR, et al. Unresectable carcinoma of the paranasal sinuses: outcomes and toxicities. Int J Radiat Oncol Biol Phys 2008;72:763–769. Available at: http://www.ncbi.nlm.nih.gov/pubmed/18395361.

638. Hoppe BS, Wolden SL, Zelefsky MJ, et al. Postoperative intensity-modulated radiation therapy for cancers of the paranasal sinuses, nasal cavity, and lacrimal glands: technique, early outcomes, and toxicity. Head Neck 2008;30:925–932. Available at: http://www.ncbi.nlm.nih.gov/pubmed/18302261.

639. Magrini SM, Buglione M, Corvo R, et al. Cetuximab and radiotherapy versus cisplatin and radiotherapy for locally advanced head and neck cancer: a randomized phase II trial. J Clin Oncol 2016;34:427–435. Available at: https://www.ncbi.nlm.nih.gov/pubmed/26644536.

640. Suntharalingam M, Haas ML, Conley BA, et al. The use of carboplatin and paclitaxel with daily radiotherapy in patients with locally advanced squamous cell carcinomas of the head and neck. Int J Radiat Oncol Biol Phys 2000;47:49–56. Available at: https://www.ncbi.nlm.nih.gov/pubmed/10758304.

641. Beckmann GK, Hoppe F, Pfreundner L, Flentje MP. Hyperfractionated accelerated radiotherapy in combination with weekly cisplatin for locally advanced head and neck cancer. Head Neck 2005;27:36–43. Available at: https://www.ncbi.nlm.nih.gov/pubmed/15459918.

642. Medina JA, Rueda A, de Pasos AS, et al. A phase II study of concomitant boost radiation plus concurrent weekly cisplatin for locally advanced unresectable head and neck carcinomas. Radiother Oncol 2006;79:34–38. Available at: https://www.ncbi.nlm.nih.gov/pubmed/16626826.

643. Kiyota N, Tahara M, Mizusawa J, et al. Weekly cisplatin plus radiation for postoperative head and neck cancer (JCOG1008): a multicenter, noninferiority, phase II/III randomized controlled trial. J Clin Oncol 2022;40:1980–1990. Available at: https://www.ncbi.nlm.nih.gov/pubmed/35230884.

644. Garden AS, Harris J, Vokes EE, et al. Preliminary results of Radiation Therapy Oncology Group 97-03: a randomized phase II trial of concurrent radiation and chemotherapy for advanced squamous cell carcinomas of the head and neck. J Clin Oncol 2004;22:2856–2864. Available at: http://www.ncbi.nlm.nih.gov/pubmed/15254053.

645. Taylor SG, Murthy AK, Vannetzel JM, et al. Randomized comparison of neoadjuvant cisplatin and fluorouracil infusion followed by radiation versus concomitant treatment in advanced head and neck cancer. J Clin Oncol 1994;12:385–395. Available at: https://www.ncbi.nlm.nih.gov/pubmed/8113846.

646. Sun XS, Michel C, Babin E, et al. Approach to oligometastatic disease in head and neck cancer, on behalf of the GORTEC. Future Oncol 2018;14:877–889. Available at: https://www.ncbi.nlm.nih.gov/pubmed/29578359.

647. Bonomo P, Greto D, Desideri I, et al. Clinical outcome of stereotactic body radiotherapy for lung-only oligometastatic head and neck squamous cell carcinoma: Is the deferral of systemic therapy a potential goal? Oral Oncol 2019;93:1–7. Available at: https://www.ncbi.nlm.nih.gov/pubmed/31109688.

648. Bates JE, De Leo AN, Morris CG, et al. Oligometastatic squamous cell carcinoma of the head and neck treated with stereotactic body ablative radiotherapy: single-institution outcomes. Head Neck 2019;41:2309–2314. Available at: https://www.ncbi.nlm.nih.gov/pubmed/30788878.

Discussion update in progress

Version 1.2026 © 2025 National Comprehensive Cancer Network© (NCCN©), All rights reserved. NCCN Guidelines® and this illustration may not be reproduced in any form without the express written permission of NCCN.

PLEASE NOTE that use of this NCCN Content is governed by the End-User License Agreement, and you MAY NOT distribute this Content or use it with any artificial intelligence model or tool.
Printed by Galya Basol Kochav on 1/4/2026 9:40:35 AM. Copyright © 2026 National Comprehensive Cancer Network, Inc. All Rights Reserved.

649. Molin Y, Fayette J. Current chemotherapies for recurrent/metastatic head and neck cancer. Anticancer Drugs 2011;22:621–625. Available at: http://www.ncbi.nlm.nih.gov/pubmed/21131821.

650. Hoffmann TK. Systemic therapy strategies for head-neck carcinomas: Current status. GMS Curr Top Otorhinolaryngol Head Neck Surg 2012;11:Doc03. Available at: http://www.ncbi.nlm.nih.gov/pubmed/23320055.

651. Browman GP, Cronin L. Standard chemotherapy in squamous cell head and neck cancer: what we have learned from randomized trials. Semin Oncol 1994;21:311–319. Available at: http://www.ncbi.nlm.nih.gov/pubmed/7516093.

652. Clavel M, Vermorken JB, Cognetti F, et al. Randomized comparison of cisplatin, methotrexate, bleomycin and vincristine (CABO) versus cisplatin and 5-fluorouracil (CF) versus cisplatin (C) in recurrent or metastatic squamous cell carcinoma of the head and neck. A phase III study of the EORTC Head and Neck Cancer Cooperative Group. Ann Oncol 1994;5:521–526. Available at: http://www.ncbi.nlm.nih.gov/pubmed/7522527.

653. Vermorken JB, Mesia R, Rivera F, et al. Platinum-based chemotherapy plus cetuximab in head and neck cancer. N Engl J Med 2008;359:1116–1127. Available at: http://www.ncbi.nlm.nih.gov/pubmed/18784101.

654. Burtness B, Harrington KJ, Greil R, et al. Pembrolizumab alone or with chemotherapy versus cetuximab with chemotherapy for recurrent or metastatic squamous cell carcinoma of the head and neck (KEYNOTE-048): a randomised, open-label, phase 3 study. Lancet 2019;394:1915–1928. Available at: https://www.ncbi.nlm.nih.gov/pubmed/31679945.

655. Cohen EEW, Soulieres D, Le Tourneau C, et al. Pembrolizumab versus methotrexate, docetaxel, or cetuximab for recurrent or metastatic head-and-neck squamous cell carcinoma (KEYNOTE-040): a randomised, open-label, phase 3 study. Lancet 2019;393:156–167. Available at: https://www.ncbi.nlm.nih.gov/pubmed/30509740.

656. Ferris RL, Blumenschein G, Jr., Fayette J, et al. Nivolumab for recurrent squamous-cell carcinoma of the head and neck. N Engl J Med 2016;375:1856–1867. Available at: https://www.ncbi.nlm.nih.gov/pubmed/27718784.

657. Harrington KJ, Burtness B, Greil R, et al. Pembrolizumab with or without chemotherapy in recurrent or metastatic head and neck squamous cell carcinoma: updated results of the phase III KEYNOTE-048 study. J Clin Oncol 2023;41:790–802. Available at: https://www.ncbi.nlm.nih.gov/pubmed/36219809.

658. Bossi P, Miceli R, Locati LD, et al. A randomized, phase 2 study of cetuximab plus cisplatin with or without paclitaxel for the first-line treatment of patients with recurrent and/or metastatic squamous cell carcinoma of the head and neck. Ann Oncol 2017;28:2820–2826. Available at: https://www.ncbi.nlm.nih.gov/pubmed/28950305.

659. Guigay J, Fayette J, Dillies A-F, et al. Cetuximab, docetaxel, and cisplatin (TPEx) as first-line treatment in patients with recurrent or metastatic (R/M) squamous cell carcinoma of the head and neck (SCCHN): Final results of phase II trial GORTEC 2008-03 [abstract]. J Clin Oncol 2012;30(Suppl 15):Abstract 5505. Available at: http://meeting.ascopubs.org/cgi/content/abstract/30/15_suppl/5505.

660. Herbst RS, Arquette M, Shin DM, et al. Phase II multicenter study of the epidermal growth factor receptor antibody cetuximab and cisplatin for recurrent and refractory squamous cell carcinoma of the head and neck. J Clin Oncol 2005;23:5578–5587. Available at: http://www.ncbi.nlm.nih.gov/pubmed/16009949.

661. Tahara M, Kiyota N, Yokota T, et al. Phase II trial of combination treatment with paclitaxel, carboplatin and cetuximab (PCE) as first-line treatment in patients with recurrent and/or metastatic squamous cell carcinoma of the head and neck (CSPOR-HN02). Ann Oncol 2018;29:1004–1009. Available at: https://www.ncbi.nlm.nih.gov/pubmed/29408977.

662. Guigay J, Auperin A, Fayette J, et al. Cetuximab, docetaxel, and cisplatin versus platinum, fluorouracil, and cetuximab as first-line treatment

Discussion update in progress

Version 1.2026 © 2025 National Comprehensive Cancer Network© (NCCN©), All rights reserved. NCCN Guidelines® and this illustration may not be reproduced in any form without the express written permission of NCCN.

PLEASE NOTE that use of this NCCN Content is governed by the End-User License Agreement, and you MAY NOT distribute this Content or use it with any artificial intelligence model or tool.
Printed by Galya Basol Kochav on 1/4/2026 9:40:35 AM. Copyright © 2026 National Comprehensive Cancer Network, Inc. All Rights Reserved.

in patients with recurrent or metastatic head and neck squamous-cell carcinoma (GORTEC 2014-01 TPExtreme): a multicentre, open-label, randomised, phase 2 trial. Lancet Oncol 2021;22:463–475. Available at: https://www.ncbi.nlm.nih.gov/pubmed/33684370.

663. Sacco AG, Chen R, Worden FP, et al. Pembrolizumab plus cetuximab in patients with recurrent or metastatic head and neck squamous cell carcinoma: an open-label, multi-arm, non-randomised, multicentre, phase 2 trial. Lancet Oncol 2021;22:883–892. Available at: https://www.ncbi.nlm.nih.gov/pubmed/33989559.

664. Chung CH, Li J, Steuer CE, et al. Phase II multi-institutional clinical trial result of concurrent cetuximab and nivolumab in recurrent and/or metastatic head and neck squamous cell carcinoma. Clin Cancer Res 2022;28:2329–2338. Available at: https://www.ncbi.nlm.nih.gov/pubmed/35344035.

665. Urba S, van Herpen CM, Sahoo TP, et al. Pemetrexed in combination with cisplatin versus cisplatin monotherapy in patients with recurrent or metastatic head and neck cancer: final results of a randomized, double-blind, placebo-controlled, phase 3 study. Cancer 2012;118:4694–4705. Available at: https://www.ncbi.nlm.nih.gov/pubmed/22434360.

666. Malhotra B, Moon J, Kucuk O, et al. Phase II trial of biweekly gemcitabine and paclitaxel with recurrent or metastatic squamous cell carcinoma of the head and neck: Southwest Oncology Group study S0329. Head Neck 2014;36:1712–1717. Available at: https://www.ncbi.nlm.nih.gov/pubmed/24166832.

667. Haddad RI, Harrington K, Tahara M, et al. Nivolumab plus ipilimumab versus extreme regimen as first-line treatment for recurrent/metastatic squamous cell carcinoma of the head and neck: the final results of CheckMate 651. J Clin Oncol 2023;41:2166–2180. Available at: https://www.ncbi.nlm.nih.gov/pubmed/36473143.

668. Haigentz M, Jr., Hartl DM, Silver CE, et al. Distant metastases from head and neck squamous cell carcinoma. Part III. Treatment. Oral Oncol 2012;48:787–793. Available at: http://www.ncbi.nlm.nih.gov/pubmed/22516376.

669. Vermorken JB, Trigo J, Hitt R, et al. Open-label, uncontrolled, multicenter phase II study to evaluate the efficacy and toxicity of cetuximab as a single agent in patients with recurrent and/or metastatic squamous cell carcinoma of the head and neck who failed to respond to platinum-based therapy. J Clin Oncol 2007;25:2171–2177. Available at: http://www.ncbi.nlm.nih.gov/pubmed/17538161.

670. Janot F, de Raucourt D, Benhamou E, et al. Randomized trial of postoperative reirradiation combined with chemotherapy after salvage surgery compared with salvage surgery alone in head and neck carcinoma. J Clin Oncol 2008;26:5518–5523. Available at: https://www.ncbi.nlm.nih.gov/pubmed/18936479.

671. Ward MC, Lee NY, Caudell JJ, et al. A competing risk nomogram to predict severe late toxicity after modern re-irradiation for squamous carcinoma of the head and neck. Oral Oncol 2019;90:80–86. Available at: https://www.ncbi.nlm.nih.gov/pubmed/30846182.

672. Kyrgias G, Hajiioannou J, Tolia M, et al. Intraoperative radiation therapy (IORT) in head and neck cancer: A systematic review. Medicine (Baltimore) 2016;95:e5035. Available at: https://www.ncbi.nlm.nih.gov/pubmed/27977569.

673. Tagliaferri L, Bussu F, Fionda B, et al. Perioperative HDR brachytherapy for reirradiation in head and neck recurrences: single-institution experience and systematic review. Tumori 2017;103:516–524. Available at: https://www.ncbi.nlm.nih.gov/pubmed/28291904.

674. Münter MW, Köppen U, Ramuscak A, et al. Intraoperative radiotherapy (IORT) in the treatment of head and neck cancer. Transl Cancer Res 2015;4:178–181. Available at: http://tcr.amegroups.com/article/view/4242.

675. Chen AM, Bucci MK, Singer MI, et al. Intraoperative radiation therapy for recurrent head-and-neck cancer: the UCSF experience. Int J Radiat Oncol Biol Phys 2007;67:122–129. Available at: https://www.ncbi.nlm.nih.gov/pubmed/17084543.

Discussion update in progress

Version 1.2026 © 2025 National Comprehensive Cancer Network© (NCCN©), All rights reserved. NCCN Guidelines® and this illustration may not be reproduced in any form without the express written permission of NCCN.

PLEASE NOTE that use of this NCCN Content is governed by the End-User License Agreement, and you MAY NOT distribute this Content or use it with any artificial intelligence model or tool.
Printed by Galya Basol Kochav on 1/4/2026 9:40:35 AM. Copyright © 2026 National Comprehensive Cancer Network, Inc. All Rights Reserved.

676. Strojan P, Corry J, Eisbruch A, et al. Recurrent and second primary squamous cell carcinoma of the head and neck: when and how to reirradiate. Head Neck 2015;37:134–150. Available at: https://www.ncbi.nlm.nih.gov/pubmed/24481720.

677. Tanvetyanon T, Padhya T, McCaffrey J, et al. Prognostic factors for survival after salvage reirradiation of head and neck cancer. J Clin Oncol 2009;27:1983–1991. Available at: https://www.ncbi.nlm.nih.gov/pubmed/19289616.

678. Lee JY, Suresh K, Nguyen R, et al. Predictors of severe long-term toxicity after re-irradiation for head and neck cancer. Oral Oncol 2016;60:32–40. Available at: https://www.ncbi.nlm.nih.gov/pubmed/27531870.

679. Ward MC, Riaz N, Caudell JJ, et al. Refining patient selection for reirradiation of head and neck squamous carcinoma in the IMRT era: a multi-institution cohort study by the MIRI Collaborative. Int J Radiat Oncol Biol Phys 2018;100:586–594. Available at: https://www.ncbi.nlm.nih.gov/pubmed/28865925.

680. Stoiber EM, Schwarz M, Debus J, et al. Regional cumulative maximum dose to the spinal cord in head-and-neck cancer: considerations for re-irradiation. Radiother Oncol 2013;106:96–100. Available at: https://www.ncbi.nlm.nih.gov/pubmed/23260860.

681. Nieder C, Grosu AL, Andratschke NH, Molls M. Update of human spinal cord reirradiation tolerance based on additional data from 38 patients. Int J Radiat Oncol Biol Phys 2006;66:1446–1449. Available at: https://www.ncbi.nlm.nih.gov/pubmed/17084560.

682. Phan J, Sio TT, Nguyen TP, et al. Reirradiation of head and neck cancers with proton therapy: outcomes and analyses. Int J Radiat Oncol Biol Phys 2016;96:30–41. Available at: https://www.ncbi.nlm.nih.gov/pubmed/27325480.

683. Romesser PB, Cahlon O, Scher ED, et al. Proton beam reirradiation for recurrent head and neck cancer: multi-institutional report on feasibility and early outcomes. Int J Radiat Oncol Biol Phys 2016;95:386–395. Available at: https://www.ncbi.nlm.nih.gov/pubmed/27084656.

684. Verma V, Rwigema JM, Malyapa RS, et al. Systematic assessment of clinical outcomes and toxicities of proton radiotherapy for reirradiation. Radiother Oncol 2017;125:21–30. Available at: https://www.ncbi.nlm.nih.gov/pubmed/28941560.

685. Caudell JJ, Ward MC, Riaz N, et al. Volume, dose, and fractionation considerations for IMRT-based reirradiation in head and neck cancer: a multi-institution analysis. Int J Radiat Oncol Biol Phys 2018;100:606–617. Available at: https://www.ncbi.nlm.nih.gov/pubmed/29413274.

686. Seiwert TY, Burtness B, Mehra R, et al. Safety and clinical activity of pembrolizumab for treatment of recurrent or metastatic squamous cell carcinoma of the head and neck (KEYNOTE-012): an open-label, multicentre, phase 1b trial. Lancet Oncol 2016;17:956–965. Available at: https://www.ncbi.nlm.nih.gov/pubmed/27247226.

687. Chow LQ, Haddad R, Gupta S, et al. Antitumor activity of pembrolizumab in biomarker-unselected patients with recurrent and/or metastatic head and neck squamous cell carcinoma: results from the phase Ib KEYNOTE-012 expansion cohort. J Clin Oncol 2016;34:3838–3845. Available at: https://www.ncbi.nlm.nih.gov/pubmed/27646946.

688. Mehra R, Seiwert TY, Gupta S, et al. Efficacy and safety of pembrolizumab in recurrent/metastatic head and neck squamous cell carcinoma: pooled analyses after long-term follow-up in KEYNOTE-012. Br J Cancer 2018;119:153–159. Available at: https://www.ncbi.nlm.nih.gov/pubmed/29955135.

689. Harrington KJ, Cohen EEW, Soulieres D, et al. Pembrolizumab versus methotrexate, docetaxel, or cetuximab in recurrent or metastatic head and neck squamous cell carcinoma (KEYNOTE-040): Subgroup analysis by pattern of disease recurrence. Oral Oncol 2023;147:106587. Available at: https://www.ncbi.nlm.nih.gov/pubmed/37925894.

690. Harrington KJ, Soulieres D, Le Tourneau C, et al. Quality of life with pembrolizumab for recurrent and/or metastatic head and neck squamous

Discussion update in progress

Version 1.2026 © 2025 National Comprehensive Cancer Network© (NCCN©), All rights reserved. NCCN Guidelines® and this illustration may not be reproduced in any form without the express written permission of NCCN.

PLEASE NOTE that use of this NCCN Content is governed by the End-User License Agreement, and you MAY NOT distribute this Content or use it with any artificial intelligence model or tool.
Printed by Galya Basol Kochav on 1/4/2026 9:40:35 AM. Copyright © 2026 National Comprehensive Cancer Network, Inc. All Rights Reserved.

cell carcinoma: KEYNOTE-040. J Natl Cancer Inst 2021;113:171–181. Available at: https://www.ncbi.nlm.nih.gov/pubmed/32407532.

691. Marabelle A, Le DT, Ascierto PA, et al. Efficacy of pembrolizumab in patients with noncolorectal high microsatellite instability/mismatch repair-deficient cancer: results from the phase II KEYNOTE-158 study. J Clin Oncol 2020;38:1–10. Available at: https://www.ncbi.nlm.nih.gov/pubmed/31682550.

692. Bauml J, Seiwert TY, Pfister DG, et al. Pembrolizumab for platinum- and cetuximab-refractory head and neck cancer: results from a single-arm, phase II study. J Clin Oncol 2017;35:1542–1549. Available at: https://www.ncbi.nlm.nih.gov/pubmed/28328302.

693. Machiels JP, Haddad RI, Fayette J, et al. Afatinib versus methotrexate as second-line treatment in patients with recurrent or metastatic squamous-cell carcinoma of the head and neck progressing on or after platinum-based therapy (LUX-Head & Neck 1): an open-label, randomised phase 3 trial. Lancet Oncol 2015;16:583–594. Available at: https://www.ncbi.nlm.nih.gov/pubmed/25892145.

694. Seiwert TY, Fayette J, Cupissol D, et al. A randomized, phase II study of afatinib versus cetuximab in metastatic or recurrent squamous cell carcinoma of the head and neck. Ann Oncol 2014;25:1813–1820. Available at: https://www.ncbi.nlm.nih.gov/pubmed/24928832.

695. Meric-Bernstam F, Makker V, Oaknin A, et al. Efficacy and safety of trastuzumab deruxtecan in patients with HER2-expressing solid tumors: primary results from the Destiny-PanTumor02 phase II trial. J Clin Oncol 2024;42:47–58. Available at: https://www.ncbi.nlm.nih.gov/pubmed/37870536.

696. Pant S, Schuler M, Iyer G, et al. Erdafitinib in patients with advanced solid tumours with FGFR alterations (RAGNAR): an international, single-arm, phase 2 study. Lancet Oncol 2023;24:925–935. Available at: https://www.ncbi.nlm.nih.gov/pubmed/37541273.

697. Roh JL, Kim JS, Lee JH, et al. Utility of combined (18)F-fluorodeoxyglucose-positron emission tomography and computed tomography in patients with cervical metastases from unknown primary tumors. Oral Oncol 2009;45:218–224. Available at: https://www.ncbi.nlm.nih.gov/pubmed/18804404.

698. Hohenstein NA, Chan JW, Wu SY, et al. Diagnosis, staging, radiation treatment response assessment, and outcome prognostication of head and neck cancers using PET imaging: a systematic review. PET Clin 2020;15:65–75. Available at: https://www.ncbi.nlm.nih.gov/pubmed/31735303.

699. Furniss CS, McClean MD, Smith JF, et al. Human papillomavirus 16 and head and neck squamous cell carcinoma. Int J Cancer 2007;120:2386–2392. Available at: http://www.ncbi.nlm.nih.gov/pubmed/17315185.

700. Fakhry C, Gillison ML. Clinical implications of human papillomavirus in head and neck cancers. J Clin Oncol 2006;24:2606–2611. Available at: http://www.ncbi.nlm.nih.gov/pubmed/16763272.

701. Loughrey M, Trivett M, Lade S, et al. Diagnostic application of Epstein-Barr virus-encoded RNA in situ hybridisation. Pathology 2004;36:301–308. Available at: http://www.ncbi.nlm.nih.gov/pubmed/15370127.

702. Yap Y-Y, Hassan S, Chan M, et al. Epstein-Barr virus DNA detection in the diagnosis of nasopharyngeal carcinoma. Otolaryngol Head Neck Surg 2007;136:986–991. Available at: http://www.ncbi.nlm.nih.gov/pubmed/17547993.

703. Fakhry C, Lacchetti C, Rooper LM, et al. Human papillomavirus testing in head and neck carcinomas: ASCO Clinical Practice Guideline endorsement of the College of American Pathologists Guideline. J Clin Oncol 2018;36:3152–3161. Available at: https://www.ncbi.nlm.nih.gov/pubmed/30188786.

704. Boscolo-Rizzo P, Schroeder L, Romeo S, Pawlita M. The prevalence of human papillomavirus in squamous cell carcinoma of unknown primary site metastatic to neck lymph nodes: a systematic review. Clin Exp

Discussion update in progress

Version 1.2026 © 2025 National Comprehensive Cancer Network© (NCCN©), All rights reserved. NCCN Guidelines® and this illustration may not be reproduced in any form without the express written permission of NCCN.

PLEASE NOTE that use of this NCCN Content is governed by the End-User License Agreement, and you MAY NOT distribute this Content or use it with any artificial intelligence model or tool.
Printed by Galya Basol Kochav on 1/4/2026 9:40:35 AM. Copyright © 2026 National Comprehensive Cancer Network, Inc. All Rights Reserved.

Metastasis 2015;32:835–845. Available at: https://www.ncbi.nlm.nih.gov/pubmed/26358913.

705. Bussu F, Sali M, Gallus R, et al. HPV and EBV infections in neck metastases from occult primary squamous cell carcinoma: another virus-related neoplastic disease in the head and neck region. Ann Surg Oncol 2015;22 Suppl 3:S979–984. Available at: https://www.ncbi.nlm.nih.gov/pubmed/26286196.

706. Frank SJ, Rosenthal DI, Petsuksiri J, et al. Intensity-modulated radiotherapy for cervical node squamous cell carcinoma metastases from unknown head-and-neck primary site: M. D. Anderson Cancer Center outcomes and patterns of failure. Int J Radiat Oncol Biol Phys 2010;78:1005–1010. Available at: https://www.ncbi.nlm.nih.gov/pubmed/20207504.

707. Svajdler M, Jr., Kaspirkova J, Hadravsky L, et al. Origin of cystic squamous cell carcinoma metastases in head and neck lymph nodes: addition of EBV testing improves diagnostic accuracy. Pathol Res Pract 2016;212:524–531. Available at: https://www.ncbi.nlm.nih.gov/pubmed/27013059.

708. Spiro RH. Salivary neoplasms: overview of a 35-year experience with 2,807 patients. Head Neck Surg 1986;8:177–184. Available at: http://www.ncbi.nlm.nih.gov/pubmed/3744850.

709. Bron LP, Traynor SJ, McNeil EB, O'Brien CJ. Primary and metastatic cancer of the parotid: comparison of clinical behavior in 232 cases. Laryngoscope 2003;113:1070–1075. Available at: http://www.ncbi.nlm.nih.gov/pubmed/12782825.

710. Nagliati M, Bolner A, Vanoni V, et al. Surgery and radiotherapy in the treatment of malignant parotid tumors: a retrospective multicenter study. Tumori 2009;95:442–448. Available at: http://www.ncbi.nlm.nih.gov/pubmed/19856654.

711. Garden AS, Weber RS, Morrison WH, et al. The influence of positive margins and nerve invasion in adenoid cystic carcinoma of the head and neck treated with surgery and radiation. Int J Radiat Oncol Biol Phys 1995;32:619–626. Available at: http://www.ncbi.nlm.nih.gov/pubmed/7790247.

712. Bell RB, Dierks EJ, Homer L, Potter BE. Management and outcome of patients with malignant salivary gland tumors. J Oral Maxillofac Surg 2005;63:917–928. Available at: http://www.ncbi.nlm.nih.gov/pubmed/16003616.

713. Copelli C, Bianchi B, Ferrari S, et al. Malignant tumors of intraoral minor salivary glands. Oral Oncol 2008;44:658–663. Available at: http://www.ncbi.nlm.nih.gov/pubmed/17996484.

714. Vander Poorten V, Bradley PJ, Takes RP, et al. Diagnosis and management of parotid carcinoma with a special focus on recent advances in molecular biology. Head Neck 2012;34:429–440. Available at: http://www.ncbi.nlm.nih.gov/pubmed/21618326.

715. Timoshchuk MA, Dekker P, Hippe DS, et al. The efficacy of neutron radiation therapy in treating salivary gland malignancies. Oral Oncol 2019;88:51–57. Available at: https://www.ncbi.nlm.nih.gov/pubmed/30616797.

716. Laramore GE, Krall JM, Griffin TW, et al. Neutron versus photon irradiation for unresectable salivary gland tumors: final report of an RTOG-MRC randomized clinical trial. Radiation Therapy Oncology Group. Medical Research Council. Int J Radiat Oncol Biol Phys 1993;27:235–240. Available at: http://www.ncbi.nlm.nih.gov/pubmed/8407397.

717. Stannard C, Vernimmen F, Carrara H, et al. Malignant salivary gland tumours: can fast neutron therapy results point the way to carbon ion therapy? Radiother Oncol 2013;109:262–268. Available at: http://www.ncbi.nlm.nih.gov/pubmed/24044797.

718. Cederblad L, Johansson S, Enblad G, et al. Cancer of the parotid gland; long-term follow-up. A single centre experience on recurrence and survival. Acta Oncol 2009;48:549–555. Available at: http://www.ncbi.nlm.nih.gov/pubmed/19140053.

Discussion update progress

Version 1.2026 © 2025 National Comprehensive Cancer Network© (NCCN©), All rights reserved. NCCN Guidelines® and this illustration may not be reproduced in any form without the express written permission of NCCN.

PLEASE NOTE that use of this NCCN Content is governed by the End-User License Agreement, and you MAY NOT distribute this Content or use it with any artificial intelligence model or tool.
Printed by Galya Basol Kochav on 1/4/2026 9:40:35 AM. Copyright © 2026 National Comprehensive Cancer Network, Inc. All Rights Reserved.

719. Eppsteiner RW, Fowlkes JW, Anderson CM, et al. Aggressive salivary malignancies at early stage: outcomes and implications for treatment. Ann Otol Rhinol Laryngol 2017;126:525–529. Available at: https://www.ncbi.nlm.nih.gov/pubmed/28474964.

720. Terhaard CH, Lubsen H, Rasch CR, et al. The role of radiotherapy in the treatment of malignant salivary gland tumors. Int J Radiat Oncol Biol Phys 2005;61:103–111. Available at: https://www.ncbi.nlm.nih.gov/pubmed/15629600.

721. Tanvetyanon T, Qin D, Padhya T, et al. Outcomes of postoperative concurrent chemoradiotherapy for locally advanced major salivary gland carcinoma. Arch Otolaryngol Head Neck Surg 2009;135:687–692. Available at: http://www.ncbi.nlm.nih.gov/pubmed/19620591.

722. Skalova A. Mammary analogue secretory carcinoma of salivary gland origin: an update and expanded morphologic and immunohistochemical spectrum of recently described entity. Head Neck Pathol 2013;7 Suppl 1:S30–36. Available at: https://www.ncbi.nlm.nih.gov/pubmed/23821207.

723. Hanna GJ, Guenette JP, Chau NG, et al. Tipifarnib in recurrent, metastatic HRAS-mutant salivary gland cancer. Cancer 2020;126:3972–3981. Available at: https://www.ncbi.nlm.nih.gov/pubmed/32557577.

724. Williams L, Thompson LD, Seethala RR, et al. Salivary duct carcinoma: the predominance of apocrine morphology, prevalence of histologic variants, and androgen receptor expression. Am J Surg Pathol 2015;39:705–713. Available at: https://www.ncbi.nlm.nih.gov/pubmed/25871467.

725. Udager AM, Chiosea SI. Salivary duct carcinoma: an update on morphologic mimics and diagnostic use of androgen receptor immunohistochemistry. Head Neck Pathol 2017;11:288–294. Available at: https://www.ncbi.nlm.nih.gov/pubmed/28321773.

726. Simpson RH. Salivary duct carcinoma: new developments--morphological variants including pure in situ high grade lesions; proposed molecular classification. Head Neck Pathol 2013;7 Suppl 1:S48–58. Available at: https://www.ncbi.nlm.nih.gov/pubmed/23821208.

727. Fan CY, Wang J, Barnes EL. Expression of androgen receptor and prostatic specific markers in salivary duct carcinoma: an immunohistochemical analysis of 13 cases and review of the literature. Am J Surg Pathol 2000;24:579–586. Available at: https://www.ncbi.nlm.nih.gov/pubmed/10757407/.

728. Schmitt NC, Kang H, Sharma A. Salivary duct carcinoma: an aggressive salivary gland malignancy with opportunities for targeted therapy. Oral Oncol 2017;74:40–48. Available at: https://www.ncbi.nlm.nih.gov/pubmed/29103750.

729. Drilon A, Laetsch TW, Kummar S, et al. Efficacy of larotrectinib in TRK fusion-positive cancers in adults and children. N Engl J Med 2018;378:731–739. Available at: https://www.ncbi.nlm.nih.gov/pubmed/29466156.

730. Hong DS, Bauer TM, Lee JJ, et al. Larotrectinib in adult patients with solid tumours: a multi-centre, open-label, phase I dose-escalation study. Ann Oncol 2019;30:325–331. Available at: https://www.ncbi.nlm.nih.gov/pubmed/30624546.

731. Doebele RC, Drilon A, Paz-Ares L, et al. Entrectinib in patients with advanced or metastatic NTRK fusion-positive solid tumours: integrated analysis of three phase 1-2 trials. Lancet Oncol 2020;21:271–282. Available at: https://www.ncbi.nlm.nih.gov/pubmed/31838007.

732. Lin VTG, Nabell LM, Spencer SA, et al. First-line treatment of widely metastatic BRAF-mutated salivary duct carcinoma with combined BRAF and MEK inhibition. J Natl Compr Canc Netw 2018;16:1166–1170. Available at: https://www.ncbi.nlm.nih.gov/pubmed/30323086.

733. Subbiah V, Wolf J, Konda B, et al. Tumour-agnostic efficacy and safety of selpercatinib in patients with RET fusion-positive solid tumours other than lung or thyroid tumours (LIBRETTO-001): a phase 1/2, open-label, basket trial. Lancet Oncol 2022;23:1261–1273. Available at: https://www.ncbi.nlm.nih.gov/pubmed/36108661.

734. Boon E, van Boxtel W, Buter J, et al. Androgen deprivation therapy for androgen receptor-positive advanced salivary duct carcinoma: a

Discussion update in progress

Version 1.2026 © 2025 National Comprehensive Cancer Network© (NCCN©), All rights reserved. NCCN Guidelines® and this illustration may not be reproduced in any form without the express written permission of NCCN.

PLEASE NOTE that use of this NCCN Content is governed by the End-User License Agreement, and you MAY NOT distribute this Content or use it with any artificial intelligence model or tool.
Printed by Galya Basol Kochav on 1/4/2026 9:40:35 AM. Copyright © 2026 National Comprehensive Cancer Network, Inc. All Rights Reserved.

nationwide case series of 35 patients in the Netherlands. Head Neck 2018;40:605–613. Available at: https://www.ncbi.nlm.nih.gov/pubmed/29272069.

735. Yamamoto N, Minami S, Fujii M. Clinicopathologic study of salivary duct carcinoma and the efficacy of androgen deprivation therapy. Am J Otolaryngol 2014;35:731–735. Available at: https://www.ncbi.nlm.nih.gov/pubmed/25087467.

736. Fushimi C, Tada Y, Takahashi H, et al. A prospective phase II study of combined androgen blockade in patients with androgen receptor-positive metastatic or locally advanced unresectable salivary gland carcinoma. Ann Oncol 2018;29:979–984. Available at: https://www.ncbi.nlm.nih.gov/pubmed/29211833.

737. Locati LD, Cavalieri S, Bergamini C, et al. Abiraterone acetate in patients with castration-resistant, androgen receptor-expressing salivary gland cancer: a phase II trial. J Clin Oncol 2021;39:4061–4068. Available at: https://www.ncbi.nlm.nih.gov/pubmed/34597119.

738. Solomon BJ, Drilon A, Lin JJ, et al. Repotrectinib in patients (pts) with NTRK fusion-positive (NTRK+) advanced solid tumors, including NSCLC: update from the phase I/II TRIDENT-1 trial. Annals of Oncology 2023;34:S787–S788. Available at: https://doi.org/10.1016/j.annonc.2023.09.2405.

739. Gilbert MR, Sharma A, Schmitt NC, et al. A 20-year review of 75 cases of salivary duct carcinoma. JAMA Otolaryngol Head Neck Surg 2016;142:489–495. Available at: https://www.ncbi.nlm.nih.gov/pubmed/26939990.

740. Thorpe LM, Schrock AB, Erlich RL, et al. Significant and durable clinical benefit from trastuzumab in 2 patients with HER2-amplified salivary gland cancer and a review of the literature. Head Neck 2017;39:E40–e44. Available at: https://www.ncbi.nlm.nih.gov/pubmed/28006087.

741. Correa TS, Matos GDR, Segura M, Dos Anjos CH. Second-line treatment of HER2-positive salivary gland tumor: ado-trastuzumab emtansine (T-DM1) after progression on trastuzumab. Case Rep Oncol 2018;11:252–257. Available at: https://www.ncbi.nlm.nih.gov/pubmed/29867432.

742. Jhaveri KL, Wang XV, Makker V, et al. Ado-trastuzumab emtansine (T-DM1) in patients with HER2-amplified tumors excluding breast and gastric/gastroesophageal junction (GEJ) adenocarcinomas: results from the NCI-MATCH trial (EAY131) subprotocol Q. Ann Oncol 2019;30:1821–1830. Available at: https://www.ncbi.nlm.nih.gov/pubmed/31504139.

743. Takahashi H, Tada Y, Saotome T, et al. Phase II trial of trastuzumab and docetaxel in patients with human epidermal growth factor receptor 2-positive salivary duct carcinoma. J Clin Oncol 2019;37:125–134. Available at: https://www.ncbi.nlm.nih.gov/pubmed/30452336.

744. Kurzrock R, Bowles DW, Kang H, et al. Targeted therapy for advanced salivary gland carcinoma based on molecular profiling: results from MyPathway, a phase IIa multiple basket study. Ann Oncol 2020;31:412–421. Available at: https://www.ncbi.nlm.nih.gov/pubmed/32067683.

745. Bando H, Kinoshita I, Modi S, et al. Trastuzumab deruxtecan (T-DXd) in patients with human epidermal growth factor receptor 2 (HER2)-expressing salivary duct carcinoma: subgroup analysis of two phase 1 studies. Journal of Clinical Oncology 2021;39:6079–6079. Available at: https://ascopubs.org/doi/abs/10.1200/JCO.2021.39.15_suppl.6079.

746. Tsurutani J, Iwata H, Krop I, et al. Targeting HER2 with trastuzumab deruxtecan: a dose-expansion, phase I study in multiple advanced solid tumors. Cancer Discov 2020;10:688–701. Available at: https://www.ncbi.nlm.nih.gov/pubmed/32213540.

747. Licitra L, Cavina R, Grandi C, et al. Cisplatin, doxorubicin and cyclophosphamide in advanced salivary gland carcinoma. A phase II trial of 22 patients. Ann Oncol 1996;7:640–642. Available at: http://www.ncbi.nlm.nih.gov/pubmed/8879381.

748. Airoldi M, Pedani F, Succo G, et al. Phase II randomized trial comparing vinorelbine versus vinorelbine plus cisplatin in patients with

Discussion update in progress

Version 1.2026 © 2025 National Comprehensive Cancer Network© (NCCN©), All rights reserved. NCCN Guidelines® and this illustration may not be reproduced in any form without the express written permission of NCCN.

PLEASE NOTE that use of this NCCN Content is governed by the End-User License Agreement, and you MAY NOT distribute this Content or use it with any artificial intelligence model or tool.
Printed by Galya Basol Kochav on 1/4/2026 9:40:35 AM. Copyright © 2026 National Comprehensive Cancer Network, Inc. All Rights Reserved.

recurrent salivary gland malignancies. Cancer 2001;91:541–547. Available at: http://www.ncbi.nlm.nih.gov/pubmed/11169936.

749. Nakano K, Sato Y, Sasaki T, et al. Combination chemotherapy of carboplatin and paclitaxel for advanced/metastatic salivary gland carcinoma patients: differences in responses by different pathological diagnoses. Acta Otolaryngol 2016;136:948–951. Available at: https://www.ncbi.nlm.nih.gov/pubmed/27094013.

750. Laurie SA, Siu LL, Winquist E, et al. A phase 2 study of platinum and gemcitabine in patients with advanced salivary gland cancer: a trial of the NCIC Clinical Trials Group. Cancer 2010;116:362–368. Available at: https://www.ncbi.nlm.nih.gov/pubmed/19924794.

751. Sousa LG, Wang K, Torman D, et al. Treatment patterns and outcomes of palliative systemic therapy in patients with salivary duct carcinoma and adenocarcinoma, not otherwise specified. Cancer 2022;128:509–518. Available at: https://www.ncbi.nlm.nih.gov/pubmed/34661906.

752. Gilbert J, Li Y, Pinto HA, et al. Phase II trial of taxol in salivary gland malignancies (E1394): a trial of the Eastern Cooperative Oncology Group. Head Neck 2006;28:197–204. Available at: http://www.ncbi.nlm.nih.gov/pubmed/16470745.

753. Locati LD, Cavalieri S, Bergamini C, et al. Phase II trial with axitinib in recurrent and/or metastatic salivary gland cancers of the upper aerodigestive tract. Head Neck 2019;41:3670–3676. Available at: https://www.ncbi.nlm.nih.gov/pubmed/31355973.

754. Thomson DJ, Silva P, Denton K, et al. Phase II trial of sorafenib in advanced salivary adenoid cystic carcinoma of the head and neck. Head Neck 2015;37:182–187. Available at: https://www.ncbi.nlm.nih.gov/pubmed/24346857.

755. Ferrarotto R, Sousa LG, Feng L, et al. Phase II clinical trial of axitinib and avelumab in patients with recurrent/metastatic adenoid cystic carcinoma. J Clin Oncol 2023;41:2843–2851. Available at: https://www.ncbi.nlm.nih.gov/pubmed/36898078.

756. Chau NG, Hotte SJ, Chen EX, et al. A phase II study of sunitinib in recurrent and/or metastatic adenoid cystic carcinoma (ACC) of the salivary glands: current progress and challenges in evaluating molecularly targeted agents in ACC. Ann Oncol 2012;23:1562–1570. Available at: https://www.ncbi.nlm.nih.gov/pubmed/22080184.

757. Keam B, Kim SB, Shin SH, et al. Phase 2 study of dovitinib in patients with metastatic or unresectable adenoid cystic carcinoma. Cancer 2015;121:2612–2617. Available at: https://www.ncbi.nlm.nih.gov/pubmed/25903089.

758. Tchekmedyian V, Sherman EJ, Dunn L, et al. Phase II study of lenvatinib in patients with progressive, recurrent or metastatic adenoid cystic carcinoma. J Clin Oncol 2019;37:1529–1537. Available at: https://www.ncbi.nlm.nih.gov/pubmed/30939095.

759. Locati LD, Galbiati D, Calareso G, et al. Patients with adenoid cystic carcinomas of the salivary glands treated with lenvatinib: activity and quality of life. Cancer 2020;126:1888–1894. Available at: https://www.ncbi.nlm.nih.gov/pubmed/32031693.

760. Marcus DM, Marcus RP, Prabhu RS, et al. Rising incidence of mucosal melanoma of the head and neck in the United States. J Skin Cancer 2012;2012:231693. Available at: http://www.ncbi.nlm.nih.gov/pubmed/23251803.

761. McLaughlin CC, Wu XC, Jemal A, et al. Incidence of noncutaneous melanomas in the U.S. Cancer 2005;103:1000–1007. Available at: http://www.ncbi.nlm.nih.gov/pubmed/15651058.

762. Chang AE, Karnell LH, Menck HR. The National Cancer Data Base report on cutaneous and noncutaneous melanoma: a summary of 84,836 cases from the past decade. The American College of Surgeons Commission on Cancer and the American Cancer Society. Cancer 1998;83:1664–1678. Available at: http://www.ncbi.nlm.nih.gov/pubmed/9781962.

763. Bachar G, Loh KS, O'Sullivan B, et al. Mucosal melanomas of the head and neck: experience of the Princess Margaret Hospital. Head Neck

Discussion update in progress

Version 1.2026 © 2025 National Comprehensive Cancer Network© (NCCN©), All rights reserved. NCCN Guidelines® and this illustration may not be reproduced in any form without the express written permission of NCCN.

PLEASE NOTE that use of this NCCN Content is governed by the End-User License Agreement, and you MAY NOT distribute this Content or use it with any artificial intelligence model or tool.
Printed by Galya Basol Kochav on 1/4/2026 9:40:35 AM. Copyright © 2026 National Comprehensive Cancer Network, Inc. All Rights Reserved.

2008;30:1325–1331. Available at: http://www.ncbi.nlm.nih.gov/pubmed/18704964.

764. McLean N, Tighiouart M, Muller S. Primary mucosal melanoma of the head and neck. Comparison of clinical presentation and histopathologic features of oral and sinonasal melanoma. Oral Oncol 2008;44:1039–1046. Available at: http://www.ncbi.nlm.nih.gov/pubmed/18396446.

765. Patel SG, Prasad ML, Escrig M, et al. Primary mucosal malignant melanoma of the head and neck. Head Neck 2002;24:247–257. Available at: http://www.ncbi.nlm.nih.gov/pubmed/11891956.

766. Meleti M, Leemans CR, de Bree R, et al. Head and neck mucosal melanoma: experience with 42 patients, with emphasis on the role of postoperative radiotherapy. Head Neck 2008;30:1543–1551. Available at: http://www.ncbi.nlm.nih.gov/pubmed/18704960.

767. Ang KK, Peters LJ, Weber RS, et al. Postoperative radiotherapy for cutaneous melanoma of the head and neck region. Int J Radiat Oncol Biol Phys 1994;30:795–798. Available at: http://www.ncbi.nlm.nih.gov/pubmed/7960981.

768. Agrawal S, Kane JM, 3rd, Guadagnolo BA, et al. The benefits of adjuvant radiation therapy after therapeutic lymphadenectomy for clinically advanced, high-risk, lymph node-metastatic melanoma. Cancer 2009;115:5836–5844. Available at: http://www.ncbi.nlm.nih.gov/pubmed/19701906.

769. Douglas CM, Malik T, Swindell R, et al. Mucosal melanoma of the head and neck: radiotherapy or surgery? J Otolaryngol Head Neck Surg 2010;39:385–392. Available at: http://www.ncbi.nlm.nih.gov/pubmed/20643003.

770. Gavriel H, McArthur G, Sizeland A, Henderson M. Review: mucosal melanoma of the head and neck. Melanoma Res 2011;21:257–266. Available at: http://www.ncbi.nlm.nih.gov/pubmed/21540752.

771. Temam S, Mamelle G, Marandas P, et al. Postoperative radiotherapy for primary mucosal melanoma of the head and neck. Cancer 2005;103:313–319. Available at: http://www.ncbi.nlm.nih.gov/pubmed/15578718.

772. Burmeister BH, Henderson MA, Ainslie J, et al. Adjuvant radiotherapy versus observation alone for patients at risk of lymph-node field relapse after therapeutic lymphadenectomy for melanoma: a randomised trial. Lancet Oncol 2012;13:589–597. Available at: http://www.ncbi.nlm.nih.gov/pubmed/22575589.

773. Moreno MA, Roberts DB, Kupferman ME, et al. Mucosal melanoma of the nose and paranasal sinuses, a contemporary experience from the M. D. Anderson Cancer Center. Cancer 2010;116:2215–2223. Available at: http://www.ncbi.nlm.nih.gov/pubmed/20198705.

774. Benlyazid A, Thariat J, Temam S, et al. Postoperative radiotherapy in head and neck mucosal melanoma: a GETTEC study. Arch Otolaryngol Head Neck Surg 2010;136:1219–1225. Available at: http://www.ncbi.nlm.nih.gov/pubmed/21173371.

775. Saigal K, Weed DT, Reis IM, et al. Mucosal melanomas of the head and neck: the role of postoperative radiation therapy. ISRN Oncol 2012;2012:785131. Available at: http://www.ncbi.nlm.nih.gov/pubmed/22577582.

776. Owens JM, Roberts DB, Myers JN. The role of postoperative adjuvant radiation therapy in the treatment of mucosal melanomas of the head and neck region. Arch Otolaryngol Head Neck Surg 2003;129:864–868. Available at: http://www.ncbi.nlm.nih.gov/pubmed/12925346.

777. Gilligan D, Slevin NJ. Radical radiotherapy for 28 cases of mucosal melanoma in the nasal cavity and sinuses. Br J Radiol 1991;64:1147–1150. Available at: http://www.ncbi.nlm.nih.gov/pubmed/1773274.

778. Shibuya H, Takeda M, Matsumoto S, et al. The efficacy of radiation therapy for a malignant melanoma in the mucosa of the upper jaw: an analytic study. Int J Radiat Oncol Biol Phys 1993;25:35–39. Available at: http://www.ncbi.nlm.nih.gov/pubmed/8416880.

Discussion update in progress

Version 1.2026 © 2025 National Comprehensive Cancer Network© (NCCN©), All rights reserved. NCCN Guidelines® and this illustration may not be reproduced in any form without the express written permission of NCCN.

PLEASE NOTE that use of this NCCN Content is governed by the End-User License Agreement, and you MAY NOT distribute this Content or use it with any artificial intelligence model or tool.
Printed by Galya Basol Kochav on 1/4/2026 9:40:35 AM. Copyright © 2026 National Comprehensive Cancer Network, Inc. All Rights Reserved.

779. Wada H, Nemoto K, Ogawa Y, et al. A multi-institutional retrospective analysis of external radiotherapy for mucosal melanoma of the head and neck in Northern Japan. Int J Radiat Oncol Biol Phys 2004;59:495–500. Available at: http://www.ncbi.nlm.nih.gov/pubmed/15145168.

780. Bonnen MD, Ballo MT, Myers JN, et al. Elective radiotherapy provides regional control for patients with cutaneous melanoma of the head and neck. Cancer 2004;100:383–389. Available at: http://www.ncbi.nlm.nih.gov/pubmed/14716775.

781. Ballo MT, Bonnen MD, Garden AS, et al. Adjuvant irradiation for cervical lymph node metastases from melanoma. Cancer 2003;97:1789–1796. Available at: http://www.ncbi.nlm.nih.gov/pubmed/12655537.

782. Wu AJ, Gomez J, Zhung JE, et al. Radiotherapy after surgical resection for head and neck mucosal melanoma. Am J Clin Oncol 2010;33:281–285. Available at: http://www.ncbi.nlm.nih.gov/pubmed/19823070.

783. Anker CJ, Grossmann KF, Atkins MB, et al. Avoiding severe toxicity from combined BRAF inhibitor and radiation treatment: consensus guidelines from the Eastern Cooperative Oncology Group (ECOG). Int J Radiat Oncol Biol Phys 2016;95:632–646. Available at: https://www.ncbi.nlm.nih.gov/pubmed/27131079.

784. Ho J, Mattei J, Tetzlaff M, et al. Neoadjuvant checkpoint inhibitor immunotherapy for resectable mucosal melanoma. Front Oncol 2022;12:1001150. Available at: https://www.ncbi.nlm.nih.gov/pubmed/36324592.

785. Patel SP, Othus M, Chen Y, et al. Neoadjuvant-adjuvant or adjuvant-only pembrolizumab in advanced melanoma. N Engl J Med 2023;388:813–823. Available at: https://www.ncbi.nlm.nih.gov/pubmed/36856617.

Discussion update in progress

Version 1.2026 © 2025 National Comprehensive Cancer Network© (NCCN©), All rights reserved. NCCN Guidelines® and this illustration may not be reproduced in any form without the express written permission of NCCN.